

Osteopetrosis; a report of two Iranian patients with autosomal recessive inheritance pattern

Saeid Morovvati^{1*}, Sara Amirpour Amraii², Hosna Zahed Shekar Abi², Nastaran Shahbazi²,
Reza Ranjbar³

1. Research Center for Human Genetics, Baqiyatallah University of Medical Sciences, Tehran, Iran.

2. Tehran Medical Unit, Islamic Azad University, Tehran, Iran.

3. Molecular Biology Research Center, Baqiyatallah University of Medical Sciences, Tehran, Iran.

In the rare hereditary bone disorder of osteopetrosis, reduced bone resorption function leads to both the development of densely sclerotic fragile bones and progressive obliteration of the marrow spaces and cranial foramina. Marrow obliteration, typically associated with extramedullary hemopoiesis and hepatosplenomegaly, results in anemia and thrombocytopenia; and nerve entrapment accounts for progressive blindness and hearing loss. Severe infantile or malignant osteopetrosis is the worst type of the disease which has poor prognosis. In this study we report two cases of severe infantile or malignant type of the disease in an Iranian family.

Our two patients were children of a family where the wife is a grandchild of the husband's aunt. The first patient had episodes of seizure and spastic in extremities 2 weeks after birth. Gradually, the patient showed upper and lower respiratory problems and horizontal nystagmus. X-Ray of hand and foot showed widening and increased bone density and physical examination showed hepatosplenomegally and petechiae in extremities. The patient expired due to cardiopulmonary arrest. The second patient had also episodes of seizure 2 weeks after birth. Gradually, dissymmetry in eyes appeared and blindness was confirmed by ophthalmologist. Finally the patient expired because of severe pneumonia.

Autosomal recessive osteopetrosis has been reported in most ethnic groups although it is more frequently seen in ethnic groups where consanguinity is common. We report for the first time two cases of severe infantile or malignant type of the disease in an Iranian family.

Key words: Osteopetrosis, autosomal recessive, consanguinity

Osteopetrosis, a rare hereditary bone disorder is also named marble bone disease because of the dense rock-like appearance of the bone in the disease (1). Several genes have been associated with osteopetrosis in humans (2). It is thought that bone formation is normal and that bone resorption

is reduced, resulting in the presence of excessive calcified tissue. The abnormal resorption results in the normal structural pattern of the bone being grossly altered, the cortices are thickened, individual bony trabeculae are increased, and the marrow spaces are encroached upon leading to a

*Corresponding author: Research Center for Human Genetics, Baqiyatallah University of Medical Sciences, Mollasadra St, Tehran, Iran.
Email: morovvati@bmsu.ac.ir, morovvati@hotmail.com

paucity of haemopoietic tissue with consequent secondary anemia (3). Four types of osteopetrosis have been described: Severe infantile or malignant type, osteopetrosis with renal tubular acidosis and cerebral calcifications, benign type and intermediate type (2). Severe infantile or malignant type is the worst one and has poor prognosis. In this study we report two cases of severe infantile or malignant type of the disease in an Iranian family.

Case presentation

We are reporting two patients which are offsprings of an Iranian family where the wife is a grandchild of the husband's aunt (Fig.1).

Patient one

He was born with normal vaginal delivery. Weight at birth was 3000 grs. Two weeks after birth, the infant had episodes of seizure like eye staring, focal movement in face and spastic in extremities. Infant underwent work-up and hypocalcaemia was detected ($Ca=3.5$). Gradually, the patient showed upper and lower respiratory problems and when he was 2 years old he had tonsillectomy due to tonsillar hypertrophy. At this time, patient didn't gain catch-up weight and his weight was approximately 9.2 Kg when he was 2.5 years old. The patient had horizontal nystagmus, but CT scan and serial head circumference didn't reveal abnormality. X-Ray of hand and foot showed widening and increased bone density, and loss of the normal corticomedullary differentiation. Then, patient showed productive rough, high fever and

confusion and was hospitalized showing hepatosplenomegally upon examination and petechiae in extremities (Platelet: 61000). Patient was admitted in ICU and intubated, but finally cardiopulmonary arrest occurred and he expired.

Patient two

The second patient was born with normal vaginal delivery. Her height, weight and head circumference was 46cm, 3700grs and 35cm respectively. She had normal apgar score and infantile reflexes were normal. At the fifth day after birth she became icteric. Some blood indexes of the patient were Hct:43, WBC:9100, Plts:145000. In the course of hospitalization, she had two episode of seizure. In clinical testes hypocalcaemia ($Ca=5$) was detected. Gradually, the mother of the patient discovered dissymmetry in eyes of patient, and the patient got hospitalized. The ophthalmologist confirmed blindness, but the two retinas were normal. In the course of disease she had not good weight (weight at 4 years old was 1Kg) and she was edentulous. Then, an ulcerative lesion was found in right mandible of the patient that gradually increased in size and the patient became supportive. Patient became febrile and hospitalized with diagnosis of chronic osteomyelitis. In the course of hospitalization the patient presented cough, respiratory distress and the level of consciousness decreased, so she was intubated but finally expired because of severe pneumonia.

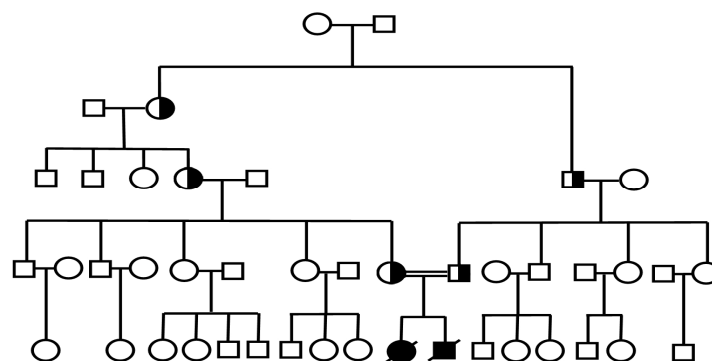


Fig 1 .Pedigree of patients

Discussion

The growth and remodeling of bone that occurs during vertebrate development requires the carefully balanced activities of bone-forming osteoblast cells and bone-resorbing osteoclast cells. Disruption of this dynamic equilibrium can lead to a variety of pathological states. A century ago, Albers-Schönberg described the radiographic findings of osteopetrosis (4) including a generalized increased bone density together with modelling defects at the metaphyseal ends of long bones, resulting in typically widened and blunted diaphyses and metaphyses (5). Autosomal recessive malignant osteopetrosis (ARO) is a rare congenital disorder of bone resorption. It is caused by the failure of osteoclasts to resorb immature bone. Defective resorption leads to both the development of densely sclerotic fragile bones (osteosclerosis) and progressive obliteration of the marrow spaces and cranial foramina. Marrow obliteration, typically associated with extramedullary hemopoiesis and hepatosplenomegaly, results in anemia and thrombocytopenia; and nerve entrapment accounts for progressive blindness and hearing loss. Other major manifestations are failure to thrive, pathological fractures, and increased infection rate (6).

The generation of superoxide by peripheral blood leucocytes is defective in patients with osteopetrosis. This, along with the anemia, poor nutrition, recurrent hospital admissions, and the frequent ear, nose, and throat complications, results in a greatly increased susceptibility to infections especially pneumonia and septicemia, which are a common cause of death (7). Infantile malignant osteopetrosis becomes apparent during the first months of life. The natural course of ARO is characterized by early mortality: only 30% of children are still alive at the age of 6 years, the mortality rate being higher in the first 2 years of life. Without treatment, life expectancy rarely exceeds twenty years. The main causes of death are

severe bone marrow failure and overwhelming infections (8-9).

The incidence of ARO is approximately 1 in 300,000 births but is almost 10 times as high in Costa Rica (10). Osteopetrosis has been reported in most ethnic groups although as the disease is very rare it is more frequently seen in ethnic groups where consanguinity is common and consanguineous sibships with multiple affected patients have been described in Costa Rica [9], Kuwait (11) and Saudi Arabia (12).

Osteopetrosis is a genetically heterogeneous disease. Several human genes have been described as the cause of ARO. The T-cell immune-regulator-1 (TCIRG1) gene (MIM 604592), which is mutated in about 50 to 60 percent of the patients, results in defects in the A3 subunit of the osteoclast vacuolar H⁺-ATPase proton pump (13-14). This gene has been mapped to 11q13 (15). The chloride channel 7 (CLCN7) gene (MIM 602727) which accounts for about 10 to 15 percent of cases, encodes an osteoclast-specific chloride channel. Heterozygous CLCN7 mutations cause a wide range of phenotypes even in the same family, ranging from early severe to nearly asymptomatic forms (16). Recessive osteopetrosis with renal tubular acidosis (MIM 259730) which accounts for a small proportion of patients with osteopetrosis, results from a mutation in the gene encoding carbonic anhydrase type II (CAII) and a defect in production of carbonic acid and proton (17).

Several patients have been reported with the grey-lethal gene (OSTM1) mutation, coding for a cytoplasmic protein involved in OCL functional activity, but this mutation also occurs in few children with osteopetrosis (18). Mouse GL protein function is absolutely required for osteoclast and melanocyte maturation and function. Perturbation of this balance can lead to a reduction of bone mass, as seen in osteoporosis, or to an abnormal accumulation of bone, as in osteopetrosis. It should be noted that a substantial percentage of patients

with osteopetrosis have no identifiable gene defect. The analysis of the OSTM1 gene in two patients, both from Kuwait, showed homozygosity for two nucleotide deletion in exon 2, leading to a frameshift and premature termination. The third (Lebanese) patient showed a single point mutation in exon 1, leading to a nonsense mutation (19).

Gene analysis in two Portuguese families affected with osteopetrosis showed homozygosity for CLCN7 mutations. Direct sequencing of the CLCN7 gene in both patients revealed homozygosity for two mutations G203D and P470Q (20). All nine Costa Rican patients had either one or both of the two missense mutations G405R and R444L (21).

Acknowledgment

We thank Research Center for Human Genetics and Molecular Biology Research Center from Baqiyatallah University of medical sciences for financial support of this research. There is no conflict of interest in this article.

References

1. Worth HM. Principles and practice of oral radiologic interpretation. Chicago: Year Book Medical Publishers; 1963:128–31.
2. Van Hul E, Gram J, Bollerslev J, et al. Localization of the gene causing autosomal dominant osteopetrosis type I to chromosome 11q12-13. *Journal of Bone and Mineral Research* 2002;17:1111-7.
3. Van Hul W, Vanhoenacker F, Balemans W, et al. Molecular and radiological diagnosis of sclerosing bone dysplasias. *European Journal of Radiology* 2001;40:198-207.
4. Albers-Schönberg HE. Röntgenbilder einer seltenen Knochenerkrankung. *Munch Med Wochenschr* 1904;51:365-8.
5. Shapiro F. Osteopetrosis .Current clinical considerations. *Clin Orthop Relat Res* 1993;294:34-44.
6. Gerritsen EJ, Vossen JM, van Loo IH, et al. Autosomal recessive osteopetrosis: variability of findings at diagnosis and during the natural course. *Pediatrics* 1994;93:247-53.
7. Reeves JD, August CS, Humbert JR, et al. Host defense in infantile osteopetrosis. *Pediatrics* 1979;64:202-6.

8. Gerritsen EJ, Vossen JM, Fasth A, et al. Bone marrow transplantation for autosomal recessive osteopetrosis. A report from the Working Party on Inborn Errors of the European Bone Marrow Transplantation Group. *J Pediatr* 1994;125:896-902.
9. Loria-Cortes R, Quesada-Calvo E, Cordero-Chaverri C. Osteopetrosis in children: a report of 26 cases. *J Pediatr* 1977;91:43-7.
10. Fasth A, Porras O. Human malignant osteopetrosis: pathophysiology, management and the role of bone marrow transplantation. *Pediatr Transplant* 1999;3 Suppl 1:102-7.
11. Abdel-Al YK, Shabani IS, Lubani MM, et al. Autosomal recessive osteopetrosis in Arab children. *Ann Trop Paediatr* 1994;14:59-64.
12. al-Rasheed SA, al-Mohrij O, al-Jurayyan N, et al. Osteopetrosis in children. *Int J Clin Pract* 1998;52:15-8.
13. Frattini A, Orchard PJ, Sobacchi C, et al. Defects in TCIRG1 subunit of the vacuolar proton pump are responsible for a subset of human autosomal recessive osteopetrosis. *Nat Genet* 2000;25:343-6.
14. Kornak U, Schulz A, Friedrich W, et al. Mutations in the a3 subunit of the vacuolar H(+)-ATPase cause infantile malignant osteopetrosis. *Hum Mol Genet* 2000;9:2059-63.
15. Heinemann T, Bulwin GC, Randall J, et al. Genomic organization of the gene coding for TIRC7, a novel membrane protein essential for T cell activation. *Genomics* 1999;57:398-406.
16. Kornak U, Kasper D, Bosl MR, et al. Loss of the CIC-7 chloride channel leads to osteopetrosis in mice and man. *Cell* 2001;104:205-15.
17. Sly WS, Hewett-Emmett D, Whyte MP, et al. Carbonic anhydrase II deficiency identified as the primary defect in the autosomal recessive syndrome of osteopetrosis with renal tubular acidosis and cerebral calcification. *Proc Natl Acad Sci USA* 1983;80:2752-6.
18. Chalhoub N, Benachenhou N, Rajapurohitam V, et al. Grey-lethal mutation induces severe malignant autosomal recessive osteopetrosis in mouse and human. *Nature Medicine* 2003;9:399-406.
19. Pangrazio A, Poliani PL, Megarbane A, et al. Mutations in OSTM1 (grey lethal) define a particularly severe form of autosomal recessive osteopetrosis with neural involvement.

Journal of Bone and Mineral Research 2006;21:1098-105.

20. Campos-Xavier AB, Saraiva JM, Ribeiro LM ,et al. Chloride channel 7 (CLCN7) gene mutations in intermediate autosomal recessive osteopetrosis. Human Genetics 2003;112:186-9.

21. Sobacchi C, Frattini A, Orchard P, et al. The mutational spectrum of human malignant autosomal recessive osteopetrosis . Human Molecular Genetics 2001;10:1767-73.