Babol University Of Medical Sciences

IJMCM, Winter 2026, VOL 15, NO 1

International Journal of Molecular and Cellular Medicine

Journal homepage: www.ijmcmed.org

ORIGINAL ARTICLE

Histological and Molecular Characterization of Mucin-Rich Gastrointestinal and Mammary Carcinomas with a Focus on MUC1, MUC2, MUC4 and MUC5AC

Mahmoud Mohammed Mahmoud[1*], Mohanad Mundher Abdulghani[2], Dler Omar Mohammed[3]

1. Department of Pathology, College of Medicine, University of Kirkuk, Kirkuk, Iraq.
2. Department of Pathology and Forensic Medicine, Al Kindy College of Medicine, University of Baghdad.
3. Department of General Surgery, College of Medicine, University of Kirkuk, Kirkuk, Iraq.

ARTICLE INFO

Received: 2025/12/17
Revised: 2026/02/11
Accepted: 2026/03/10

ABSTRACT

Although mucin-producing carcinomas of the gastrointestinal tract and breast have similar histological characteristics, their clinical behavior and prognosis vary. The relationship of mucin gene product expression in the development of these clinical differences is poorly understood. This study examines the histopathological characteristics of gastrointestinal and breast mucin-producing carcinomas for the expression of MUC1, MUC2, MUC4, and MUC5AC and their relationship to patient outcome. A retrospective comparative study of 120 mucinous carcinomas of the gastrointestinal tract and breast (60 in each group) was conducted. The histopathological characteristics of the tumors were examined. MUC gene expression was quantified by RT-qPCR in a subset of 60 cases. Overall survival was evaluated in the RT-qPCR subset using Kaplan–Meier analysis and multivariate Cox proportional hazards models. Gastrointestinal tumors exhibited significantly higher histologic grade and greater necrosis compared with mammary tumors ($P < 0.01$). MUC2 and MUC5AC were markedly overexpressed in gastrointestinal carcinomas ($P < 0.001$ for both), whereas MUC1 and MUC4 were expressed across both tumor types. In multivariate analysis, high expression of MUC1 (hazard ratio = 2.18; 95% confidence interval [CI], 1.31–3.61; $P = 0.003$) and MUC4 (HR = 1.89; 95% CI, 1.10–3.23; $P = 0.017$) was independently associated with reduced overall survival. In contrast, MUC2 and MUC5AC expression distinguished tumor origin but showed no prognostic significance ($P > 0.05$). Mucin gene expression profiles differ substantially between GI and mammary mucin-rich carcinomas. MUC1 and MUC4 have prognostic relevance, while MUC2 and MUC5AC aid in determining tumor origin. Integrating histopathological evaluation with molecular profiling may improve diagnostic accuracy and risk stratification in mucin-rich carcinomas.

Keywords: Mucinous carcinoma; Gastrointestinal tumours; Breast tumours; Gene expression; Prognostic biomarkers; Histopathology

***Corresponding**:
Mahmoud Mohammed Mahmoud
Address:
[1]Department of Pathology, College of Medicine, University of Kirkuk, Kirkuk, Iraq.
E-mail:
mahmoud_mm1973@uokirkuk.edu.iq

Cite this article: Mahmoud M, et al. Histological and Molecular Characterization of Mucin-Rich Gastrointestinal and Mamm Carcinomas with a Focus on MUC1, MUC2, MUC4 and MUC5AC. International Journal of Molecular and Cellular Medic 2026; 15 (1):1216-1227-. DOI: 10.22088/IJMCM.BUMS.15.1.1216

[Downloaded from ijmcmed.org on 2026-11-27]

[DOI: 10.22088/IJMCM.BUMS.15.1.1216]

© The Author(s).
Publisher: Babol University of Medical Sciences
This work is published as an open access article distributed under the terms of the Creative Commons Attribution 4.0 License (http://creativecommons.org/licenses/by-nc/4). Non-commercial uses of the work are permitted, provided the original work is properly cited.

Introduction

Mucin-producing carcinomas form a unique group of epithelial neoplasms that are differentiated by the high levels of extracellular mucin production. Mucinous adenocarcinomas most commonly occur in the colon, rectum, and stomach. These tumors form 10-15% of colorectal cancers and up to 20% of gastric cancer cases in specific ethnic groups (1). Geographical variations also occur, with a higher incidence reported from East Asia and Eastern Europe. Mucinous carcinoma of the breast constitutes 1-7% of all invasive breast cancer cases. These cases usually occur in postmenopausal women (2-5). Despite the similarities between the tumor types based on mucin production, GI tract mucinous adenocarcinomas and those occurring in the breast vary significantly with respect to tumor behavior, clinical course, and treatment outcomes (2).

Despite the advancements made in the histopathological evaluation of tumors through the application of modern diagnostic techniques, mucinous carcinomas continue to pose a challenge due to the high levels of heterogeneity between the tumor types. GI tract mucinous adenocarcinomas commonly occur at an advanced stage with peritoneal dissemination, while the clinical course of pure mucinous carcinoma of the breast tends to be indolent (6,7). Geographic and ethnic variations also occur with respect to the occurrence of these tumors, indicating the role of environmental, hormonal, and genetic factors (8,9).

Histopathological evaluation of the tumor also proves to be a challenge due to the varying levels of mucin production within the tumor tissues, the occurrence of mixed tumor types, and the ambiguous nature of the tumor due to the presence of signet-ring cells and floating clusters (10-13). Despite the application of immunohistochemical techniques to enhance the accuracy of the evaluation, the results prove to be inconsistent due to the ambiguous nature of the tumor with respect to mucin production or the tumor type (14).

Mucins, encoded by the mucin (MUC) family genes, are high molecular weight glycoproteins that play critical roles in the protection of the epithelial barrier, cell signaling, and immune modulation. Aberrant expression of mucins, along with altered patterns of mucin glycosylation, has been implicated in the development of cancer, facilitating the survival, invasiveness, metastasis, and immune escape of tumor cells (15). On the other hand, MUC5AC, a gel-forming mucin, is normally present in the gastric mucosa but is aberrantly overexpressed in various mucinous carcinomas, which may contribute to the mucinous differentiation of tumor cells, facilitating immune escape (17, 18, 19). Thus, the different roles of different mucins may lead to differential effects on the tumor phenotype, depending upon the type of mucin.

Mucin overexpression has been known to affect the tumor phenotype as well as the prognosis. MUC2 and MUC5AC overexpression has been correlated with the invasiveness and peritoneal dissemination of GI cancers. On the other hand, pure mucinous breast cancers with high MUC1 and MUC2 expression are known to be low-grade, ER-positive, whereas the mixed type with MUC1, MUC2, and HER2 overexpression is known for its aggressive behavior and resistance to therapy (19, 20). Despite the increasing interest in the biological roles of mucins, there is a lack of comparative analyses of the histopathological features, along with the molecular profiles, of mucin-rich cancers of different organs. This is the major reason for the lack of reliable diagnostic tools.

In the present study, the histopathological features, along with the expression profiles of the MUC genes, of mucin-rich gastrointestinal cancers and breast cancers, along with the assessment of the prognostic significance, are the aims. The mucin panel was selected a priori to reflect both shared epithelial tumor biology and tissue-specific differentiation. Transmembrane mucins MUC1 and MUC4 were included because of their broad expression across epithelial cancers and established associations with tumor aggressiveness and prognosis.

In contrast, the gel-forming mucins MUC2 and MUC5AC were selected as markers of gastrointestinal differentiation, given their predominant expression in intestinal and gastric epithelium and mucinous tumors.

Other mucins, such as MUC6 and MUC16, were not included because of their more restricted or context-dependent expression patterns and limited relevance to distinguishing gastrointestinal from mammary mucin-rich carcinomas within the scope of this study.

[Downloaded from ijmcmed.org on 2026-11-27]

[DOI: 10.22088/IJMCM.BUMS.15.1.1216]

Methods

Study Design and Setting

This retrospective, multicenter, comparative study evaluated histopathological features in all cases and included survival follow-up in a molecularly characterized subset. The study extended from August 2017 to August 2025 and involved four Iraqi medical institutions: Azadi Teaching Hospital (Kirkuk), the Oncology Centre (Kirkuk), Al-Kindy Teaching Hospital (Baghdad), and Al-Amal Oncology Hospital (Baghdad). FFPE tissue blocks and associated clinical data were collected from pathology archives. Ethical approval was granted by the University of Kirkuk, College of Medicine.

Informed consent was not required because this is a retrospective study, and patient identifiers were removed to ensure confidentiality. Ethical principles were in accordance with the Declaration of Helsinki. Ethical approval was granted by the Ethics Committee of the University of Kirkuk, College of Medicine. As this is a retrospective study using archived FFPE tissues and removing patient identifiers to ensure confidentiality, the ethics committee waived the need to obtain informed consent. All patient identifiers were removed to ensure data confidentiality and protection.

Sample Collection

In total, 120 carcinoma samples rich in mucin were evaluated. In the gastrointestinal tumor group, 60 tumors were used, including colorectal adenocarcinoma (30 cases), gastric adenocarcinoma (20 cases), and pancreatic ductal adenocarcinoma (10 cases). In the mammary tumor group, 60 tumors were used, including invasive ductal carcinoma with mucinous features (35 cases), pure mucinous carcinoma (15 cases), and invasive lobular carcinoma with mucin pools (10 cases).

Inclusion Criteria

1-Histologically confirmed mucin-rich carcinoma (>50% extracellular mucin). 2-Complete clinicopathological data available. 3-Adequate FFPE tissue for histology and molecular analysis.

Exclusion Criteria

1-Tumors with ambiguous mucinous components or mixed phenotypes. 2-Insufficient residual FFPE material for RNA extraction. 3-Receipt of neoadjuvant therapy before biopsy.

Selection of Samples for Molecular Analysis

Sixty cases were selected for the analysis via reverse transcription quantitative polymerase chain reaction (RT-qPCR). As the study used archival formalin-fixed paraffin-embedded (FFPE) tissues that were collected over a long period of time from various centers, a stratified approach to sample selection was adopted. The criteria for sample selection were as follows:

1. Preservation quality blocks with optimal fixation status and minimal autolysis;

2. Tumor cellularity, which was defined as a minimum tumor content of 50% within the sample;

3. Tissue adequacy to allow simultaneous histopathological examination and nucleic acid extraction.

This approach ensured that the sample selected for the RT-qPCR analysis represented all the histological subtypes while providing high-quality nucleic acids.

Histopathological Examination

Tumor necrosis was evaluated on hematoxylin and eosin (H&E)-stained sections and graded semi-quantitatively using a four-grade scoring system based on the estimated percentage of tumor necrosis: 0, no necrosis present; 1, focal tumor necrosis composing <10% of tumor area; 2, moderate tumor necrosis composing 10% to 30% of tumor area; and 3, extensive tumor necrosis composing >30% of tumor area. Representative 4-µm sections were evaluated independently by two senior pathologists without knowledge of clinical or molecular information. Tumors with >50% extracellular mucin volume were considered mucin-rich according to established diagnostic criteria. Tumor grade, 8th edition American Joint Committee on Cancer Tumor-node-metastasis stage, lymphovascular invasion (21), tumor necrosis score, and other parameters were evaluated using standardized systems.

Interobserver agreement was excellent with a κ value of 0.84. In cases with discordant results between the two reviewers, cases were co-reviewed and a consensus reached. Semi-quantitative estimation of the proportion of extracellular mucin was performed by visual estimation of the mucinous tumor volume as compared with the total tumor volume on H&E-stained tumor sections. Ancillary staining with periodic acid-Schiff-Alcian blue or mucicarmine was

[Downloaded from ijmcmed.org on 2026-11-27]

[DOI: 10.22088/IJMCM.BUMS.15.1.1216]

used when necessary to assess mucin content in equivocal cases. For the purpose of descriptive and comparative analyses, tumors were also stratified into those with >70% extracellular mucin volume as a means of identifying tumors with mucin predominance; however, this did not involve redefining the existing diagnostic categories.

RNA Extraction and Gene Expression Analysis

Total RNA was extracted from the FFPE blocks using the Qiagen RNeasy FFPE Kit. The quantity and quality of the extracted RNA were determined using the NanoDrop Spectrophotometer and the Agilent Bioanalyzer, respectively. However, only the samples with a DV200 ≥30% were included. Complementary DNA (cDNA) synthesis was done using the High-Capacity cDNA Reverse Transcription Kit from Applied Biosystems.

Quantitative real-time polymerase chain reaction (qPCR) was performed using the QuantStudio™ 5 Real-Time PCR System from Applied Biosystems. A TaqMan™ Universal PCR Master Mix was used, along with the TaqMan Gene Expression Assays for mucin 1 (MUC1), mucin 2 (MUC2), mucin 4 (MUC4), and mucin 5AC (MUC5AC), which are Hs00159357_m1, Hs00159374_m1, Hs00366414_m1, and Hs01365616_m1, respectively. Glyceraldehyde-3-phosphate dehydrogenase (GAPDH) (Hs02758991_g1) was the endogenous reference gene. The reactions were performed for 20 µl, containing 20 ng of cDNA, using the standard conditions: 95 °C for 10 min, followed by 40 cycles of 95 °C for 15 s, and then 60 °C for 1 min. Three replicates for each sample, along with the required no-template control and no-reverse transcription control, were performed. The relative expression of the genes was done using the 2^(-ΔΔCt) method, ensuring that the efficiencies were maintained at the required level of 90-110%. Inter-batch calibrators were included for the balanced processing of the samples

Statistical Analysis

All statistical analyses were carried out using SPSS 28.0 software. Continuous variables were expressed as mean with standard deviation or median with interquartile range, while categorical variables were expressed as frequency with percentage. Comparisons between groups were performed using the χ^2 test or Fisher's exact test for categorical variables and Student's t-test or Mann-Whitney U test for continuous variables, as appropriate. A P value < 0.05 was considered statistically significant.

For gene expression analyses, an absolute log2 fold change ≥1.0 was used as an a priori threshold to determine biologically significant differences between groups with multiple testing correction using the Benjamini-Hochberg false discovery rate method. High versus low gene expression for survival analyses was defined as the upper tertile of ΔCt values.

Colon, gastric, and pancreatic mucin-rich carcinomas were grouped as a single cohort to investigate the primary research objective.

OS was calculated as time from diagnosis to death from any cause or last follow-up. Kaplan-Meier survival estimates with log rank tests were used to analyze survival distributions between groups. Multivariate Cox proportional hazards regression analysis was used to assess the independent prognostic value of mucin gene expression on survival outcomes while controlling for tumor stage, histologic grade, and lymph node status. Hazard ratios with 95% confidence intervals were reported. Proportional Hazards assumption was verified.

All analyses were performed on the subset with reverse transcription-quantitative polymerase chain reaction data with complete case analysis used to manage missing data.

Results

Clinicopathological Characteristics

A total of 120 patients with mucin-rich carcinomas were included in the study. These included 60 patients with GI tract carcinomas and 60 patients with mammary carcinomas. The average patient age in the study group was 58.6 ± 10.4 years. There was a female predominance in the study group (65%), mainly due to the contribution of breast cancer.

Most of the GI tract carcinomas included in the study originated from the colon/rectum (n = 30), followed by the stomach (n = 20) and the pancreas (n = 10). The histological type of breast carcinomas included invasive ductal carcinomas with mucinous components (n = 35), pure mucinous carcinomas (n = 15), and invasive lobular carcinomas with mucin production (n = 10). GI tract carcinomas were found to have a higher percentage of advanced-stage

[Downloaded from ijmcmed.org on 2026-11-27]

[DOI: 10.22088/IJMCM.BUMS.15.1.1216]

diseases (Stage III/IV in 66.7%) compared to breast carcinomas. Moreover, the GI tract carcinomas showed a higher percentage of lymph node metastases (70%) compared to breast carcinomas ($p < 0.01$). The average tumor size in the GI group was larger compared to the breast group (5.4 ± 1.8 cm vs. 3.1 ± 1.2 cm; $p < 0.001$). High-grade histology in GI carcinomas (60%) was significantly higher compared to breast carcinomas (30%) ($p = 0.002$).

These findings indicated that GI tract mucinous carcinomas were more aggressive, larger in size, and had a higher stage of progression compared to breast carcinomas (Table 1).

Table 1. Demographic and Clinical Characteristics of Patients*

Characteristic	GI Tumors (n=60) Mean ± SD	Breast Tumors (n=60) Mean ± SD	p-value
Mean Age (years ± SD)	60.1 ± 9.8	57.2 ± 10.9	0.138
Female (%)	31 (51.7%)	47 (78.3%)	<0.001*
Mean Tumor Size (cm)	5.4 ± 1.8	3.1 ± 1.2	<0.001*
High-Grade Histology (%)	36 (60%)	18 (30%)	0.002*
Stage III/IV (%)	40 (66.7%)	22 (36.7%)	0.001*
Lymph Node Positive (%)	42 (70%)	20 (33.3%)	<0.001*

*Continuous variables are presented as mean ± SD and compared using Student's t-test when normally distributed or the Mann–Whitney U test otherwise. Categorical variables are presented as n (%) and compared using the χ^2 test or Fisher's exact test, as appropriate. Two-sided $p < 0.05$ was considered statistically significant.

Histopathological Findings

In terms of histological appearance, the gastrointestinal and mammary tumors showed large pools of extracellular mucin, although the tumor architecture and tumor-stroma interface were quite different between the two types of tumors. In the gastrointestinal tumors, mucin was present in large confluent lakes with floating clusters and individual malignant cells in a desmoplastic stroma with an irregular infiltrative pattern (Figure 1A). In contrast, mammary mucinous carcinomas typically displayed well-demarcated, lobulated mucin pools containing cohesive nests of low-grade tumor cells, often separated by delicate fibrous septa and showing more circumscribed margins (Figure 1B).

Quantitative comparison of histological features is summarized in Table 2. A mucin volume >70% was slightly more frequent in GI tumors than in breast tumors (66.7% vs 55.0%, $p = 0.179$), although this difference did not reach statistical significance. Infiltrative margins were significantly more common in GI carcinomas (76.7% vs 33.3%, $p < 0.001$). Moderate-to-extensive necrosis (necrosis score ≥ 2) was present in 50.0% of GI tumors compared with 20.0% of mammary tumors ($p = 0.001$). In addition, the occurrence of desmoplasia was also higher in GI tumors compared with the other tumors (63.3% vs 30.0%, $p < 0.001$). Signet-ring cells were also found to be present in 28.3% of GI tumors compared with 3.3% of the breast tumors ($p < 0.001$). Among the GI tumors, high necrosis scores were significantly correlated with lymphovascular invasion ($p = 0.01$) (Table 2).

MUC Gene Expression Profiles

RT-qPCR data analysis showed specific profiles of mucin genes differentiating gastrointestinal and mammary mucinous carcinomas. In conclusion, MUC2 and MUC5AC were significantly overexpressed in gastrointestinal carcinomas, while MUC1 and MUC4 showed moderate differences in expression levels. As shown in Table 3, MUC2 expression in gastrointestinal carcinomas showed a mean log2 fold change +2.6 compared to breast carcinomas (FDR < 0.001), reflecting its exclusive presence in gastrointestinal tract goblet cells. MUC5AC, a gastric-type mucin, also showed a similar pattern of expression in gastrointestinal carcinomas, with a mean log2 fold change +2.3 (FDR < 0.001). MUC1 expression in gastrointestinal and mammary carcinomas was similar, although slightly increased in gastrointestinal carcinomas (log2 fold change +1.2; FDR = 0.034). MUC4 showed a mean $\log_2$ fold change of +1.0 in GI tumors versus breast

[Downloaded from ijmcmed.org on 2026-11-27]

[DOI: 10.22088/IJMCM.BUMS.15.1.1216]

tumors (FDR = 0.045). These differences are illustrated in the RT-qPCR expression plots (Figure 2), in which paired dot and heatmap representations highlight the robust discriminatory capacity of MUC2 and MUC5AC for GI mucinous tumors, while MUC1 and MUC4 remain more broadly expressed across both organ sites.

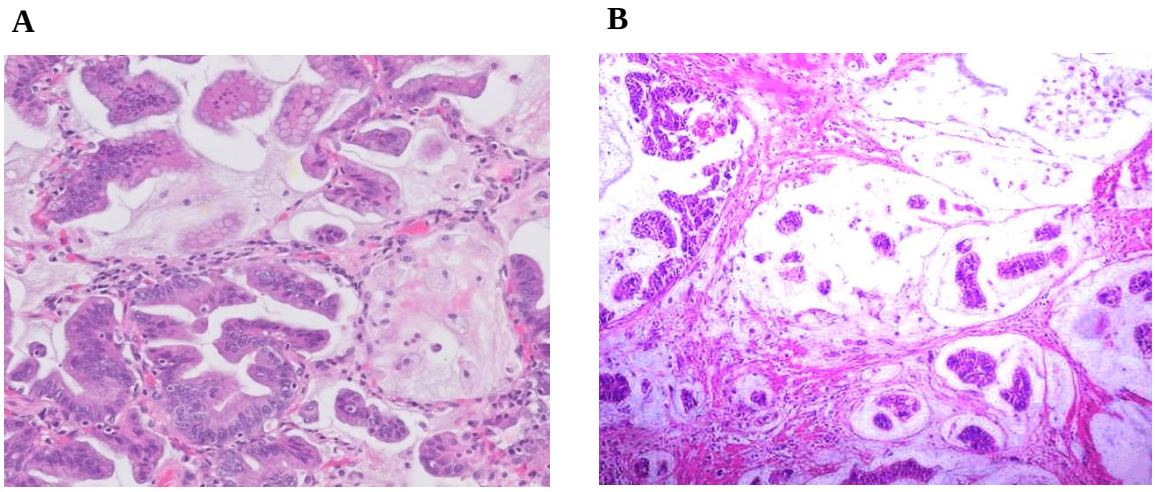

Figure 1. Histomorphological features of mucin-rich carcinomas in GI and mammary tissues. (A) Colonic mucinous adenocarcinoma Hematoxylin and eosin (H&E, 400×) showing prominent extracellular mucin pools containing irregular clusters and small groups of malignant epithelial cells, with gland-forming elements at the periphery of mucin lakes. Tumor cells display nuclear enlargement and hyperchromasia with variable pleomorphism. The surrounding stroma appears fibrocollagenous in areas adjacent to mucin pools. (B) Mammary mucinous carcinoma (H&E, 100×) showing large mucin pools containing cohesive nests and clusters of tumor cells, with fibrous stromal septa separating mucinous areas. Compared with panel A, the mucin pools appear more rounded and compartmentalized, and tumor cell clusters are more cohesive within mucin.

Table 2. Histopathological Comparison Between Tumor Groups

Feature	GI Tumors (n=60)	Breast Tumors (n=60)	p-value
Mucin Volume >70% (%)	40 (66.7%)	33 (55.0%)	0.179
Infiltrative Margins (%)	46 (76.7%)	20 (33.3%)	<0.001
Necrosis Score ≥ 2 (%)	30 (50.0%)	12 (20.0%)	0.001
Desmoplasia Present (%)	38 (63.3%)	18 (30.0%)	<0.001
Signet-Ring Cells Present (%)	17 (28.3%)	2 (3.3%)	<0.001

Chi-square test* p-value < 0.05 indicates statistical significance*.

Table 3. MUC Gene Expression: GI vs. Mammary Tumors*

Gene	Mean Log□ Fold Change (GI vs. Breast; breast as reference)	Adjusted p-value (FDR)
MUC1	+1.2	0.034*
MUC2	+2.6	<0.001*
MUC4	+1.0	0.045*
MUC5AC	+2.3	<0.001*

*Student t-test p-value < 0.05 indicates statistical significance. Numbers at risk are not shown for clarity. Tick marks indicate censored observations

[Downloaded from ijmcmed.org on 2026-11-27]

[DOI: 10.22088/IJMCM.BUMS.15.1.1216]

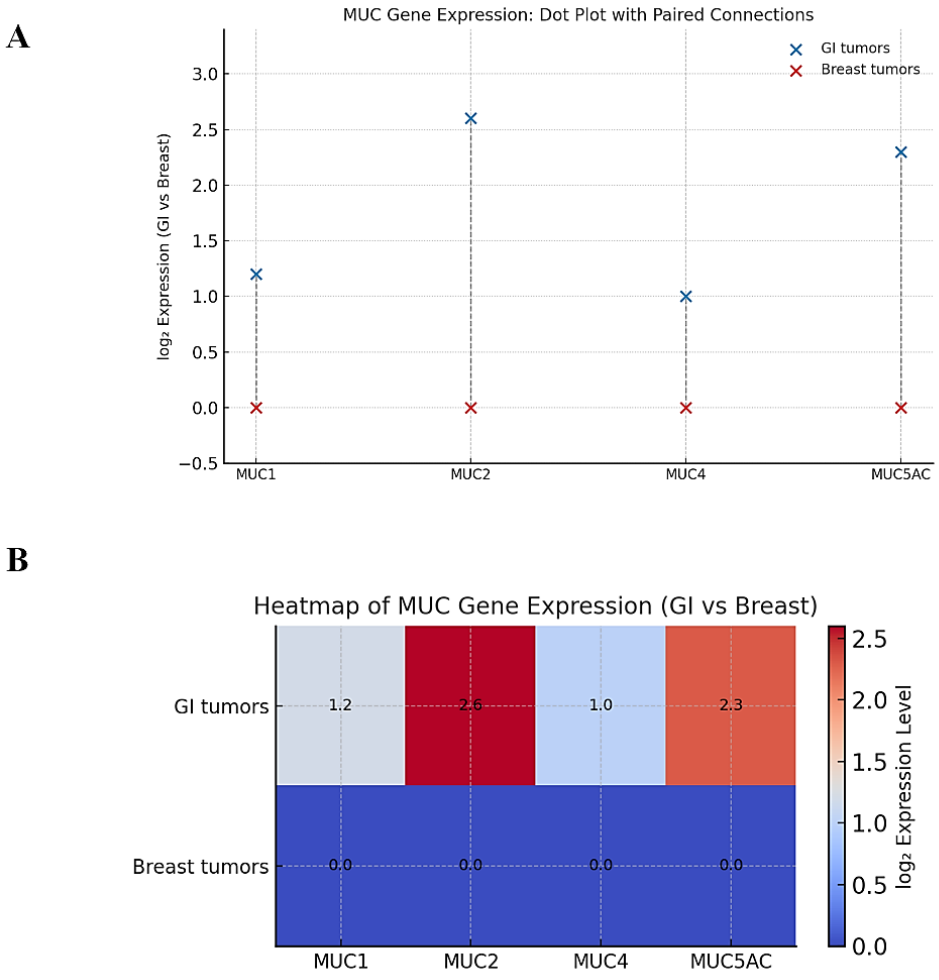

Figure 2. RT-qPCR-based comparison of MUC gene expression between GI and breast mucin-rich carcinomas. (A) Dot plot showing mean log2 fold change values of gastrointestinal (GI) tumor samples compared to breast tumor samples for MUC1, MUC2, MUC4, and MUC5AC based on the information provided in Table 3. Blue dots represent the log2 fold change values of GI tumor samples compared to breast tumor samples, while red dots represent the reference level of the fold change values of breast tumor samples set to 0 on the log2 fold change scale. Dashed vertical lines connect the reference baseline to the GI fold change values of each gene of interest. Among the four genes analyzed, MUC2 and MUC5AC had the highest log2 fold change values compared to MUC1 and MUC4. (B) Heat map showing the mean log2 fold change values of MUC genes in gastrointestinal mucin-rich carcinomas compared to mammary mucin-rich carcinomas based on the information provided in the Andot plot above. In this figure, mammary tumor samples were used as reference samples and were set to 0. This figure shows that mammary tumor samples are not devoid of MUC genes but rather represent the baseline or reference level of MUC gene expression. Warmer colors indicate higher $\log_2$ fold-change values in gastrointestinal tumors relative to mammary tumors. Values represent group-level estimates derived from reverse transcription–quantitative polymerase chain reaction analyses and do not correspond to individual tumor samples.

Correlation with Prognosis

Survival analyses were conducted in the RT-qPCR subset (n = 60). Kaplan–Meier curves showed that patients with high MUC1 or high MUC4 expression, defined by the upper tertile of ΔCt-normalized expression, had significantly shorter overall survival compared with those with low expression (Figure 3). Follow-up duration did not differ significantly between GI and mammary tumor groups.In multivariate Cox proportional hazards

[Downloaded from ijmcmed.org on 2026-11-27]

[DOI: 10.22088/IJMCM.BUMS.15.1.1216]

regression, adjusting for tumor stage, grade, and lymph node status, High MUC1 expression (upper ΔCt-based tertile) remained an independent predictor of mortality (HR = 2.18, 95% CI 1.31–3.61, p = 0.003). High MUC4 expression was also independently associated with worse outcome (HR = 1.89, 95% CI 1.10–3.23, p = 0.017). Advanced stage (III/IV) and lymph node positivity were strong adverse prognostic factors (HR = 2.56 and 1.76, respectively; both p < 0.05). In contrast, high expression of MUC2 or MUC5AC did not significantly influence overall survival (p = 0.490 and p = 0.727, respectively). These findings are summarized in the forest plot and detailed in Table 4.

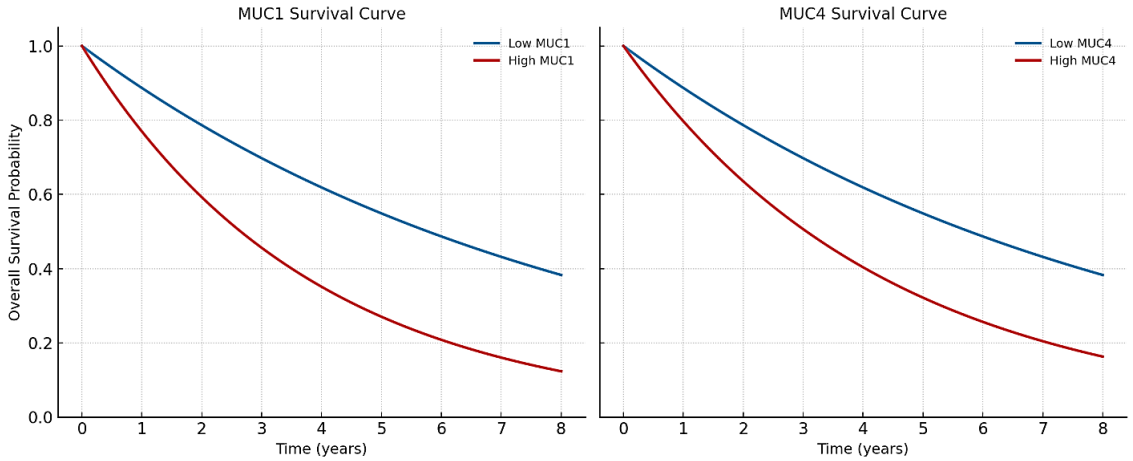

Figure 3. Kaplan–Meier overall survival curves stratified by MUC1 and MUC4 gene expression in the RT-qPCR subset. Kaplan–Meier estimates of overall survival are shown for patients in the RT-qPCR subset (n = 60), stratified by high versus low expression of MUC1 (left panel) and MUC4 (right panel). Expression groups were defined using the upper tertile of ΔCt-normalized RT-qPCR values, with lower ΔCt indicating higher gene expression. Blue curves represent patients with low expression, and red curves represent those with high expression of the respective gene. In both analyses, higher expression of MUC1 and MUC4 is associated with reduced overall survival compared with lower expression levels. Statistical significance and effect sizes were assessed using log-rank tests and confirmed in multivariate Cox proportional hazards regression models adjusting for tumor stage, histologic grade, and lymph node status (see Table 4). The curves are shown over an 8-year follow-up period.

Table 4. Multivariate Cox proportional hazards regression for overall survival in the RT-qPCR subset (n = 60).*

Variable	Hazard Ratio (HR)	95% CI	p-value
High MUC1 Expression	2.18	1.31–3.61	0.003*
High MUC4 Expression	1.89	1.10–3.23	0.017*
Tumor Stage III/IV	2.56	1.49–4.42	<0.001*
Lymph Node Positive	1.76	1.01–3.09	0.046*
High MUC2 Expression	1.21	0.70–2.07	0.490
High MUC5AC	0.91	0.53–1.57	0.727

Multivariate Cox Regression Analysis* p-value < 0.05 indicates significance*

Discussion

The integrated analysis of histopathology, along with mucin gene expression profiles, has provided a comprehensive overview of the spectrum of mucin-rich tumors of the gastrointestinal and mammary systems. Morphologically, the gastrointestinal tumors demonstrated highly irregular tumor borders, high scores of necrosis, and a high percentage of high-grade tumors. These features are indicative of more

[Downloaded from ijmcmed.org on 2026-11-27]

[DOI: 10.22088/IJMCM.BUMS.15.1.1216]

aggressive tumor behavior. Moreover, the tumors were of higher clinical stages, with more lymphovascular invasion and lymph node metastasis in the gastrointestinal tumors.

At the molecular level, differential mucin expression is indicative of tissue-specific differentiation patterns as well as tumor aggressiveness. In the gastrointestinal tumors, the overexpression of MUC5AC, a gel matrix mucin normally present only in gastric epithelium, has been implicated in mucinous differentiation and altered tumor-host interaction, including reduced immune access (references 18, 19). In the present study, the differential expression of MUC5AC distinguished gastrointestinal from mammary mucin-rich tumors but was not correlated with patient survival. Thus, it appears that MUC5AC overexpression is of primary diagnostic use.

Mucin 4, a transmembrane mucin, has been implicated in the modulation of tumor behavior by interaction with the human epidermal growth factor receptor 2 (HER2) signaling pathways, thereby enhancing tumor proliferation and invasiveness (references 17, 22). Consistent with these observations, high MUC4 expressions were independently correlated with reduced overall survival. Thus, MUC4 is implicated more as a marker of tumor aggressiveness rather than being indicative of the tissue type of origin.

The association of high MUC1/MUC4 expression with reduced overall survival is consistent with experimental evidence of the roles of these mucins in the epithelial mesenchymal transition, migration, modulation of growth factor signals, and cell-cell adhesion (references 15, 17, 22).. Although the present study was not designed to explore mechanisms, our findings are compatible with these proposed functions and support further investigation of MUC1 and MUC4 as markers of adverse tumor biology.

Our results are broadly consistent with previous reports on mucinous GI tumors. Several studies in colorectal and gastric adenocarcinomas have described frequent overexpression of MUC2 and MUC5AC in mucinous histotypes and have linked these patterns to specific clinicopathological features and chemoresistance (23,24). Lee et al. reported that MUC2 overexpression in colorectal cancer was associated with mucinous histology and reduced response to fluoropyrimidine-based chemotherapy (23). Similarly, Namikawa and Hanazaki described MUC5AC expression in diffuse-type gastric carcinoma and its association with unfavorable outcomes possible chemoresistance (24). Our comparative analysis between GI and mammary tumors extends these observations by showing that MUC2 and MUC5AC are strongly enriched in GI mucin-rich carcinomas but not in most breast mucinous tumors.

In contrast, the biological landscape of mucin-rich mammary carcinomas is different. MUC1 is the most consistently expressed mucin in the breast, particularly in pure mucinous and mixed mucinous carcinomas, which are often low grade and have relatively favorable prognosis (19). Rakha et al. reported that MUC1 is overexpressed in mucinous and mixed-type breast carcinomas, although its prognostic impact depends on the broader molecular context (19). MUC4 has also been associated with adverse outcome, especially in more aggressive molecular subtypes such as triple-negative breast cancer (24). In our series, MUC1 and MUC4 expression contributed more to prognostic stratification than to distinguishing organ of origin, which is compatible with their broader distribution across tumor types.

MUC2 expression in breast tumors was generally low in our cohort. Occasional expression may reflect aberrant differentiation or focal intestinal-type mucin production, but in this study, it was not associated with worse prognosis. This supports the concept that mucin genes have tissue-specific roles and that their clinical significance depends on the background epithelial context. In conclusion, our data add to the existing body of literature by providing a comparison of two different, although histologically similar, tumor types, thus emphasizing their common features (the association of MUC1/MUC4 expression with aggressiveness) and their unique features (organ-specific expression of mucin molecules, such as gastrointestinal tract-predominant expression of MUC2/MUC5AC in gastrointestinal and mammary gland tumors, respectively).

From a translational point of view, this study demonstrates that the expression of mucin genes could play a potential role in diagnostic and predictive workups in a limited number of cases. For example, in diagnostically difficult cases of mucin-producing tumors, especially in metastatic tumors of uncertain

[Downloaded from ijmcmed.org on 2026-11-27]

[DOI: 10.22088/IJMCM.BUMS.15.1.1216]

primary site, differences in expression of MUC2 and MUC5AC could help to identify gastrointestinal tract primaries, whereas their lack of expression in most breast mucinous carcinomas could be useful in a limited number of cases when considered in the appropriate clinical and immunohistochemical context.

Finally, the association of high expression of MUC1 and MUC4 with poor survival in gastrointestinal and mammary gland tumors could help in stratifying risk in these two types of cancer. Patients with high expression of these two molecules could be considered a subgroup with a worse prognosis, in whom closer clinical surveillance could be considered. Furthermore, recent studies on MUC1-directed vaccines and antibody drug conjugates in various types of solid tumors also emphasize the potential utility of these molecules as therapeutic targets; however, it should be noted that our data should not be considered directly applicable to therapeutic decisions.

In summary, this study has demonstrated that the combination of histopathological examination with mucin gene expression profiling can provide additional information regarding the behavior of tumors arising in mucinous carcinomas. However, it should be noted that the results of this study should be interpreted with caution and should be verified using larger prospective cohorts before it is considered for clinical use.

Several limitations should be noted. Firstly, the sample size, though adequate for the purpose of this comparative study, may not be large enough to reflect the biological heterogeneity of gastrointestinal and mammary tumors, especially at the subsite level. Secondly, the multicenter nature of the study, though enabling the collection of a large sample size, may limit control over pre-analytical variables such as tissue fixation and storage, which may affect histopathological examination. Thirdly, the survival analyses may have been limited by the availability of follow-up information, which may not reflect the differences in systemic therapy, thereby affecting the association of mucin expression with outcome. Lastly, the expression of genes was analyzed at a single time point, thereby limiting the assessment of the dynamics of expression during the course of the disease.

In addition, molecular subtype data for breast cancer, including estrogen receptor, progesterone receptor, and human epidermal growth factor receptor 2 status, were not consistently available and therefore not included, necessitating analysis of breast tumors as a single cohort. Finally, no formal a priori power calculation was performed for the reverse transcription–quantitative polymerase chain reaction subset, and the prognostic associations observed should be interpreted as hypothesis-generating pending confirmation in larger, well-characterized cohorts.

Gastrointestinal and breast cancers differ substantially in natural history, therapeutic approaches, and baseline survival. Although tumor origin was adjusted for in multivariate models, residual confounding related to disease-specific biology and treatment cannot be excluded. Accordingly, pooled survival analyses should be interpreted as exploratory and hypothesis-generating, and tumor-specific prognostic effects of mucin expression warrant validation in homogeneous, site-specific cohorts.

Future work should aim to validate these findings in larger, prospectively collected multicenter cohorts with standardized treatment and follow-up protocols. Such studies would help in a better evaluation of the independent prognostic value of MUC1 and MUC4 and their application in more sophisticated models of risk stratification. Spatially resolved techniques, including the application of digital pathology techniques and spatial transcriptomics, may help in determining the heterogeneity of mucin expression within tumors, especially in mixed or borderline tumors. At the same time, multi-omics techniques including transcriptomics and genomics may help in determining co-operating pathways with mucin genes that play a part in tumor development or treatment resistance. In vitro and in vivo techniques may be important in determining the specific function of MUC1 and MUC4 in tumor invasion and metastasis and immunomodulation in mucin-producing tumors.

This comparative analysis of mucin-rich carcinomas of the gastrointestinal tract and the breast correlated histopathological parameters with the expression patterns of the MUC genes. Carcinomas of the gastrointestinal tract showed a high grade of malignancy, necrosis, high tumor stage, and lymph node involvement compared to the mammary mucinous carcinomas. On the molecular level, the overexpression of the genes MUC2 and MUC5AC

[Downloaded from ijmcmed.org on 2026-11-27]

[DOI: 10.22088/IJMCM.BUMS.15.1.1216]

was significantly higher in gastrointestinal tumors. However, the genes MUC1 and MUC4 were overexpressed in both gastrointestinal and breast tumors. The overexpression of the genes MUC1 and MUC4 correlated significantly with poor survival rates. On the contrary, the overexpression of the genes MUC2 and MUC5AC was only used to differentiate between the tumors. Overall, this comparative analysis of the two tumors provides a rationale for the investigation of the biological significance of the overexpression of the genes MUC1 and MUC4 in mucin-rich tumors.

Acknowledgments

This study was supported financially by a research grant (A) from the University of Kirkuk, College of Medicine. The study protocol was reviewed and approved by the Ethics Committee of the College of Medicine, Kirkuk University, Ministry of Higher Education and Scientific Research, Iraq (approval code: 50-2-11-2023; date of approval: November 2, 2023).

References

1. Auld FM, Moyana TN. Invasive stratified mucin-producing carcinoma of the colorectum: expanding the morphologic spectrum of large bowel cancer. Diagn Pathol. 2023;18(1):113.
2. Yap YS, Lu YS, Tamura K, Lee JE, et al. Insights into Breast Cancer in the East vs the West: A Review. JAMA Oncol. 2019;5(10):1489–96.
3. Arif K, Hussain I, Rea C, et al. Stem Cell Factor Antibody: Effective Manipulation of Antihormonal Therapy in Resistant Human Breast Cancer In Vitro. J Drug Deliv . 2019; 9(4): 608-612.
4. Abdulla AK, Al-Barzinji RMG, Taher CA. Open reading frame 8 gene sequence variation of coronavirus in patients from Erbil City, Iraq. Gomal J Med Sci. 2024;22(1):44–51.
5. Mohammed Mahmoud M, Abdulla Kamil Abdulla null, Dler Omar Mohammed null. Molecular detection of Epstein-Barr virus in invasive ductal carcinoma of the breast: a case-control study. Cell Mol Biol Noisy--Gd Fr. 2025;71(9):105–10.
6. Yonezawa S, Higashi M, Yamada N, et al. Mucins in human neoplasms: clinical pathology, gene expression and diagnostic application. Pathol Int. 2011;61(12):697–716.
7. Luo C, Cen S, Ding G, et al. Mucinous colorectal adenocarcinoma: clinical pathology and treatment options. Cancer Commun Lond Engl. 2019;39(1):13.
8. Bishop KD, Olszewski AJ. Epidemiology and survival outcomes of ocular and mucosal melanomas: a population-based analysis. Int J Cancer. 2014 ;134(12):2961–71.
9. Cancer burden: Epidemiology, racial, and geographical disparities. In: Biomarkers in Cancer Detection and Monitoring of Therapeutics [Internet]. Academic Press; 2024;1:15–32.
10. Chen C, Patel A, Demirkhanyan L, et al. The Role of Mucins in Cancer and Cancer Progression: A Comprehensive Review. Curr Issues Mol Biol. 2025;47(6):406.
11. Carr NJ, Bibeau F, Bradley RF, et al. The histopathological classification, diagnosis and differential diagnosis of mucinous appendiceal neoplasms, appendiceal adenocarcinomas and pseudomyxoma peritonei. Histopathology. 2017;71(6):847–58.
12. Joneja U, Palazzo J. The Spectrum of Mucinous Lesions of the Breast. Arch Pathol Lab Med. 2023;147(1):19–29.
13. Gautam SK, Khan P, Natarajan G, et al. Mucins as Potential Biomarkers for Early Detection of Cancer. Cancers. 2023;15(6):1640.
14. Belfast Pathology 2017. 10th Joint Meeting of the British Division of the International Academy of Pathology and the Pathological Society of Great Britain & Ireland, 2017. J Pathol. 2017;243 Suppl 1:S1–41.
15. Rose MC, Voynow JA. Respiratory tract mucin genes and mucin glycoproteins in health and disease. Physiol Rev. 2006;86(1):245–78.
16. Gustafsson JK, Johansson MEV. The role of goblet cells and mucus in intestinal homeostasis. Nat Rev Gastroenterol Hepatol. 2022;19(12):785–803.
17. Dreyer CA, VanderVorst K, Free S, et al. The role of membrane mucin MUC4 in breast cancer metastasis. Endocr Relat Cancer. 2021;29(1):R17–32.

[Downloaded from ijmcmed.org on 2026-11-27]

[DOI: 10.22088/IJMCM.BUMS.15.1.1216]

18. Yonezawa S, Horinouchi M, Osako M, et al. Gene expression of gastric type mucin (MUC5AC) in pancreatic tumors: its relationship with the biological behavior of the tumor. Pathol Int. 1999;49(1):45–54.
19. Rakha EA, Boyce RWG, Abd El-Rehim D, et al. Expression of mucins (MUC1, MUC2, MUC3, MUC4, MUC5AC and MUC6) and their prognostic significance in human breast cancer. Mod Pathol Off J U S Can Acad Pathol Inc. 2005;18(10):1295–304.
20. Mall AS. Analysis of mucins: role in laboratory diagnosis. J Clin Pathol. 2008 Sept;61(9):1018–24.
21. Carr NJ, Bibeau F, Bradley RF, et al. The histopathological classification, diagnosis and differential diagnosis of mucinous appendiceal neoplasms, appendiceal adenocarcinomas and pseudomyxoma peritonei. Histopathology. 2017;71(6):847–58.
22. Mercogliano MF, Inurrigarro G, De Martino M, et al. Invasive micropapillary carcinoma of the breast overexpresses MUC4 and is associated with poor outcome to adjuvant trastuzumab in HER2-positive breast cancer. BMC Cancer. 2017;17(1):895.
23. Lee PY, Md Azhan FS, Low TY. Biomarkers for colorectal cancer chemotherapy: Recent updates and future perspective. Malays J Pathol. 2023;45(3):317–31.
24. Namikawa T, Hanazaki K. Mucin phenotype of gastric cancer and clinicopathology of gastric-type differentiated adenocarcinoma. World J Gastroenterol. 2010;16(37):4634–9.

[Downloaded from ijmcmed.org on 2026-11-27]

[DOI: 10.22088/IJMCM.BUMS.15.1.1216]