



Babol University  
Of Medical Sciences

IJMCM, Summer 2025, VOL 14, NO 3

International Journal of Molecular and Cellular Medicine

Journal homepage: [www.ijmcm.org](http://www.ijmcm.org)



## REVIEW ARTICLE

# Recent knowledge on squamous cell carcinoma of the oral cavity: Contributing factors, underlying molecular pathways, and current attitudes in the therapeutic approaches

Reza Mahmoudi Anzabi<sup>1</sup> , Amir Hossein Davodpour<sup>2</sup> , Soroush Ghodratizadeh<sup>3</sup> , Dorsa Nikeghbal<sup>4</sup> , Azita Sadeghzade<sup>5</sup> , Meysam Mohammadikhah<sup>6</sup> , Sajjad Rostamzadeh<sup>7\*</sup>

1. Department of Orthodontics, Faculty of Dentistry, Tabriz University of Medical Sciences, Tabriz, Iran.

2. Department of Oral and Maxillofacial Surgery, Faculty of Dentistry, Isfahan University of Medical Sciences, Isfahan, Iran.

3. Istanbul Aydin University, Faculty of Dentistry, Istanbul, Turkey.

4. Department of Oral & Maxillofacial Surgery, School of Dentistry, Shiraz University of Medical Sciences, Shiraz, Iran.

5. Oral and Dental Disease Research Center, Department of Oral and Maxillofacial Medicine, School of Dentistry, Shiraz University of Medical Sciences, Shiraz, Iran.

6. Department of Oral and Maxillofacial Surgery, School of Dentistry, Alborz University of Medical Sciences, Karaj, Alborz, Iran.

7. Department of Orthodontics, Faculty of Dentistry, Tabriz University of Medical Sciences, Tabriz, Iran.

## ARTICLE INFO

**Received:** 2024/10/16

**Revised:** 2024/11/18

**Accepted:** 2024/11/19

**DOI:**

## ABSTRACT

Oral cavity squamous cell carcinoma (OCSCC) is a prevalent malignancy associated with considerable morbidity and mortality. This article offers a comprehensive overview of its major risk factors, molecular characteristics, and emerging therapeutic approaches. Key risk factors include tobacco use, alcohol consumption, and environmental exposures such as air pollution. Viral infections, particularly with Epstein-Barr Virus (EBV) and high-risk genotypes of Human Papillomaviruses (HPV), are also implicated in OCSCC pathogenesis. At the molecular level, OCSCC is characterized by aberrant expression of growth factors, especially transforming growth factor  $\alpha$  (TGF- $\alpha$ ) and epidermal growth factor receptor (EGFR). EGFR overexpression, often due to gene amplification, is closely associated with tumor progression and poor clinical outcomes. These insights into molecular pathways are guiding the development of targeted therapies. Innovative treatments are being explored, including combination therapies such as metformin with 4SC-202, which show promise in reducing tumor cell migration and enhancing chemotherapy sensitivity. Additionally, nanoengineered formulations of cisplatin aim to improve drug delivery specificity and minimize systemic toxicity, offering a more patient-friendly approach. The article emphasizes the need for continued investigation into novel therapeutic strategies and a deeper understanding of the molecular basis of OCSCC to improve treatment outcomes. Future research priorities include the identification of new risk factors, refinement of induction chemotherapy protocols, and incorporation of personalized treatment strategies. Addressing these areas is crucial for advancing prevention, enabling early diagnosis, and improving survival and quality of life for patients with OCSCC. This work supports ongoing progress in oral cancer research and clinical care.

**Keywords:** Oral cavity cancer, Risk factors, Pathways, Molecular, Therapeutic index

\*Corresponding:

Sajjad Rostamzadeh

**Address:**

Department of Orthodontics,  
Faculty of Dentistry, Tabriz  
University of Medical Sciences,  
Tabriz, Iran

**E-mail:**

sajjadrostamzadeh1@gmail.com



© The Author(s).

Publisher: Babol University of Medical Sciences

This work is published as an open access article distributed under the terms of the Creative Commons Attribution 4.0 License (<http://creativecommons.org/licenses/by-nc/4/>). Non-commercial uses of the work are permitted, provided the original work is properly cited.

## Introduction

Oral cavity cancer (OCC), which is classified as a subset of head and neck cancers (HNC), occupies a noteworthy position within the global landscape of malignancies, ranking sixteenth in terms of prevalence worldwide (1). According to statistics from the year 2020, the global incidence of OCC resulted in the identification of approximately 377,713 new cases, while the mortality figures indicated that around 177,757 individuals succumbed to this form of cancer, specifically linked to cancers of the lips and the oral cavity across various regions of the globe. The occurrence of this particular type of cancer is especially pronounced in Southeast Asian countries, including but not limited to India, Sri Lanka, Pakistan, Bangladesh, and Taiwan, in addition to the Pacific regions, which include territories such as Papua New Guinea and Melanesia, with the high rates being significantly attributed to the widespread cultural practice involving the chewing of betel nut (1-3).

OCC is fundamentally characterized as a malignant neoplasm that originates within the confines of the oral cavity, encompassing a diverse array of subsites such as the buccal mucosa, the floor of the mouth, the anterior portion of the tongue, the alveolar ridges, the retromolar trigone, the hard palate, and the inner surfaces of the lips. It is particularly noteworthy that over 90% of the cases of OCC originate from squamous epithelial tissues, leading to the prevalent terminology of oral cavity squamous cell carcinoma to describe this specific malignancy (4). Several key risk factors have been robustly established as contributors to the development of OCC, including but not limited to the consumption of tobacco in both smoked and smokeless forms, as well as socioeconomic challenges like low income, self-neglect, and a notable lack of awareness regarding oral health issues.

Furthermore, it has been observed that OCC predominantly affects individuals who are over the age of 40, with a statistically significant higher incidence rate observed in males compared to their female counterparts, specifically at ratios of 5.8 cases per 100,000 males versus 2.3 cases per 100,000 females (5). As we approach the year 2024, oral squamous cell carcinomas (SCCs) continue to represent a significant category of malignancy, comprising an estimated 3% of all cancers diagnosed in males and approximately 2% in females across the United States, with a clear

predominance in individuals who are over the age of 50 years. Recent research has highlighted that the most commonly encountered histological variant of SCC is the moderately differentiated type, which is identified in about 43.5% of all cases, while the poorly differentiated variant is present in roughly 17.7% of instances (3).

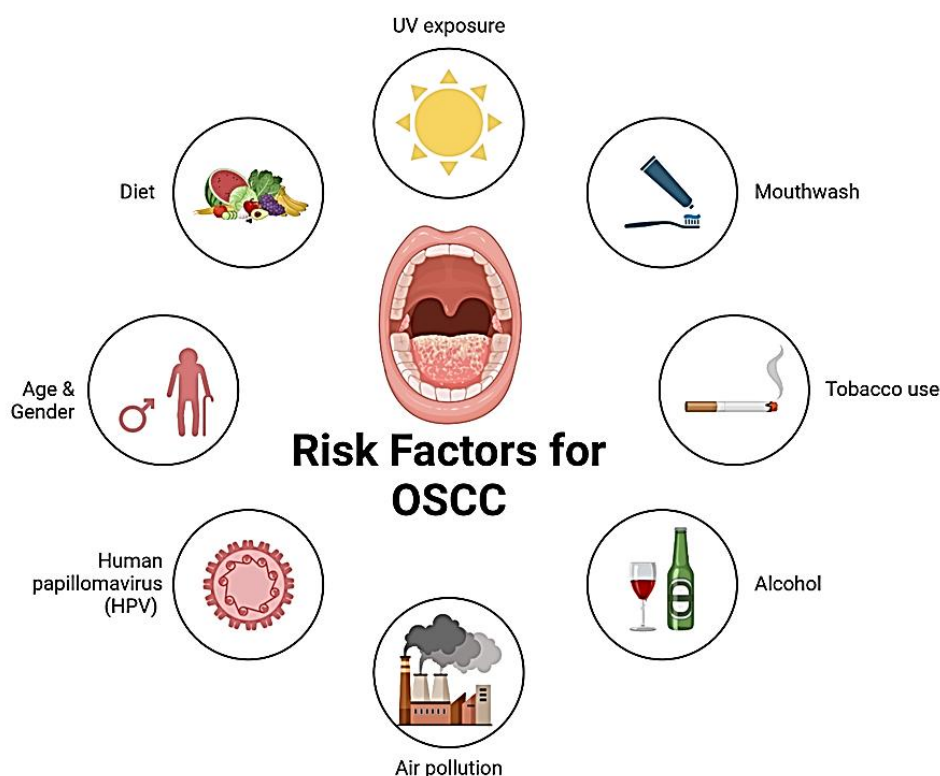
Despite the steady advancements that have been made in the realms of surgical techniques and various treatment modalities aimed at combating this disease, the global survival rates and recurrence statistics about head and neck SCCs have demonstrated only minimal improvements, suggesting the need for further advancements in therapeutic strategies (1). While it is true that the overall incidence rates of head and neck squamous cell carcinoma (HNSCC) have shown a downward trend on a global scale—largely attributable to the reduction in both tobacco and alcohol consumption—there has been a concerning report indicating an increase in the incidence of oral tongue cancers in several countries, which merits further investigation (6, 7).

Moreover, viruses have been proposed as a causal factor because oncoviruses such as High-Risk Human Papillomaviruses (HR-HPV), Merkel Cell Polyomavirus (MCPyV), and Epstein-Barr Virus (EBV) have been detected in oral cavity tumor tissues. The most common premalignant lesions include leukoplakia, proliferative verrucous leukoplakia, erythroplasia, oral lichen planus, and oral submucous fibrosis, each associated with differing risks of malignant transformation. Consequently, a growing proportion of patients diagnosed with HNSCC seem to have no substantial history of tobacco or alcohol use, which raises compelling questions about the potential existence of unidentified risk factors or perhaps new exposures to established risk factors beyond the conventional associations with tobacco and alcohol consumption (7, 8). The different risk factors related to OSCC are summarized in Figure 1 (Figure 1).

Recent investigations have begun to elucidate how the molecular constituents that govern these mechanisms are perturbed in oral cavity squamous cell carcinoma (OCSCC). For instance, the inactivation of p16 and p53 is associated with heightened cellular proliferation and an enhanced capacity to circumvent growth inhibitors. Moreover, the aberrant regulation of the Notch and Wnt-related integration site (WNT) signaling pathways may play a role in promoting

replicative immortality and the evasion of cellular differentiation, whereas the protein kinase B signaling pathway is essential for processes related to invasion and metastasis (6, 7, 9). Despite the availability of novel therapies, such as monoclonal antibodies that target the epidermal growth factor receptor (EGFR) and programmed cell death protein 1 (PD-1), individuals diagnosed with advanced oral malignancies encounter a scarcity of effective treatment alternatives. Consequently, there exists an urgent necessity to explore viable systemic therapies through a comprehensive understanding of the molecular

mechanisms that underlie oral squamous cell carcinoma, particularly the interactions between tumor cells and their adjacent microenvironment (7, 9). Consistent with our research objectives, this review evaluates the existing literature on risk factors, the molecular mechanisms of tumorigenesis within malignant cells, and the therapeutic approaches. It is imperative for clinicians treating oral cancer patients to have a foundational comprehension of these pathways, as they are likely to inform forthcoming therapeutic approaches in addition to understanding the risk factors associated with the incidence of OCC.



**Figure 1: Various risk factors related to oral cavity squamous cell carcinoma.**

### **Risk factors related to oral cavity squamous cell carcinoma**

#### **Oral Potentially Malignant Disorders**

The oral cavity may present a variety of disorders with the potential to become malignant. Among these, premalignant lesions are the most commonly identified, including leukoplakia, proliferative verrucous leukoplakia, erythroplasia, oral lichen planus, and oral submucous fibrosis, each associated with differing risks of malignant transformation. The World Health Organization (2005) classifies precancerous lesions according to the extent of

dysplasia: mild, moderate, severe, and in situ carcinoma (10). Clinically, leukoplakia is characterized as a “white patch or plaque that cannot be identified as another disease either clinically or pathologically.” This condition is frequently associated with the consumption of tobacco and alcohol, with a global prevalence estimated at around 2%. The projected annual rate of malignant transformation for oral leukoplakia is approximately 1%. Factors that augment the likelihood of malignant transformation include the presence of dysplasia, female sex, duration of the lesion, anatomical location on the tongue or floor of the mouth, manifestation in non-smokers,

dimensions exceeding 2 cm, and a non-homogeneous appearance (11, 12).

### **Proliferative verrucous leukoplakia**

Proliferative verrucous leukoplakia is a rare condition of unknown origin, characterized by its progressive, aggressive, multifocal nature, and a high likelihood of evolving into squamous or verrucous carcinoma (13, 14).

### **Erythroplasia**

Erythroplasia is a “red velvety lesion that cannot be classified as resulting from another condition.” Due to the elevated risk of malignancy associated with these lesions, which often accompany dysplasia and in situ carcinoma, surgical resection is advised (15).

### **Oral lichen planus**

Oral lichen planus is a chronic inflammatory condition affecting the skin and mucous membranes, characterized by episodes of flare-ups. Its exact cause remains unclear. It can manifest in several oral forms, with the three most common being reticulated (quiescent), erosive (active), and atrophic (late or post-lichenic). The potential for malignant transformation in oral lichen planus is a concern (16).

### **Fanconi anemia**

Fanconi anemia is a hereditary disorder characterized by bone marrow insufficiency due to mutations in the FANC genes. This condition adheres to an autosomal X-linked recessive mode of inheritance. The FANC genes play a crucial role in synthesizing proteins that facilitate the repair of damaged DNA and uphold genomic stability. Individuals diagnosed with Fanconi anemia exhibit a remarkably heightened risk of developing HNSCC, with estimates indicating a risk that is 500 to 700 times greater than that of the general populace, particularly with the oral cavity being the predominant location for such malignancies (17).

A systematic review found 112 individuals with FA who exhibited an oculopharyngeal muscular dystrophy (OPMD) and/or OSCC. The highest incidence of OSCC was observed in women in their thirties. The lesions typically presented as ulcers or masses, predominantly located on the tongue. Although the estimated rate of transformation from OPMD to OSCC was relatively low at 1.8%, the

likelihood of OSCC recurrence after treatment was significant, accompanied by a low survival rate (18).

### **Dyskeratosis congenita**

Dyskeratosis congenita is a genetic syndrome characterized by impaired telomere maintenance, which can lead to leukoplakia and potentially progress to oral cancer. The squamous cell carcinoma associated with this condition can be inherited in various ways, including X-linked, autosomal dominant, or autosomal recessive patterns, with varying degrees of penetrance (19).

### **Alcohol and tobacco consumption**

The carcinogenic attributes of alcohol are predominantly associated with the endogenous synthesis of acetaldehyde during its metabolic absorption. The International Agency for Research on Cancer (IARC) categorizes acetaldehyde present in alcoholic beverages as a Group 1 carcinogen for humans. Specific demographic groups in East Asia who exhibit genetic variations that influence the enzymes responsible for the metabolism of alcohol (alcohol dehydrogenase: ADH) and acetaldehyde (aldehyde dehydrogenase: ALDH) are prone to accumulating elevated levels of acetaldehyde, leading to a heightened risk of cancer (20). A cohort study involving over 490,000 individuals in the United States demonstrated a relative risk (RR) of 1.52 for OSCC among men consuming more than three alcoholic beverages daily, whereas women within the same consumption range exhibited an RR of 2.81. Additionally, a 2001 meta-analysis revealed a meta-RR of 6.01 for oral cavity and pharyngeal cancers linked to a daily alcohol intake surpassing 100 grams (21, 22).

Moreover, moderate alcohol intake has been associated with an increased risk of mortality, irrespective of other prognostic indicators, among patients receiving treatment for head and neck squamous cell carcinoma. Alcohol use also appears to serve as a significant predictor of disease-specific survival post-treatment for OSCC (22). The correlation between alcohol and tobacco consumption is markedly pronounced across various populations, likely influenced by sociocultural factors and the tendency for co-occurring addictive behaviors. Heavy smokers, characterized by extensive pack years, generally consume more alcohol than light smokers, while individuals who drink heavily are more inclined to smoke compared to their lighter-drinking peers (21).

The simultaneous consumption of both substances produces synergistic effects, resulting in a multiplicative risk rather than merely an additive one. For example, the RR for OSCC is approximately 5.8 for heavy smokers and 7.4 for heavy drinkers, culminating in a combined RR of 37.7 for individuals who both smoke and drink. The concurrent ingestion of tobacco and alcohol amplifies acetaldehyde production, potentially elucidating the observed synergistic interactions (23, 24).

In a meta-analysis study, out of 3,260 records reviewed, 33 articles were selected for qualitative analysis, with 15 of these included in the meta-analyses. The findings indicated a positive correlation between synergistic consumption and the incidence of OSCC, with an OR of 5.37 and a 95% confidence interval ranging from 3.54 to 8.14. Notably, the odds of developing OSCC were heightened with the combined use of alcohol and smoked tobacco, alcohol and smokeless tobacco, as well as the combination of alcohol, smoked tobacco, and smokeless tobacco. The systematic review's results underscore that the synergistic use of alcohol and both forms of tobacco significantly elevates the risk of OSCC (25).

### Human papillomavirus (HPV)

HPV16 has been recognized as a Group 1 carcinogen by the IARC since 1995, primarily due to its involvement in the carcinogenesis of squamous cell carcinoma of the cervix uteri. There has been sufficient evidence establishing a causal link between HPV16 infection and specific cancers of the oral cavity since 1995, while the evidence for HPV18 remains limited. Notably, HPV has emerged as the predominant cause of HNSCC in the United States and northern Europe. However, it accounts for less than 4% of OSCCs (26-28). The carcinogenic mechanisms of HPV include the immortalization of cells, genomic instability, deficiencies in DNA damage repair, and anti-apoptotic properties.

A critical event in this process is the integration of HPV DNA into the host genome, which facilitates the expression of the viral oncogenes E6 and E7. The E6 protein interacts with the p53 protein, inhibiting its ability to bind to DNA and undermining its tumor-suppressing functions. Despite presenting at a more advanced stage at diagnosis, HPV-positive HNSCCs, particularly oropharyngeal squamous cell carcinoma, demonstrate improved survival rates regardless of the treatment approach. Nevertheless, their impact on

OSCC patient's remains limited (29). In a systematic review article, a total of 2,129 articles were identified through the search strategy. Full-text evaluations were conducted for 626 of these articles, resulting in the inclusion of five. The total number of participants was 383, predominantly males, with an average age ranging from 51.0 to 63.5 years. Among the participants, 17 were found to be HPV/mRNA-positive, with subtypes 16 and 18 being the most commonly detected. Notably, nine cases of HPV/mRNA-positive oral squamous cell carcinoma were located on the tongue (30).

A systematic review and meta-analysis indicated that HPV positivity is linked to a significantly reduced overall survival (OS) and disease control (DC), highlighting HPV infection as a negative prognostic factor in OSCC. This analysis incorporated 22 studies involving 3,065 OSCC patients. The findings revealed that HPV-positive OSCC patients experienced a notably shorter OS compared to their HPV-negative counterparts, with a hazard ratio (HR) of 1.45 and a lower DC. However, no significant differences were observed in disease-free survival (DFS), disease-specific survival (DSS), locoregional control (LC), or recurrence (RC) between HPV-positive and HPV-negative OSCC patients (31).

### The other viruses

Epstein-Barr Virus (EBV), HPV, Human T-cell Lymphotropic Virus type-1 (HTLV-1), and Kaposi's Sarcoma-associated Herpesvirus (KSHV) are classified as direct carcinogens; Hepatitis B Virus (HBV), MCPyV, and Hepatitis C Virus (HCV) are recognized as indirect carcinogens that can precipitate a chronic inflammatory response; Human Immunodeficiency Virus type-1 (HIV-1) is categorized as an indirect carcinogen that may lead to immunosuppression (32).

Based on an experimental study, the incidence of infection involving a minimum of two viral agents was observed in 21.1% of the patient cohort. Within this subset, co-infection with HPV and EBV was ascertained in 37.5% of instances, HPV and MCPyV in 29.2%, EBV and MCPyV in 12.5%, and concurrent infection with HPV, EBV, and MCPyV in 20.8%. No statistically significant disparity was found between multiple viral infections and the anatomical sites of malignancy. The occurrence of triple viral infection (HPV/EBV/MCPyV) in well-differentiated neoplasms was greater than that of single infections involving EBV or MCPyV. This investigation elucidated that co-

infection with HPV, EBV, and MCPyV can be detected in both malignant and non-malignant tissues of the oral cavity, and the presence of all three viral agents in well-differentiated tumors may support a synergistic hypothesis concerning the pathogenic mechanisms of these viruses in the process of oral malignant transformation (33).

### Air pollution

The IARC currently deems the evidence insufficient to establish a direct link between air pollution and the incidence of any specific subtypes of HNSCC. Elevated levels of PM<sub>2.5</sub> exposure were correlated with an augmented incidence of oral cavity and pharyngeal malignancies, even after controlling for potential confounding variables in analyses. This ecologically representative national study elucidates that heightened levels of air pollution are correlated with an increase in the overall incidence of oral cavity and pharyngeal cancers within the United States (34, 35). When juxtaposed with PM<sub>2.5</sub> levels below 26.74 µg/m<sup>3</sup>, PM<sub>2.5</sub> levels equal to or exceeding 40.37 µg/m<sup>3</sup> exhibited a markedly significant correlation with a heightened risk of oral carcinoma.

Elevated ozone concentrations were found to be significantly correlated with an augmented risk of oral carcinoma (34). The behaviors of smoking and habitual betel quid consumption demonstrated a significant correlation with an increased risk of oral carcinoma. These findings have substantially enriched the understanding of fine particulate matter pollution as a contributory risk factor for oral carcinoma. Research has elucidated the association between oral carcinoma and PM<sub>2.5</sub>, even at reduced exposure levels (35).

A cross-sectional study was conducted to examine 896 cases of OCC and oropharyngeal cancer (OPC) utilizing data from the Population-based Cancer Registry covering the years 1998 to 2012. The identified occupations were classified into four risk categories based on the framework established by the Ministry of Labor. Additionally, it assessed the impact of smoking and alcohol consumption on these cases. The analysis revealed that the highest incidence rates of oral cancer were linked to occupations in cleaning, construction, administration, agriculture, and transportation. A significant portion of the occupations, specifically 52.2%, fell into the third risk category. This figure rose to 65.5% when smoking and alcohol consumption were factored into the analysis. The sectors of trade,

construction, cleaning services, and mechanics represented the majority of OCC and OPC cases within the studied municipality. In total, were identified 131 occupations associated with oral cancer cases, with the majority classified as risk grade 3. Therefore, it is essential to incorporate occupational risk considerations into the development of preventive strategies (36).

### Endocrine Factors

Given the considerable prevalence of women diagnosed with OSCC who do not present with discernible risk factors, an endocrine hypothesis has been posited. Recent findings from cohort studies have suggested that menopausal hormone therapy may augment the risk of OSCC in postmenopausal women, with an oral estrogen hazard ratio (HR) of 1.633 associated with oral estrogen and similarly an HR of 1.633 attributed to tibolone. Furthermore, a potential correlation between endocrine-disrupting chemicals, such as bisphenol A, has been postulated, albeit this assertion remains unsubstantiated by epidemiological evidence (37, 38).

Sex hormones exert a significant influence on the biopathology of oral cancer and possess prognostic implications across various tumor subgroups. While hormonal receptors have been identified as pivotal in the pathogenesis of breast cancer, prostate cancer, and oropharyngeal tumors, their role in HNSCC remains a subject of considerable debate. The assessment of estrogen receptors (ER), androgen receptors (AR), and progesterone receptors (PR) requires meticulous consideration due to the potential variability in clinicopathological characteristics and their correlation with diverse expression patterns in OSCC (39).

Estrogen is recognized as a carcinogenic agent, with multiple pathways contributing to its tumor-promoting effects. Additionally, estrogen has been demonstrated to induce chromosomal instability, which subsequently results in aneuploidy and facilitates the onset of oral cancer. Ultimately, the expression of ER may be considered an infrequent risk factor for OSCC, whereas PR expression appears to lack relevance in the oncogenesis of OSCC. The integration of gene profiling techniques with molecular methodologies could facilitate the interpretation of extensive studies in the future aimed at diagnosing and mitigating the progression of OSCC (40). Lukits et al. observed a notable prevalence of functional receptor

expression, specifically the co-expression of ER and PR, in head and neck cancers, irrespective of the tumor's anatomical site. The significant number of cases exhibiting both ER and PR suggests that hormones may not affect patient survival but do play a role in the progression of the disease. The expression of sex hormone receptors did not influence the survival rates of patients with head and neck cancer. The expressions of ER $\alpha$ , ER $\beta$ , and progesterone receptor (PgR) are commonly observed in HNC and may have implications for disease prognosis, particularly in the context of LH cancers (41).

### **Plummer–Vinson syndrome**

Plummer–Vinson syndrome, alternatively referred to as Kelly Patterson syndrome, is distinguished by the presence of esophageal webs, iron-deficiency anemia, and atrophy of the gastrointestinal mucosa, and is frequently associated with HNSCC in the retro-cricoid region, particularly affecting the hypopharynx. The prevalence of this syndrome has markedly diminished due to enhancements in dietary iron consumption. The etiopathogenesis of Plummer–Vinson syndrome remains obscure. Nonetheless, factors encompassing iron deficiency, malnutrition, genetic susceptibility, or autoimmune mechanisms may play a role in the emergence of this syndrome.

Myasthenic alterations are evident in the musculature involved in the swallowing process, stemming from the reduction of iron-dependent oxidative enzymes. Atrophy of the esophageal mucosa and the formation of webs are recognized as mucosal complications. These modifications were notably evident in the case presented herein. An autoimmune mechanism is indisputably involved, as this syndrome commonly coexists with conditions such as rheumatoid arthritis, thyroiditis, celiac disease, and pernicious anemia. Additional elements, including nutritional deficiencies and genetic predisposition, are posited to significantly influence the etiology of this disorder (42).

### **Dietary influences**

A variety of research indicates that a diet deficient in fruits, carotenoids, and green vegetables correlates with an elevated risk of HNSCC. An analysis that included 14,520 HNSCC cases and 2,337 controls from 22 case-control studies, identified a protective effect associated with fruit consumption and vegetable intake. Conversely, higher consumption of red meat

and processed meat was linked to an increased risk of HNSCC (43). Additional findings highlighted the protective benefits of vitamin E, vitamin C, carotenoids, and folates. Furthermore, dairy product consumption seems to offer protective effects, as evidenced by a case-control study involving 959 HNSCC patients and 2,877 controls (44). The evidence surrounding tea consumption is mixed, with some studies suggesting a protective effect. However, a recent meta-analysis by Weber Mello et al. has indicated that hot mate consumption may elevate the risk of HNSCC, reporting an OR of 2.24 CI (45).

Additionally, coffee has been associated with protective effects in a 2011 meta-analysis, which reported a meta-risk of 0.64 CI for squamous cell carcinoma of the oral cavity (46). Based on the published study, the intake of dairy products showed a negative correlation with certain upper aerodigestive tract cancers, specifically laryngeal cancer and esophageal cancer. In contrast, the consumption of yellow and orange vegetables was found to be inversely related to the risk of oral/pharyngeal and laryngeal cancers, with odds ratios of 0.53 and 0.62, respectively. Conversely, the intake of preserved vegetables was positively associated with an increased risk of oral/pharyngeal and laryngeal cancers, with a significant trend observed for both (47).

Filomeno et al. analyzed data from a case-control study performed in Italy and Switzerland from 1997 to 2009. The study included 768 patients with newly diagnosed, histologically confirmed cancer and 2078 hospital controls. To assess dietary patterns, three indices were utilized: the Mediterranean Diet Score (MDS), the Mediterranean Dietary Pattern Adherence Index (MDP), and the Mediterranean Adequacy Index (MAI). Their findings revealed a significant inverse relationship between the risk of oral cancer and adherence to the Mediterranean diet, indicating a substantial protective effect of the Mediterranean diet on oral cancer (48).

### **Dental hygiene**

Research has established a connection between oral hygiene habits and the likelihood of developing oral squamous cell carcinoma. Specifically, a reduced risk is linked to having fewer than five missing teeth, annual dental visits, daily tooth brushing, and the absence of periodontal disease. No significant association was observed concerning denture use.

Additional studies have reinforced these conclusions, indicating that inadequate dental hygiene may serve as a risk factor for head and neck squamous cell carcinoma. Moreover, chronic trauma has been suggested as a possible factor contributing to squamous cell carcinoma in the oral cavity, particularly highlighted in a meta-analysis that associated this risk with denture use. Some researchers emphasize that the frequency of trauma is crucial, with the free edge of the tongue being the most common site for OSCC due to its higher susceptibility to injury compared to the tongue's dorsum. Chronic inflammation may also play a role in this context (49, 50).

Interviews concerning dental care and oral health were carried out with 317 cases of head and neck cancer (HNC) and 296 control participants. A significant association was found between HNC and factors such as infrequent dental visits, brushing teeth less than twice a day, frequent gum bleeding, and the loss of more than 20 teeth. An analysis utilizing a dental care score (ranging from 0 to 4, with 4 indicating the worst dental care) that incorporated regular dental visits, tooth brushing, and the use of dental floss and mouthwash revealed a positive correlation with HNC risk, especially among individuals who consume alcohol and smoke cigarettes (51).

Multifactor dimensionality reduction analysis categorized the participants into high- and low-risk groups based on their dental care scores and IL6 rs1800796 genotypes. The high-risk group exhibited an odds ratio for HNC of 2.16 when compared to the low-risk group. This research identified a positive link between inadequate oral hygiene and HNC, with variations noted based on alcohol and cigarette use as well as the IL-6 rs1800796 genotypes. Additional studies are required to clarify whether poor oral hygiene is a direct cause of HNC or merely a surrogate marker for an unhealthy lifestyle that elevates the risk of developing HNC (51).

The potential link between mouthwash use and oral cavity conditions has been raised, as many mouthwash products contain trace amounts of alcohol. Acetaldehyde, a genotoxic byproduct of ethanol, has been found in the saliva of individuals who regularly use mouthwashes. The ARCADE study indicated an odds ratio of 3.23 for those using more than three mouthwashes daily. However, the epidemiological evidence supporting a direct connection between mouthwash use and OSCC remains limited (52).

Observational investigations centered on adult and geriatric populations that examined the association between mouthwash utilization and oral neoplasia were incorporated into a meta-analytic manuscript. Among the 4,094 studies identified, 15 case-control investigations were chosen for inclusion, encompassing a total of 6,515 cases and 17,037 controls. The meta-analysis integrated 17 effect sizes derived from these 15 investigations. The aggregated odds ratio was determined to be 1.00; however, this figure escalated to 2.58 for individuals utilizing mouthwash three or more times per day, and to 1.30 for those who had employed mouthwash for durations exceeding 40 years. The outcomes indicate that habitual mouthwash use may be associated with an increased risk of oral cancer (53).

### Molecular mechanisms

Oncogenes represent modified regulatory genes that promote cellular proliferation and influence signal transduction pathways within the cellular environment. Mutations within these genes can result in either an overproduction or an augmented activity of proteins that stimulate cellular functions. While oncogenes, in isolation, are inadequate to induce the transformation of epithelial cells, they serve as crucial initiators within the transformation continuum, frequently inducing cellular alterations via the mutation of a solitary gene copy (9).

Numerous oncogenes have been associated with the initiation of oral carcinoma. The aberrant expression of the proto-oncogene epidermal growth factor receptor (EGFR/c-erb 1), in conjunction with various members of the ras gene family, c-myc, int-2, hst-1, Cyclin D1, and bcl-1, is posited to contribute to the progression of cancer significantly. The PI3K/AKT/mTOR signaling cascade is instrumental in the metastasis and proliferation of oral squamous cell carcinoma (OSCC) cells. The activation of the PI3K-AKT pathway is commonly observed in OSCC tumors, which is attributable to the elevated phosphorylation states of AKT and its downstream effector mTOR. Consequently, the activation of AKT, PDK1, and mTOR initiates a series of downstream biological responses, including enhancements in cellular metabolism, proliferation, apoptosis, protein synthesis, and transcriptional regulation, thereby facilitating the progression of OSCC. Both HPV-positive and HPV-negative head and neck squamous cell carcinoma



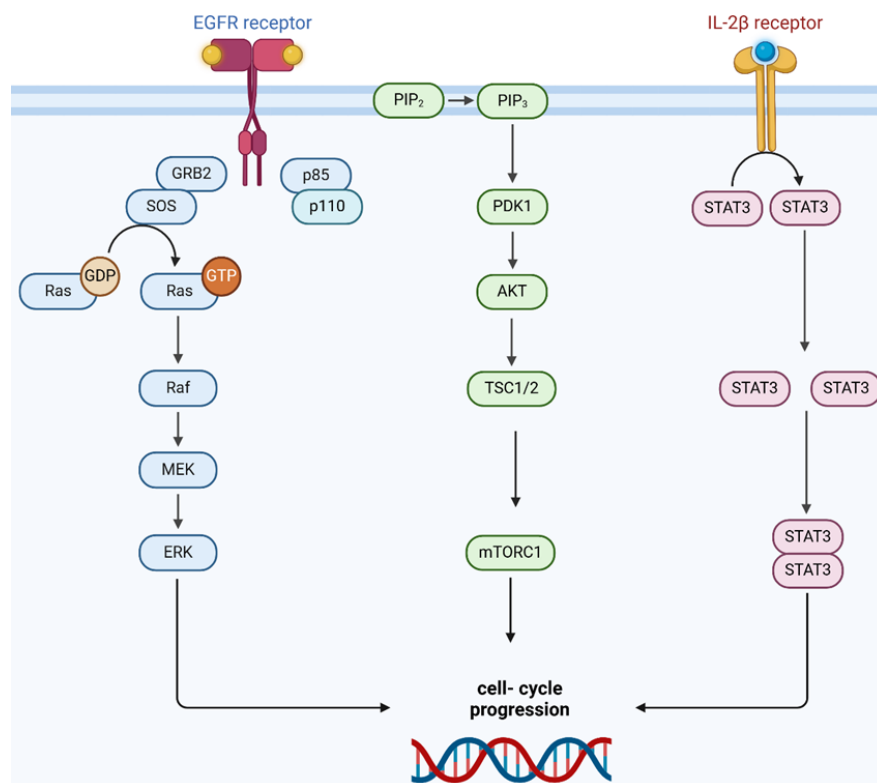
(HNSCC) exhibit aberrant activation of the signal transducer and activator of the transcription (STAT) signaling pathway.<sup>69,115</sup> The elevation of STAT3 expression correlates with the malignancy of HNSCC and is linked to resistance against chemotherapeutic agents, radiotherapy, and therapies targeting the epidermal growth factor receptor (EGFR). The summary of the pathway is mentioned in Figure 2 (54).

In the context of oral carcinogenesis, there is a disruption in the regulation of growth factors, marked by increased production and autocrine stimulation. The abnormal expression of transforming growth factor  $\alpha$  (TGF- $\alpha$ ) is observed early in this process, first in hyperplastic epithelium and later in carcinoma, particularly within the inflammatory cell infiltrate, especially eosinophils, surrounding the affected epithelium. TGF- $\alpha$  promotes cell proliferation by engaging with EGFR in both autocrine and paracrine ways. It is also thought to aid in angiogenesis and has been found in the "normal" oral mucosa of patients who

subsequently develop a second primary carcinoma (55). EGFR, which serves as the receptor for EGF and TGF- $\alpha$ , is frequently overexpressed in oral cancers. Research suggests that this overexpression is associated with EGFR gene amplification in about 30% of cases.

It is believed that the increased expression of the EGF receptor is generally linked to the production of its ligands, TGF- $\alpha$  and EGF. When these ligands bind to the receptor, they initiate a cascade of intracellular processes that enable the transfer of extracellular signals through the cell membrane, activating intrinsic tyrosine kinase activity. Genetic mutations affecting growth factor receptors can result in either an elevated number of receptors or the creation of a continuous ligand-independent mitogenic signal (56). The amplification of the EGFR gene and the heightened presence of EGF receptors in oral cancers are associated with the tumors' differentiation and aggressiveness.

### PI3K/Akt, RAS/MAPK, JAK/STAT Signaling in OSCC



**Figure 2. PI3K/Akt, RAS/MAPK, JAK/STAT signaling pathways in OSCC which targeted therapy for this signaling pathway is important for the drug development.**

EGFR, which serves as the receptor for EGF and TGF- $\alpha$ , is frequently overexpressed in oral cancers. Research suggests that this overexpression is associated with EGFR gene amplification in about 30% of cases. It is believed that the increased expression of the EGF receptor is generally linked to the production of its ligands, TGF- $\alpha$  and EGF. When these ligands bind to the receptor, they initiate a cascade of intracellular processes that enable the transfer of extracellular signals through the cell membrane, activating intrinsic tyrosine kinase activity. Genetic mutations affecting growth factor receptors can result in either an elevated number of receptors or the creation of a continuous ligand-independent mitogenic signal (56). The amplification of the EGFR gene and the heightened presence of EGF receptors in oral cancers are associated with the tumors' differentiation and aggressiveness.

Oral squamous cell carcinomas that exhibit EGFR overexpression have shown a more pronounced response to chemotherapy compared to those lacking EGFR expression. This improved response is likely attributed to the increased proliferative activity in tumors with EGFR overexpression, leading to heightened sensitivity to cytotoxic treatments. Recent studies suggest that therapeutic approaches employing antibodies that target EGF receptors may prove advantageous in managing both premalignant and malignant lesions (55-57). In the development of oral cancer, intracellular signaling molecules can become activated on their own, eliminating the necessity for ligand-receptor interactions. Research has focused on the ras gene family, which plays a significant role in these signaling pathways related to oral cancers. The genes H-ras, K-ras, and N-ras produce the p21 protein, located on the cytoplasmic membrane, which conveys mitogenic signals through guanosine triphosphate (GTP) binding. Normally, the mitogenic signal is deactivated by the conversion of GTP to GDP; however, mutations in the ras oncogene can prevent this process, leading to prolonged stimulation (54).

Studies indicate that the ras oncogene family is frequently overexpressed in oral cancers. The dysregulation of N-ras may signify an early stage in the carcinogenic process of oral cancers, with increased expression observed in initial dysplastic lesions. However, ras mutations are relatively uncommon in the advancement of oral cancers within Western populations, occurring in less than 5% of cases. Conversely, H-ras

mutations are present in 55% of lip cancers and 35% of oral cancers in Asian populations, particularly associated with the consumption of betel nuts (58, 59).

Transcription factors that activate a range of genes are also associated with oral cancer. The functional roles of many of these proteins are influenced by receptor-mediated second messenger pathways. The inactivation of these genes may result in a disruption of the cell cycle, impeding both mitogenic and differentiation responses to growth factors. Notably, the c-myc gene, which is crucial for regulating cell proliferation, is often overexpressed in oral cancers due to gene amplification.

This overexpression is typically linked to poorly differentiated tumors; however, recent research has shown that c-myc is also overexpressed in moderately and well-differentiated oral carcinomas, where the rate of cell proliferation significantly surpasses that of apoptotic cells. c-Myc has a complex role in facilitating both cell proliferation and apoptosis (60). It necessitates p53 for the induction of apoptosis, while the retinoblastoma tumor suppressor gene Rb-1's nuclear protein pR6 interacts with the c-myc gene to suppress its transcription, thereby limiting cell proliferation. However, when pR6 is phosphorylated, c-Myc levels rise, promoting continued cell proliferation. Notably, our research demonstrates that pR6, c-myc, and p53 are present in all oral carcinomas, irrespective of their differentiation status (61).

The phosphorylation of pR6 results in an elevation of c-Myc, which promotes cell proliferation. Importantly, our research demonstrates that pR6, c-Myc, and p53 are present in all oral carcinomas, irrespective of their differentiation levels. Nevertheless, further investigation is required to evaluate the genetic characteristics of these oncogenes and tumor suppressor genes, as well as to measure protein concentrations, to uncover potential regulatory pathways that may contribute to the advancement of oral cancers (9).

The PRAD-1 gene, situated on chromosome 11q13, encodes cyclin D, which, together with the Rb gene product, governs the transition from the G1 phase to the S phase of the cell cycle. This gene is amplified in 30–50% of head and neck cancers, and its amplification is associated with cytological grade, patterns of infiltrative growth, and the occurrence of metastases (62). The hst-1/int-2 gene is responsible for producing a protein that resembles the fibroblast growth factor and plays a role in tumor proliferation

and angiogenesis in oral cancers. This gene is situated on human chromosome 11q13.3 and is co-amplified with int-2 in specific cancer types (63). In 1995, Lese et al. documented the co-amplification of the int-2 and hst-1 genes in cases of oral squamous carcinoma. Further research has indicated that this co-amplification in head and neck squamous carcinomas is associated with tumor recurrence and the advancement of the disease. Additionally, int-2 amplification has been detected in premalignant lesions near neoplastic areas, such as dysplasia and hyperplasia, suggesting that int-2 amplification may precede the onset of tumors (64).

The immunosuppressive characteristics of the tumor microenvironment (TME) in OSCC reveal a complex interplay of various immunomodulatory cells that contribute to tumor progression and evasion of the host immune response. Within this intricate ecosystem, one can identify a diverse array of cell types, such as cancer-associated fibroblasts (CAFs), regulatory T cells (Tregs), tumor-associated macrophages (TAMs), and myeloid-derived suppressor cells (MDSCs), each playing pivotal roles in modulating the immune landscape. The dynamic interaction that occurs between programmed death 1 (PD-1) expressed on T cells and its ligand, programmed death ligand-1 (PD-L1) present on OSCC cells, serves to effectively suppress T-cell activity and foster a state of adaptive immunity tolerance, thus facilitating tumor survival. Furthermore, the cytotoxic T-lymphocyte-associated antigen 4 (CTLA-4) operates through a competitive mechanism whereby it binds to CD80/86 on OSCC cells, thereby inhibiting the stimulatory signals that are normally delivered by CD28, which is crucial for T-cell activation (63).

In addition to PD-1/PD-L1 and CTLA-4, other immune checkpoints such as lymphocyte-activation gene 3 (LAG-3) and T-cell immunoglobulin mucin-3 (TIM-3) also contribute significantly to the immune evasion strategies employed by OSCC. The malignant cells of OSCC have been shown to secrete a variety of immune suppressive factors, including vascular endothelial growth factor (VEGF), granulocyte-macrophage colony-stimulating factor (GM-CSF), transforming growth factor (TGF)- $\beta$ , interleukin (IL)-6, and IL-10, which collectively act to inhibit the functionality of effector immune cells that could potentially mount an effective anti-tumor response. Tregs, in particular, play a central role in this

immunosuppressive milieu by producing TGF- $\beta$  and IL-10, thereby further attenuating the activity of T cells and promoting an environment conducive to tumor growth. Moreover, CAFs are characterized by the expression of  $\alpha$ -smooth muscle actin ( $\alpha$ -SMA) and fibroblast activation protein (FAP), and they contribute to tumor progression by overexpressing microRNA-385-5p in their exosomes, which can influence the behavior of neighboring cells in the TME. Notably, within the TME of OSCC, there exists a marked predominance of M2 macrophages relative to M1 macrophages, with M2 TAMs exhibiting distinct carcinogenic properties that facilitate tumor development and metastasis (Figure 3).

## Therapeutic approaches

### Induction Chemotherapy Regimen

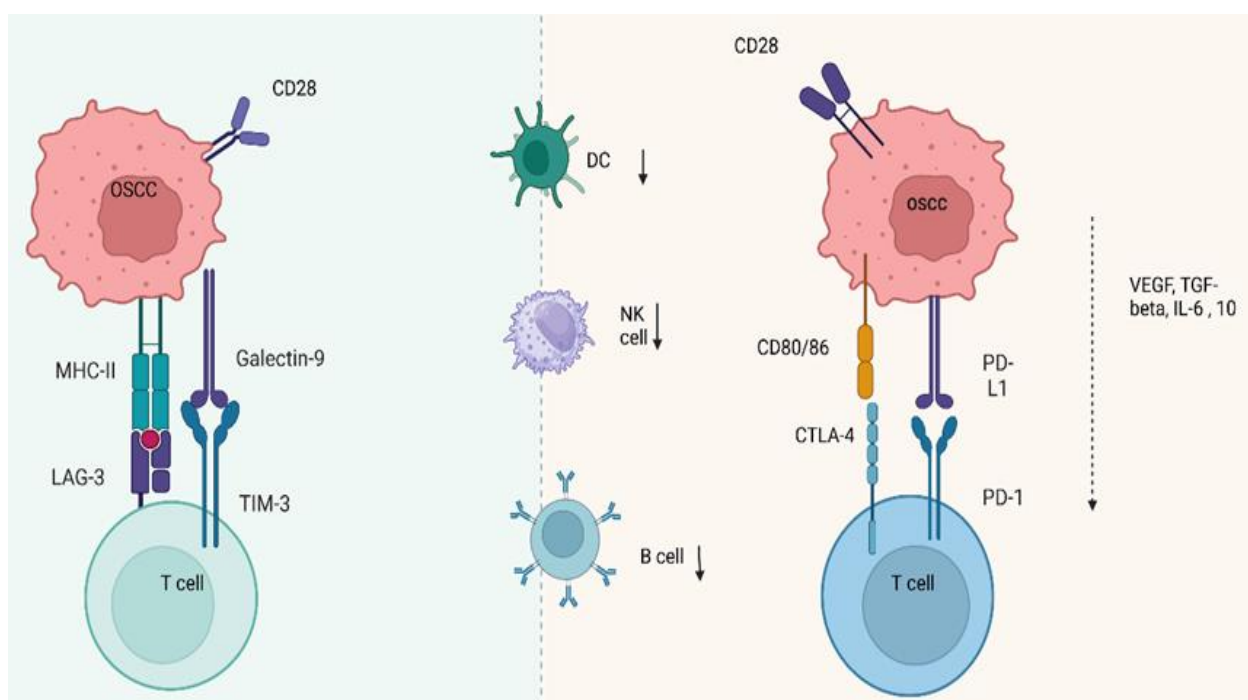
The investigation carried out by Licitra et al. was a historical analysis, with participant enrollment spanning from 1989 to 1999. The chemotherapy regimen employed for induction was CF (cisplatin + fluorouracil) (65). Recent findings have indicated that the addition of docetaxel to the CF regimen, creating the DCF combination, may improve oncological results. In this context, Chaukar et al. chose to implement the more effective DCF induction chemotherapy regimen. Notably, the objective response rate achieved with DCF in Chaukar et al.'s research was relatively modest at 38%, particularly when juxtaposed with the 82% response rate noted by Licitra et al. (65, 66).

This variation underscores the difficulties in utilizing radiologic response criteria to accurately forecast pathological responses in advanced head and neck cancer following induction chemotherapy. Nevertheless, the mandibular preservation rate reported in the previous study was promising, further supporting the choice of DCF as the preferred induction chemotherapy regimen. A retrospective analysis was performed on the medical records of patients diagnosed with locoregionally advanced (stage III and IV) oral cavity squamous cell carcinoma who underwent induction chemotherapy (IC) followed by definitive local treatment.

The primary outcomes assessed were the response to IC and overall survival rates. The study included a total of 120 patients, with 79.2% classified as stage IV. Following two cycles of IC, 76 (63.3%) patients demonstrated at least a partial response, which

included 13 patients achieving a complete response. Stable disease was noted in 30 (25%) patients, while 14 (11.7%) patients experienced disease progression. Among those who responded, 16 patients received definitive chemoradiation or radiation therapy, and 60 underwent surgical resection, with 15 of these patients having less extensive surgery than initially planned. Organ preservation was successfully achieved in 40.8% of patients who responded favorably to IC. The 5-year overall survival and disease-specific survival rates were recorded at 51.4% and 66.9%, respectively. Patients with at least a partial response exhibited improved 5-year overall survival (60.1%) and disease-

specific survival (78.5%) compared to non-responders, who had rates of 33.8% and 46.4%, respectively. These findings indicate that the response rate to IC in patients with advanced OSCC is comparable to that seen in other head and neck cancer sites. Those achieving at least a partial response to IC experienced better outcomes, including organ preservation (67). Patients diagnosed with HPV-associated locally advanced squamous cell carcinoma of the head and neck (LA SCCHN) typically exhibit more favorable prognoses, enhanced therapeutic responses, and extended overall survival (OS) when compared to those with HPV-negative variants.



**Figure 3. The immune response plays a crucial role in OSCC development. Programmed death 1 (PD-1), programmed death ligand-1 (PD-L1), cytotoxic T-lymphocyte-associated antigen 4 (CTLA-4), vascular endothelial growth factor (VEGF), transforming growth factor (TGF)- $\beta$ , interleukin (IL)-6, and IL-10, The major histocompatibility complex (MHC), Lymphocyte-activation gene 3.**

The prognostic significance of HPV and p16 positivity has been established in the induction chemotherapy (ICT) context (utilizing paclitaxel/carboplatin or TPF), where individuals with HPV-positive conditions demonstrated a superior overall response rate (ORR) and more than double the five-year survival statistics as opposed to their HPV-negative counterparts (68, 69).

With in the phase II Eastern Cooperative Oncology Group 1308 trial, Marur et al. proposed that ICT employing cisplatin/paclitaxel/cetuximab could enable

patients with HPV-positive oropharyngeal carcinoma, possessing an otherwise promising prognosis, to receive reduced-dose intensity-modulated radiation therapy (IMRT) without compromising therapeutic effectiveness. This strategy for chemoradiotherapy de-escalation resulted in a marked reduction in radiotherapy-related toxicities, such as dysphagia and nutritional impairment, in comparison to patients undergoing standard-dose IMRT. Although the evidence regarding the efficacy of ICT in patients with HPV-related LA SCCHN remains incomplete, these

preliminary studies indicate a potential role for ICT in the deintensification of treatment for those with favorable prognoses (70).

### **Surgical margins following induction chemotherapy and adjuvant therapy**

A key factor in the use of induction chemotherapy, particularly for patients with borderline resectable or unresectable tumors, is the decision to assess surgical margin status before induction chemotherapy or to concentrate exclusively on the residual tumor volume post-treatment for surgical resection. In the study by Licitra et al., the initial surgical strategy was determined by the original tumor dimensions; however, the ultimate choice regarding surgical resection was entrusted to the operating surgeon, contingent upon achieving a macroscopic margin of 1.5cm. Positive surgical margins were identified in 4(4%) patients from the induction chemotherapy cohort and in 12 (12.4%) patients from the upfront surgery cohort. Among those who received induction chemotherapy, 27 (33%) patients attained complete pathological remission or exhibited only microscopic residual tumors (65).

A matched-pair analysis comparing patients with T4 buccal mucosa tumors who underwent induction chemotherapy for technically unresectable disease (with wide margins around the post-induction tumor volume) and those with technically resectable T4 tumors who had upfront surgery (with a gross margin of 1 cm) showed no significant difference in margin positivity rates between the two groups (71, 72). Likewise, in the research conducted by Chaukar et al., surgical margins were evaluated based on tumor volume following induction chemotherapy. To reduce the likelihood of residual microscopic tumor islands due to nonconcentric tumor shrinkage from induction chemotherapy, all patients in the induction chemotherapy group received adjuvant cisplatin-based concurrent chemoradiotherapy, regardless of their pathological risk factors. Importantly, none of the patients in Chaukar et al.'s study had positive margins, and the rate of pathological complete remission was noted at 11.8% (73).

### **Recommendation**

For patients with locally advanced oral squamous cell carcinoma requiring mandibulectomy, yet lacking clinical and radiographic signs of mandibular erosion,

a potential approach for organ preservation could involve induction chemotherapy consisting of three cycles of docetaxel, cisplatin, and fluorouracil (FU). This would be followed by an attempt at mandibular preservation surgery, which may be guided by the tumor volume post-induction chemotherapy, along with adjuvant concurrent chemoradiotherapy. This strategy aimed to maintain oncologic survival outcomes in carefully selected patients. A multidisciplinary discussion and a patient-centered approach are essential for identifying suitable candidates for this treatment.

### **Alternative strategies to Cisplatin combined with radiotherapy as adjuvant treatment**

The standard treatment protocol for patients with high-risk features, such as perineural invasion (pENE) and/or positive surgical margins, currently involves postoperative concurrent chemoradiotherapy (CRT) with high-dose cisplatin administered at 100 mg/m<sup>2</sup> every three weeks. This treatment has demonstrated improvements in locoregional control (LRC), disease-free survival (DFS), and overall survival (OS) (74). However, it is accompanied by both acute and long-term side effects, including ototoxicity and nephrotoxicity. Furthermore, a considerable number of patients may be unsuitable for platinum-based therapies or may experience difficulties in tolerating them. As a result, various alternative approaches to high-dose cisplatin have been investigated.

One early strategy involved altering the administration schedule by reducing the dose and providing cisplatin every week. Research conducted by Noronha et al. revealed that a once-weekly cisplatin regimen at 30 mg/m<sup>2</sup>, in conjunction with adjuvant radiation, was not noninferior to the standard high-dose treatment and led to a significant reduction in LRC (75). In contrast, Kiyota et al. discovered that increasing the weekly cisplatin dose to 40 mg/m<sup>2</sup> resulted in noninferior OS when compared to the high-dose regimen administered every three weeks. The weekly cisplatin regimen was linked to considerable adverse events, with 71.6% of patients experiencing acute grade 3 or higher toxicities in the once-weekly cisplatin cohort. Although this percentage is lower than the 84.6% of grade 3 or higher toxicities seen in the once-every-3-weeks cisplatin group, it remains a significant issue. Consequently, the search for alternatives to cisplatin continued (76).

### Alternatives to Cisplatin for platinum-fit patients

There are several reasons to explore alternatives to cisplatin for patients who are considered fit, including the potential for enhanced efficacy or reduced toxicity. A phase III randomized controlled trial aimed at determining whether the addition of carboplatin to radiation would yield better outcomes was halted prematurely due to insufficient participant enrollment; it ultimately indicated no improvement in disease-free survival with carboplatin addition. While direct comparisons between cetuximab and cisplatin as adjuvant chemoradiotherapy (CRT) for oral squamous cell carcinoma (OSCC) are lacking, extrapolated data from definitive treatment settings suggest that cetuximab may not be a suitable choice for patients eligible for platinum-based therapy (77).

Efforts to intensify treatment by incorporating immune checkpoint inhibitors alongside standard cisplatin-based CRT, such as avelumab in the JAVELIN Head and Neck trial and pembrolizumab in KEYNOTE-412, have not demonstrated improved outcomes. The GORTEC 2017-01 (REACH) study, which assessed the combination of immunotherapy with cetuximab versus cisplatin CRT in non-operated locally advanced head and neck cancer patients within the cisplatin-fit cohort, has been recently terminated due to futility. In the adjuvant context, the most promising findings involve the combination of docetaxel and cetuximab. A noninferiority trial is currently underway to compare docetaxel with high-dose cisplatin in conjunction with radiotherapy in both adjuvant and definitive CRT scenarios (78, 79).

A recent study published involving 900 patients with resected stage III/IV oral squamous cell carcinoma and at least one adverse prognostic histopathological feature found no significant differences in oncological outcomes—local recurrence control (LRC), disease-free survival (DFS), or overall survival (OS)—across the three treatment arms. These included arm A, which received standard adjuvant radiotherapy (60 Gy in 30 fractions, administered five days a week over six weeks); arm B, which underwent concurrent chemoradiotherapy with weekly cisplatin (30 mg/m<sup>2</sup> for six cycles) alongside standard radiation; and arm C, which was treated with accelerated radiation (60 Gy in 30 fractions, six days a week over five weeks). Notably, patients classified as high-risk (specifically those with T3-4 N2-3 disease and perineural invasion) demonstrated significantly

improved DFS and OS when chemotherapy was added to standard radiation or when radiation was accelerated (80). Nanotechnologies, such as pH-sensitive nanocarriers, show promise in enhancing drug delivery to OSCC tumors while minimizing side effects on normal tissues. A novel nanocomposite (DOX@NGO-BBN-AF750) demonstrated effective tumor targeting and controlled drug release, suggesting potential for imaging-guided therapy in OSCC. The findings indicate that targeted therapies could significantly improve pharmacological treatment outcomes for OSCC patients (81).

### Metformin combined with 4SC-202

Metformin has been shown to inhibit the invasion and migration of various cancers, such as bladder, prostate, and pancreatic cancer, through the mechanism of STAT3 inhibition. 4SC-202 is an innovative selective inhibitor of class I histone deacetylases (HDACi) (82). The class I HDAC, HDAC3, interacts with STAT3, and the inhibition of HDAC3 by HDACi leads to a reduction in STAT3 phosphorylation. Consequently, one potential reason for the inhibition of STAT3 by 4SC-202 is its role as a selective class I HDAC inhibitor, which diminishes the enzymatic function of HDAC3, thereby inactivating STAT3 (83).

It can be inferred that both metformin and 4SC-202 achieve their STAT3-inhibiting effects through distinct mechanisms, necessitating further investigation to clarify the precise pathways involved. The combination of metformin and 4SC-202 has been shown to inhibit OSCC cell migration and invasion by suppressing key signaling pathways. Metformin, already used for type II diabetes, could be easily integrated into clinical practice alongside 4SC-202, enhancing anticancer effects while reducing side effects (84). In a reported experimental study, human OSCC cell lines HSC6 and CAL33 were treated with metformin (16 mM) and 4SC-202 (0.4 μM) for 72 hours. The STAT3 inhibitor S31-201 was administered at a concentration of 60 μM for 48 hours.

The results indicated that metformin and/or 4SC-202 effectively inhibited the migration and invasion of OSCC cells. Notably, both metformin and 4SC-202 reduced the expression of TWIST1, and the inhibitory effects on migration and invasion were reversed by the overexpression of TWIST1. Additionally, the phosphorylation of STAT3 was found to be diminished following treatment with metformin and/or 4SC-202.

Moreover, the use of S31-201 to inhibit signal transducer and activator of transcription 3 (STAT3) resulted in decreased twist family BHLH transcription factor 1 (TWIST1) expression and a reduction in OSCC migration and invasion, which was mitigated by the overexpression of TWIST1. So, metformin and 4SC-202 hinder the invasion and migration of OSCC cells by targeting the STAT3/TWIST1 pathway, presenting a potential new therapeutic approach for OSCC (82).

### **Procyanidin B2 (PB2)**

Procyanidin B2 (PB2) serves as a significant individual component of procyanidin. It is frequently utilized to standardize the procyanidin content in grape seed extract. Research has indicated that PB2 can enhance autophagy and induce apoptosis in colorectal cancer cells via the phosphatidylinositol-4, 5-bisphosphate 3-kinase (PI3K)/protein kinase B (Protein kinase B) signaling pathway, and it also exhibits cytotoxic effects on breast cancer cells. PB2 has been found to inhibit angiogenesis and cell growth in OCSCC through the VEGF/VEGFR2 pathway. Research demonstrated that PB2 treatment led to reduced viability and migration of OCSCC cells, indicating its potential as an adjuvant therapy. Further preclinical and clinical studies are needed to confirm these findings (81, 85).

### **Cetuximab and Cisplatin-conjugated gold nanoparticles**

In previous studies, gold nanoparticles (GNPs) were synthesized and effectively conjugated with cetuximab and cisplatin. Both GNP-treated and untreated cells were subjected to 6 MV X-ray irradiation, and colony formation assays were conducted to evaluate the long-term effects of GNPs and the nanodrug complex on radiotherapy-resistant oral cavity cancer cells. The findings showed that GNPs effectively entered tumor cells, leading to a notable decrease in viability for GNP-CDDP and GNP-CDDP-CTX (a combination of gold nanoparticles (GNP) conjugated with cisplatin (CDDP) and potentially other therapeutic agents (CTX)). The combination of GNP and GNP-CTX with radiotherapy produced a more substantial decrease in UPCI-SCC-131 colony counts compared to radiation alone and radiation with free cetuximab, yielding sensitizing enhancement ratios of 1:2 and 1:9, respectively (86, 87). PEGylated gold nanoparticle complexes enhance

the efficacy of cisplatin and cetuximab, potentially reducing the required doses and associated toxicity. These nanodrugs have shown increased cytotoxicity and improved radiotherapy effectiveness in resistant oral cavity cancer cells. In conclusion, the cetuximab and cisplatin-conjugated gold nanodrug complex demonstrate significant potential to enhance cytotoxicity and address resistance to radiotherapy in the treatment of oral cavity cancer (88, 89).

### **Cisplatin + Paclitaxel**

The concomitant administration of cisplatin and paclitaxel may effectively address drug resistance in OCSCC, with paclitaxel augmenting the therapeutic efficacy of cisplatin. Investigative studies have shown that the overexpression of forkhead box protein M1 (FOXO1) plays a pivotal role in mediating resistance, thereby implying that monotherapy with paclitaxel could yield greater therapeutic advantages following the failure of cisplatin treatment. This combinatory approach necessitates further exploration to optimize treatment regimens (90).

### **Anlotinib**

Anlotinib is a newly developed oral multitarget receptor tyrosine kinase inhibitor that received its initial approval for use as a third-line treatment in patients with refractory advanced non-small-cell lung cancer. It demonstrates promising effectiveness and manageable safety profiles across various malignant tumors, such as medullary thyroid cancer, renal cell carcinoma, gastric cancer, and esophageal squamous cell carcinoma, by modulating tumor cell proliferation, apoptosis, angiogenesis, migration, and invasion (91, 92). Anlotinib has shown a tolerable safety profile and significant efficacy in inhibiting the spread of OCSCC cells through the PI3K/Protein kinase B pathway. The findings support the potential use of anlotinib in treating OCSCC, although further studies are necessary to validate these results. Akt is a crucial kinase that is activated by numerous cellular signals and has been documented to play a role in several essential physiological processes within cells, such as proliferation, apoptosis, autophagy, resistance, migration, and invasion. Research has indicated that a range of intracellular and extracellular factors can enhance the expression and migration of MMP-2 and MMP-9 through the activation of the Protein kinase B signaling pathway in OSCC (91).

### **Nimotuzumab**

Nimotuzumab, when combined with ALA-based photodynamic therapy, demonstrated enhanced efficacy in OCSCC treatment with a favorable safety profile. Preclinical studies showed significant tumor growth reduction and potential for complete remission in treated mice. These promising results highlight the need for further clinical studies to confirm the benefits of this combination therapy (93, 94).

### **Trametinib**

Trametinib has shown promise in reducing Ras/MEK/ERK pathway activation in OCSCC patients, leading to significant clinical benefits. A notable percentage of patients exhibited tumor response and downstaging after trametinib treatment before surgery. These findings suggest trametinib as a viable therapeutic option for OCSCC, warranting further exploration (95).

### **Nivolumab**

Nivolumab demonstrated a 33% overall response rate in a phase-II trial for OCSCC, indicating its safety and tolerability as a neoadjuvant therapy. The survival rate of approximately 80% among treated patients underscores its potential as a treatment option. These results support the further investigation of nivolumab in OCSCC management (96).

### **Nanoengineered Cisplatin**

The development of a self-adhesive cisplatin transmucosal system (PRV111) aims to enhance targeted drug delivery for oral cancers while minimizing systemic exposure. Preclinical studies showed superior efficacy and safety of PRV111 compared to traditional cisplatin administration. The promising results from early trials suggest that PRV111 could improve treatment outcomes for OCSCC patients (97).

### **Camrelizumab + Apatinib**

The combination of camrelizumab and apatinib showed a 40% major pathological response rate in patients with locally advanced OCSCC. The treatment was well-tolerated, with promising survival rates and local recurrence outcomes. These findings indicate that this combination therapy could enhance treatment efficacy for OCSCC patients (98, 99).

## **Discussion**

In summary, the exploration of oral cavity squamous cell carcinoma (OCSCC) reveals several critical insights into its treatment and underlying mechanisms: Understanding the molecular interactions between tumor cells and their microenvironment is essential for developing effective systemic therapies. This knowledge can inform future therapeutic strategies and improve patient outcomes. The combination of Nimotuzumab with ALA-based photodynamic therapy has shown promising results in preclinical studies, indicating a potential for enhanced efficacy and safety in OCSCC treatment. However, further clinical studies are necessary to validate these findings. The management of surgical margins is crucial, especially following induction chemotherapy. Studies indicate that achieving clear surgical margins is vital for reducing the risk of residual disease. The choice of surgical strategy should be tailored based on tumor characteristics and response to treatment.

For patients with advanced or borderline resectable tumors, induction chemotherapy can be a viable option. It allows for the assessment of tumor response and can guide subsequent surgical decisions, potentially leading to better oncologic outcomes. The role of human papillomavirus (HPV) in head and neck cancers, while more pronounced in oropharyngeal cases, still warrants attention in OCSCC. Understanding its carcinogenic mechanisms may provide insights into patient prognosis and treatment responses. Overall, the ongoing research into the risk factors, molecular mechanisms, and innovative treatment strategies for OCSCC is crucial for improving patient care and outcomes. A multidisciplinary approach, incorporating the latest findings and technologies, will be essential in addressing the challenges posed by this aggressive cancer type.

### **Future Directions in Research on Oral Cavity Squamous Cell Carcinoma**

There is a critical need for in-depth research into the molecular pathways linked to OCSCC, particularly those related to EGFR overexpression and its impact on treatment efficacy. A clearer understanding of these mechanisms could aid in developing targeted therapies that improve patient outcomes. Promising results from studies combining Nimotuzumab with ALA-based



photodynamic therapy highlight the need for additional clinical trials to evaluate the effectiveness and safety of this combination in OCSCC patients, potentially leading to new treatment guidelines. Future research should focus on refining induction chemotherapy protocols, such as the combination of docetaxel, cisplatin, and fluorouracil, to assess their effectiveness in organ preservation and overall survival for advanced OCSCC patients. Given the rising incidence of oral tongue cancers, especially in patients lacking traditional risk factors like tobacco and alcohol use, it is crucial to explore new risk factors or exposures that may contribute to OCSCC, which could inform preventive measures. Additionally, the relationship between air pollution—particularly PM2.5 levels—and oral carcinoma risk requires further investigation into how environmental factors influence OCSCC onset. Prioritizing a multidisciplinary, patient-centered approach is essential in treatment planning, and future efforts should establish frameworks to enhance patient selection for innovative therapies, ensuring that treatment plans are tailored to individual needs.

## References

1. Ettinger KS, Ganry L, Fernandes RP. Oral cavity cancer. *Oral Maxillofac Surg Clin North Am* 2019;31(1):13-29.
2. Hernández-Morales A, González-López BS, Scougall-Vilchis RJ, et al. Lip and oral cavity cancer incidence and mortality rates associated with smoking and chewing tobacco use and the human development index in 172 countries worldwide: an ecological study 2019–2020. *Healthcare*. 2023;11(8):1063.
3. Infante-Cossio P, Duran-Romero A-J, Castaño-Seiquer A, et al. Estimated projection of oral cavity and oropharyngeal cancer deaths in Spain to 2044. *BMC Oral Health* 2022;22(1):444.
4. Montero PH, Patel SG. Cancer of the oral cavity. *Surg Oncol Clin N Am* 2015;24(3):491-508.
5. Lambert R, Sauvaget C, de Camargo Cancela M, et al. Epidemiology of cancer from the oral cavity and oropharynx. *Eur J Gastroenterol Hepatol* 2011;23(8):633-41.
6. Ernani V, Saba NF. Oral cavity cancer: risk factors, pathology, and management. *Oncology* 2015;89(4):187-95.
7. Chamoli A, Gosavi AS, Shirwadkar UP, et al. Overview of oral cavity squamous cell carcinoma: Risk factors, mechanisms, and diagnostics. *Oral Oncol* 2021;121:105451.
8. Nokovitch L, Maquet C, Crampon F, et al. Oral cavity squamous cell carcinoma risk factors: state of the art. *J Clin Med* 2023;12(9):3264.
9. Young A, Okuyemi OT. Malignant Salivary Gland Tumors. [Updated 2023 Jan 12]. In: StatPearls [Internet]. Treasure Island (FL): StatPearls Publishing; 2025.PMID: 33079504.
10. Warnakulasuriya S, Kujan O, Aguirre- Urizar JM, et al. Oral potentially malignant disorders: A consensus report from an international seminar on nomenclature and classification, convened by the WHO Collaborating Centre for Oral Cancer. *Oral Dis* 2021;27(8):1862-80.
11. Ojeda D, Huber MA, Kerr AR. Oral potentially malignant disorders and oral cavity cancer. *Dermatol Clin* 2020;38(4):507-21.
12. George A, Sreenivasan B, Sunil S, et al. Potentially malignant disorders of the oral cavity. *Oral Maxillofac Pathol J*. 2011;2(1):95-100.
13. Gonzalez-Moles MA, Warnakulasuriya S, Ramos-Garcia P. Prognosis parameters of oral carcinomas developed in proliferative verrucous leukoplakia: A systematic review and meta-analysis. *Cancers*. 2021 Sep 28;13(19):4843.
14. Capella DL, Gonçalves JM, Abrantes AAA, et al. Proliferative verrucous leukoplakia: diagnosis, management and current advances☆. *Braz J Otorhinolaryngol* 2017;83(5):585-93.
15. Roza AL, Kowalski LP, William Jr WN, et al. Oral leukoplakia and erythroplakia in young patients: a systematic review. *Oral surgery, oral medicine, oral pathology, and oral radiology*. 2021 Jan 1;131(1):73-84.
16. González-Moles MÁ, Warnakulasuriya S, Gonzalez-Ruiz I, et al. Clinicopathological and prognostic characteristics of oral squamous cell carcinomas arising in patients with oral lichen planus: A systematic review and a comprehensive meta-analysis. *Oral Oncology*. 2020 Jul 1;106:104688.
17. Mamrak NE, Shimamura A, Howlett NG. Recent discoveries in the molecular pathogenesis of the inherited bone marrow failure syndrome Fanconi anemia. *Blood Rev* 2017;31(3):93-9.

18. Santana NCM, de Sena ACVP, da Silva Rocha PA, et al. Oral cancer and oral potentially malignant disorders in patients with Fanconi anemia–A systematic review. *Oral Oncol* 2024;150:106699.
19. Manfuso A, Risitano AM, Copelli C. Dyskeratosis congenita and squamous cell carcinoma of the mandibular alveolar ridge. *BMJ Case Rep* 2021;14(5):e242459.
20. Paget-Bailly S, Cyr D, Luce D. Occupational exposures to asbestos, polycyclic aromatic hydrocarbons and solvents, and cancers of the oral cavity and pharynx: a quantitative literature review. *Int Arch Occup Environ Health* 2012;85(4):341-51.
21. Bagnardi V, Rota M, Botteri E, et al. Alcohol consumption and site-specific cancer risk: a comprehensive dose-response meta-analysis. *Br J Cancer* 2015;112(3):580-93.
22. Freedman N, Schatzkin A, Leitzmann M, et al. Alcohol and head and neck cancer risk in a prospective study. *Br J Cancer* 2007;96(9):1469-74.
23. Du X, Squier C, Kremer M, et al. Penetration of N- nitrosonornicotine (NNN) across oral mucosa in the presence of ethanol and nicotine. *J Oral Pathol Med* 2000;29(2):80-5.
24. Blot WJ, McLaughlin JK, Winn DM, et al. Smoking and drinking about oral and pharyngeal cancer. *Cancer Res* 1988;48(11):3282-87.
25. Mello FW, Melo G, Pasetto JJ, et al. The synergistic effect of tobacco and alcohol consumption on oral squamous cell carcinoma: a systematic review and meta-analysis. *Clin Oral Investig* 2019;23(7):2849-59.
26. Ralbovsky NM, Zhang Y, Williams DM, et al. Machine Learning and Hyperspectral Imaging for Analysis of Human Papillomaviruses (HPV) Vaccine Self-Healing Particles. *Anal Chem*. 2024;96(43):17118-27.
27. Nauta IH, Heideman DA, Brink A, et al. The unveiled reality of human papillomavirus as risk factor for oral cavity squamous cell carcinoma. *Int J Cancer* 2021;149(2):420-430.
28. Skálová A, Hycza MD, Leivo I. Update from the 5th edition of the World Health Organization classification of head and neck tumors: salivary glands. *Head Neck Pathol*. 2022;16(1):40-53.
29. Thompson L. World Health Organization classification of tumours: pathology and genetics of head and neck tumours. *Ear Nose Throat J*. 2006;85(2):74.
30. Melo BAdC, Vilar LG, Oliveira NRd, et al. Human papillomavirus infection and oral squamous cell carcinoma systematic review. *Braz J Otorhinolaryngol* 2021;87(3):346-52.
31. Christianto S, Li KY, Huang TH, et al. The Prognostic Value of Human Papilloma Virus Infection in Oral Cavity Squamous Cell Carcinoma: A Meta- Analysis. *Laryngoscope* 2022;132(9):1760-70.
32. Di Spirito F, Di Palo MP, Folliero V, et al. Oral Bacteria, Virus and Fungi in Saliva and Tissue Samples from Adult Subjects with Oral Squamous Cell Carcinoma: An Umbrella Review. *Cancers*. 2023; 15(23):5540.
33. Saber Amoli S, Hasanzadeh A, Sadeghi F, et al. Prevalence of Co-infection by Human Papillomavirus, Epstein-Barr Virus and Merkel Cell Polyomavirus in Iranian Oral Cavity Cancer and Pre-malignant Lesions. *Int J Mol Cell Med*. 2022;11(1):64-77.
34. Scussiatto HO, Stenson KM, Al-Khudari S, et al. Air pollution is associated with increased incidence rate of head and neck cancers: A nationally representative ecological study. *Oral Oncol* 2024;150:106691.
35. Chu Y-H, Kao S-W, Tantoh DM, et al. Association between fine particulate matter and oral cancer among Taiwanese men. *J Investig Med* 2019;67(1):34-8.
36. Castro SA, Sassi LM, Torres-Pereira CC, et al. Occupations associated with head and neck cancer in a city in Southern Brazil, 1998 to 2012. *Rev Bras Med Trab* 2019;17(1):130.
37. Yuk J-S, Kim BY. Relationship between menopausal hormone therapy and oral cancer: a cohort study based on the health insurance database in South Korea. *J Clin Med* 2022;11(19):5848.
38. Grimm M, Biegner T, Teriete P, et al. Estrogen and Progesterone hormone receptor expression in oral cavity cancer *Med Oral Patol Oral Cir Bucal* 2016;21(5):e554.
39. Saranya R, Chandini R, Mohideen K, et al. Expression of sex hormones in oral squamous cell carcinoma: a systematic review on immunohistochemical studies. *Cureus* 2022;14(5):e25384.

40. Rothenberger NJ, Somasundaram A, Stabile LP. The role of the estrogen pathway in the tumor microenvironment. *Int J Mol Sci* 2018;19(2):611.
41. Lukits J, Remenár E, Rásó E, et al. Molecular identification, expression and prognostic role of estrogen-and progesterone receptors in head and neck cancer. *Int J Oncol* 2007;30(1):155-160.
42. Ali K, Alam S, Kamran N, et al. Immunohistochemical (IHC) Expression of p16 in Various Grades of Oral Squamous Cell Carcinoma (OSCC) with Snuff Use in Tertiary Care Hospitals of Peshawar. *Pak J Health Sci.* 2024;5(4):109-15.
43. Chuang S-C, Jenab M, Heck JE, et al. Diet and the risk of head and neck cancer: a pooled analysis in the INHANCE consortium. *Cancer Causes Control* 2012;23(1):69-88.
44. Kawakita D, Sato F, Hosono S, et al. Inverse association between yoghurt intake and upper aerodigestive tract cancer risk in a Japanese population. *Eur J Cancer Prev* 2012;21(5):453-9.
45. Mello FW, Scotti FM, Melo G, et al. Maté consumption association with upper aerodigestive tract cancers: A systematic review and meta-analysis. *Oral Oncol* 2018;82:37-47.
46. Turati F, Galeone C, La Vecchia C, et al. Coffee and cancers of the upper digestive and respiratory tracts: meta-analyses of observational studies. *Ann Oncol* 2011;22(3):536-44.
47. Lucenteforte E, Garavello W, Bosetti C, et al. Dietary factors and oral and pharyngeal cancer risk. *Oral Oncol* 2009;45(6):461-7.
48. Filomeno M, Bosetti C, Garavello W, et al. The role of a Mediterranean diet on the risk of oral and pharyngeal cancer. *Br J Cancer* 2014;111(5):981-6.
49. Gupta B, Bray F, Kumar N, et al. Associations between oral hygiene habits, diet, tobacco and alcohol and risk of oral cancer: A case-control study from India. *Cancer Epidemiol* 2017;51:7-14.
50. Friemel J, Foraita R, Günther K, et al. Pretreatment oral hygiene habits and survival of head and neck squamous cell carcinoma (HNSCC) patients. *BMC oral health.* 2016;16:33.
51. Chang JS, Lo H-I, Wong T-Y, et al. Investigating the association between oral hygiene and head and neck cancer. *Oral Oncol* 2013;49(10):1010-7.
52. Ahrens W, Pohlabein H, Foraita R, et al. Oral health, dental care and mouthwash associated with upper aerodigestive tract cancer risk in Europe: the ARCAGE study. *Oral Oncol* 2014;50(6):616-25.
53. Araujo JSSd, Magalhães EIdS, Lima HLdO, et al. Mouthwash use and oral cancer: a systematic review and meta-analysis. *Rev Saude Publica* 2023;57:90.
54. Williams H. Molecular pathogenesis of oral squamous carcinoma. *Mol Pathol* 2000;53(4):165-72.
55. Sharma M, Shetty SS, Radhakrishnan R. Oral submucous fibrosis as an overhealing wound: Implications in malignant transformation. *Recent Pat Anticancer Drug Discov* 2018;13(3):272-91.
56. Kalyankrishna S, Grandis JR. Epidermal growth factor receptor biology in head and neck cancer. *J Clin Oncol* 2006;24(17):2666-72.
57. Taoudi Benckroun M, Saintigny P, Thomas SM, et al. Epidermal growth factor receptor expression and gene copy number in the risk of oral cancer. *Cancer Prev Res* 2010;3(7):800-09.
58. Prior IA, Lewis PD, Mattos C. A comprehensive survey of Ras mutations in cancer. *Cancer Res* 2012;72(10):2457-67.
59. Hamidavi Asl A, Shirkhoda M, Saffar H, et al. Analysis of H-ras Mutations and Immunohistochemistry in Recurrence Cases of High-Grade Oral Squamous Cell Carcinoma. *Head Neck Pathol* 2023;17(2):347-54.
60. Madden SK, de Araujo AD, Gerhardt M, et al. Taking the Myc out of cancer: toward therapeutic strategies to directly inhibit c-Myc. *Mol Cancer* 2021;20(1):3.
61. Dhanasekaran R, Deutzmann A, Mahauad-Fernandez WD, et al. The MYC oncogene—the grand orchestrator of cancer growth and immune evasion. *Nat Rev Clin Oncol* 2022;19(1):23-36.
62. Jares P, Fernández PL, Campo E, et al. PRAD-1/cyclin D1 gene amplification correlates with messenger RNA overexpression and tumor progression in human laryngeal carcinomas. *Cancer Res* 1994;54(17):4813-17.
63. Chin D, Boyle GM, Theile DR, et al. Molecular introduction to head and neck cancer (HNSCC) carcinogenesis. *Br J Plast Surg* 2004;57(7):595-602.
64. Lese CM, Rossie KM, Appel BN, et al. Visualization of INT2 and HST1 amplification in oral squamous cell carcinomas. *Genes Chromosomes Cancer* 1995;12(4):288-95.
65. Licitra L, Grandi C, Guzzo M, et al. Primary chemotherapy in resectable oral cavity squamous

- cell cancer: a randomized controlled trial. *J Clin Oncol* 2003;21(2):327-33.
66. Chaukar D, Thiagarajan S. Neoadjuvant chemotherapy in oral cancer: Current status and future possibilities-Its benefit for T4 oral cancer is yet to be tested. *Cancer Res Stat Treat* 2020;3(2):389-90.
  67. Abdelmeguid AS, Silver NL, Boonsripitayanon M, et al. Role of induction chemotherapy for oral cavity squamous cell carcinoma. *Cancer* 2021;127(17):3107-12.
  68. Misiukiewicz K, Gupta V, Miles B, et al. Standard of care vs reduced-dose chemoradiation after induction chemotherapy in HPV+ oropharyngeal carcinoma patients: The Quarterback trial. *Oral Oncol* 2019;95:170-7.
  69. Ang KK, Harris J, Wheeler R, et al. Human papillomavirus and survival of patients with oropharyngeal cancer. *N Engl J Med* 2010;363(1):24-35.
  70. Marur S, Li S, Cmelak AJ, et al. E1308: phase II trial of induction chemotherapy followed by reduced-dose radiation and weekly cetuximab in patients with HPV-associated resectable squamous cell carcinoma of the oropharynx—ECOG-ACRIN Cancer Research Group. *J Clin Oncol* 2017;35(5):490-7.
  71. Mohamad I, Glaun MD, Prabhash K, et al. Current treatment strategies and risk stratification for oral carcinoma. *Am Soc Clin Oncol Educ Book* 2023;43:e389810.
  72. Yoon DY, Hwang HS, Chang SK, et al. CT, MR, US, 18 F-FDG PET/CT, and their combined use for the assessment of cervical lymph node metastases in squamous cell carcinoma of the head and neck. *Eur Radiol* 2009;19(3):634-42.
  73. Chaukar D, Prabash K, Rane P, et al. Prospective phase II open-label randomized controlled trial to compare mandibular preservation in upfront surgery with neoadjuvant chemotherapy followed by surgery in operable oral cavity cancer. *J Clin Oncol* 2022;40(3):272-81.
  74. Bernier J, Cooper JS, Pajak T, et al. Defining risk levels in locally advanced head and neck cancers: a comparative analysis of concurrent postoperative radiation plus chemotherapy trials of the EORTC (# 22931) and RTOG (# 9501). *Head Neck* 2005;27(10):843-50.
  75. Noronha V, Joshi A, Patil VM, et al. Once-a-week versus once-every-3-weeks cisplatin chemoradiation for locally advanced head and neck cancer: a phase III randomized noninferiority trial. *J Clin Oncol* 2018;36(11):1064-72.
  76. Kiyota N, Tahara M, Mizusawa J, et al. Weekly cisplatin plus radiation for postoperative head and neck cancer (JCOG1008): a multicenter, noninferiority, phase II/III randomized controlled trial. *J Clin Oncol* 2022;40(18):1980-90.
  77. Sepahdar Z, Miroliaei M, Bouzari S, et al. Surface engineering of escherichia coli-derived omvs as promising nano-carriers to target EGFR-overexpressing breast cancer cells. *Front Pharmacol* 2021;12:719289.
  78. Machiels J-P, Tao Y, Licitra L, et al. Pembrolizumab plus concurrent chemoradiotherapy versus placebo plus concurrent chemoradiotherapy in patients with locally advanced squamous cell carcinoma of the head and neck (KEYNOTE-412): a randomised, double-blind, phase 3 trial. *Lancet Oncol* 2024;25(5):572-87.
  79. Cramer JD, Burtneess B, Ferris RL. Immunotherapy for head and neck cancer: Recent advances and future directions. *Oral Oncol* 2019;99:104460.
  80. Laskar SG, Chaukar D, Deshpande M, et al. Oral cavity adjuvant therapy (OCAT)-a phase III, randomized controlled trial of surgery followed by conventional RT (5 fr/wk) versus concurrent CT-RT versus accelerated RT (6fr/wk) in locally advanced, resectable, squamous cell carcinoma of oral cavity. *Eur J Cancer* 2023;181:179-87.
  81. Imbesi Bellantoni M, Picciolo G, Pirrotta I, et al. Oral cavity squamous cell carcinoma: an update of the pharmacological treatment. *Biomedicines* 2023;11(4):1112.
  82. Tong D, Liu Q, Liu G, et al. Metformin inhibits castration-induced EMT in prostate cancer by repressing COX2/PGE2/STAT3 axis. *Cancer Lett* 2017;389:23-32.
  83. Theocharis S, Kljjanienko J, Giaginis C, et al. Histone deacetylase- 1 and- 2 expression in mobile tongue squamous cell carcinoma: associations with clinicopathological parameters and patients survival. *J Oral Pathol Med* 2011;40(9):706-14.
  84. He Y, Fan Z, He L, et al. Metformin combined with 4SC-202 inhibited the migration and invasion of

- OSCC via STAT3/TWIST1. *Onco Targets Ther* 2020;11019-29.
85. Sun Q, Zhang T, Xiao Q, et al. Procyanidin B2 inhibits angiogenesis and cell growth in oral squamous cell carcinoma cells through the vascular endothelial growth factor (VEGF)/VEGF receptor 2 (VEGFR2) pathway. *Bioengineered* 2022;13(3):6500-08.
  86. Lepore S, Lettini G, Condelli V, et al. comparative gene expression profiling of tobacco-associated HPV-positive versus negative oral squamous carcinoma cell lines. *Int J Med Sci* 2020;17(1):112-24.
  87. Choi HS, Kim Y-K, Yun P-Y. Cisplatin plus cetuximab inhibits cisplatin-resistant human oral squamous cell carcinoma cell migration and proliferation but does not enhance apoptosis. *Int J Mol Sci* 2021;22(15):8167.
  88. Surer S, Elciteme T, Akçay D, et al. A promising, novel radiosensitizer nanodrug complex for oral cavity cancer: cetuximab and cisplatin-conjugated gold nanoparticles. *Balkan Med J* 2021;38(5):278-86.
  89. Cui S, Liu H, Cui G. Nanoparticles as drug delivery systems in the treatment of oral squamous cell carcinoma: current status and recent progression. *Front Pharmacol* 2023;14:1176422.
  90. Huang G-C, Liu S-Y, Lin M-H, et al. The synergistic cytotoxicity of cisplatin and taxol in killing oral squamous cell carcinoma. *Jpn J Clin Oncol* 2004;34(9):499-504.
  91. Deng Z, Liao W, Wei W, et al. Anlotinib as a promising inhibitor on tumor growth of oral squamous cell carcinoma through cell apoptosis and mitotic catastrophe. *Cancer Cell Int* 2021;21(1):37.
  92. Lu Y, Lin J, Duan M, et al. Anlotinib suppresses oral squamous cell carcinoma growth and metastasis by targeting the RAS protein to inhibit the PI3K/Akt signalling pathway. *Anal Cell Pathol* 2021;2021:5228713.
  93. He X, Hu N, Yang S, et al. Nimotuzumab shows an additive effect to inhibit cell growth of ALA-PDT treated oral cancer cells. *Photodiagnosis Photodyn Ther* 2022;38:102817.
  94. Liangliang T, Xinrong N. The value of NLR in predicting the efficacy of preoperative nimotuzumab combined with neoadjuvant chemotherapy for local advanced oral squamous cell carcinoma. *Journal of Prevention and Treatment for Stomatological Diseases* 2024;32:359-66.
  95. Yee PS, Zainal NS, Gan CP, et al. Synergistic growth inhibition by afatinib and trametinib in preclinical oral squamous cell carcinoma models. *Target Oncol* 2019;14(2):223-35.
  96. Tang X, Chen S, Sui Q, Li X, Liu Z, Zhu F, et al. Response to nivolumab combining radiotherapy and nimotuzumab in metastatic oral squamous cell carcinoma patient with strong PD-L1 expression: a case report. *Ann Transl Med* 2020;8(6):402.
  97. Goldberg M, Manzi A, Birdi A, et al. A nanoengineered topical transmucosal cisplatin delivery system induces anti-tumor response in animal models and patients with oral cancer. *Nat Commun* 2022;13(1):4829.
  98. Zhong L-P, Ju W-t, Xia R-h, et al. Inductive camrelizumab and apatinib for patients with locally advanced and resectable oral squamous cell carcinoma: A single-arm trial (Icemelting trial). *J Clin Oncol* 2021;39(15):6052.
  99. Ju W-t, Xia R-h, Zhu D-w, et al. Neoadjuvant chemo-free combination of camrelizumab and apatinib for locally advanced resectable oral squamous cell carcinoma—A pilot study. *Nat Commun.* 2022;13(1):5378.