

Investigating Genetic Factors Contributing to Variable Expressivity of Class I 17p13.3 Microduplication

Giovanna Cantini Tolezano¹, Silvia Souza da Costa¹, Marília de Oliveira Scliar¹, Walter Luis Magalhães Fernandes², Paulo Alberto Otto³, Débora Romeo Bertola^{1,4}, Carla Rosenberg¹, Angela Maria Vianna-Morgante¹, Ana Cristina Victorino Krepschi^{1*}

1. Human Genome and Stem-Cell Research Center, Department of Genetics and Evolutionary Biology, Institute of Biosciences, University of São Paulo, São Paulo, SP, Brazil.

2. Department of Paediatrics, College of Medicine of Pouso Alegre, Pouso Alegre, MG, Brazil.

3. Department of Genetics and Evolutionary Biology, Institute of Biosciences, University of São Paulo, São Paulo, SP, Brazil.

4. Instituto da Criança, Hospital das Clínicas, University of São Paulo Medical, São Paulo, SP, Brazil.

Submitted 23 October 2020; Accepted 2 January 2021; Published 27 January 2021

17p13.3 microduplications are rare copy number variations (CNVs) associated with variable phenotypes, including facial dysmorphism, developmental delay, intellectual disability, and autism. Typically, when a recognized pathogenic CNV is identified, other genetic factors are not considered. We investigated via whole-exome sequencing the presence of additional variants in four carriers of class I 17p13.3 microduplications. A 730 kb 17p13.3 microduplication was identified in two half-brothers with intellectual disability, but not in a third affected half-brother or blood cells from their normal mother (Family A), thus leading to the hypothesis of maternal germline mosaicism. No additional pathogenic variants were detected in Family A. Two affected siblings carried maternally inherited 450 kb 17p13.3 microduplication (Family B); the three carriers of the microduplication exhibited microcephaly and learning disability/speech impairment of variable degrees. Exome analysis revealed a variant of uncertain significance in *RORA*, a gene already linked to autism, in the autistic boy; his sister was heterozygous for a *CYP11B* pathogenic variant that could be related to her congenital glaucoma. Besides, both siblings carried a loss-of-function variant in *DIP2B*, a candidate gene for intellectual disability, which was inherited from their father, who also exhibited learning disability in childhood. In conclusion, additional pathogenic variants were revealed in two affected carriers of class I 17p13.3 microduplication (Family B), probably adding to their phenotypes. These results provided new evidence regarding the contribution of *RORA* and *DIP2B* to neurocognitive deficits, and highlighted the importance of full genetic investigation in carriers of CNV syndromes with variable expressivity. Finally, we suggest that microcephaly may be a rare clinical feature also related to the presence of the class I 17p13.3 microduplication.

*Corresponding author: Ana C V Krepschi, Institute of Biosciences, University of São Paulo, São Paulo, SP, Brazil.
E-mail: ana.krepischi@ib.usp.br

This work is published as an open access article distributed under the terms of the Creative Commons Attribution 4.0 License (<http://creativecommons.org/licenses/by-nc/4.0>). Non-commercial uses of the work are permitted, provided the original work is properly cited.

Key words: 17p13.3 microduplication, microcephaly, neurodevelopmental disorder, autism, variable expressivity, *RORA*, *CYP11B1*, *DIP2B*

Deletions at 17p13.3 are associated with isolated lissencephaly when encompassing platelet-activating factor acetylhydrolase IB subunit alpha (*PAFAH1B1*, OMIM *601545), the major gene responsible for the phenotype, or with Miller-Dieker lissencephaly syndrome (MDS, OMIM #247200), when the MDS telomeric critical region, containing eight additional genes (*PRPF8*, *RILP*, *SCARF1*, *PITPNA*, *INPP5K*, *MYO1C*, *CRK*, and *YWHAE*), is also deleted (1). MDS, characterized by lissencephaly, dysmorphic facial features, and variable congenital malformations depending on the size of the deletion, presents a more severe cerebral phenotype, with tyrosine 3-monooxygenase/tryptophan 5-monooxygenase activation protein epsilon (*YWHAE*, OMIM *605066) gene being the candidate gene to explain it (2, 3).

Microduplications at 17p13.3 overlapping the MDS region were also documented (2-8; OMIM #613215- chromosome 17p13.3, centromeric, duplication syndrome), although its clinical significance is still poorly understood, probably because they are rarer than 17p13.3 deletions and present variable sizes. Bruno *et al.* (2010) proposed to distinguish 17p13.3 microduplications as class I, when encompassing the *YWHAE* gene, but not *PAFAH1B1*, and class II, involving *PAFAH1B1*, with the inclusion of *YWHAE* and *CRK* being variable (7). Clinical signs shared by individuals carrying either class I or class II microduplications include facial dysmorphisms, intellectual disability, neuropsychomotor developmental delay, and autism spectrum disorder, although none of these features are necessarily present in all patients (4, 8, 9).

The most challenging aspect in determining the contribution of such 17p13.3 microduplications

to the phenotype is the variable clinical manifestation and incomplete penetrance (5, 7, 10, 11); the presence of a known pathogenic CNV is generally assumed to be the main cause of the phenotype, and other factors that could contribute to clinical manifestations are not usually investigated (12-15). Reported patients with 17p13.3 microduplication have not been investigated for concurrent pathogenic mutations, as well as in many other CNV syndromes that exhibit incomplete penetrance and variable expressivity (2-8, 10, 11, 16-18). In neurodevelopmental diseases, this is particularly concerning, considering the two-hit model proposed by Girirajan *et al.* (2010), in which a secondary disruptive event- either another CNV or a point mutation- would result in more severe clinical manifestations. Therefore, mechanisms that may explain the penetrance and expressivity of these conditions are not fully elucidated (12, 19).

In this study, we report two families in which class I 17p13.3 microduplications are segregating with variable clinical pictures. We searched for possible variants contributing to the phenotype of the affected carriers through whole exome sequencing.

Materials and methods

Clinical reports

The Research Ethics Committee of the Institute of Biosciences, University of Sao Paulo, approved this study under the protocol CEP_2589398, and signed informed consents were obtained from the mother in Family A, and from both parents in Family B. Family A includes three affected maternal half-siblings from unrelated fathers (Figure 1a). A-II-2 was born upon 32 weeks gestation; at birth, he developed respiratory distress

evolving to pneumothorax, and had one episode of seizure. He was able to sit up without support at about 3 years of age, walking independently soon after, spoke only isolated words until the age of 4 years, and was toilet trained after 5 years of age. When examined at the age of 9 years, he presented moderate/severe intellectual disability, being dependent on personal hygiene. He also presented hyperactivity and poor balance. Recurrent inner ear infections were reported. His physical examination revealed an occipitofrontal circumference (OFC) of 51cm (2nd-50th centile, -1.1SD), convergent strabismus, and signs of connective tissue involvement (hypoplastic ears, high-arched palate, flat feet, and joint hypermobility). Brain MRI showed corpus callosum dysgenesis.

A-II-3 was delivered at term after an uneventful pregnancy; he sat up without support at the age of 9 months, walked independently at 14 months, spoke the first words at the age of 3.5 years, and was toilet trained at the age of 4 years.

When examined at the age of 8 years, he presented moderate intellectual disability. His physical examination revealed an OFC of 53 cm (50th-98th centile, -1.1SD), and like his brother, signs of connective tissue involvement (mildly hypoplastic ears, high-arched palate, joint hypermobility), besides thin sclera with choroid visible on some spots. Brain MRI did not reveal any alterations.

A-II-4 was delivered at term after an uneventful pregnancy. Although he had normal motor milestones, he presented marked speech delay and intellectual disability; when examined at the age of 6 years, he was able to speak just a few isolated words; he was hyperactive, having been diagnosed with autism spectrum disorder (ASD). His physical examination revealed an OFC of 53 cm (50th-98th centile, +1SD), joint hypermobility, and mild planovalgus feet.

In common, the three half-siblings presented hyperextensible joints, speech impairment, and intellectual disability.

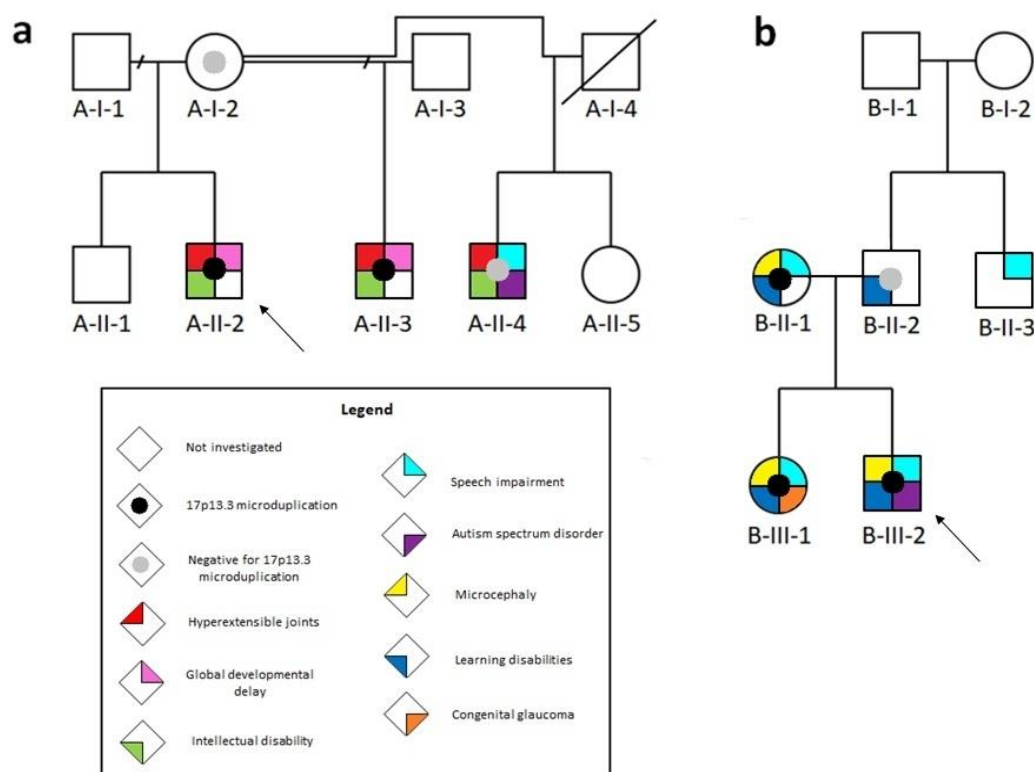


Fig. 1. Pedigrees of Family A (a) and Family B (b). Arrows indicate the proband of each family, and filled symbols represent individuals affected by specific clinical signs, according to the legend.

In Family B, the two affected siblings, a boy and a girl, were born to a non-consanguineous couple (Figure 1b). B-III-1 was born after a 32-week gestation time; her mother was diagnosed with toxoplasmosis in the early period of the pregnancy. The girl had normal newborn screening tests; however, she was born with congenital glaucoma, which was controlled therapeutically. The child evolved with motor and speech delay, and some repetitive and restrictive behaviors. She presented learning disabilities and slurred speech (dysarthria), but she learned to read and write proficiently despite having difficulties to cope with abstract issues. Her physical examination at the age of 17 years revealed a body weight (BW) of 50 Kg (25th centile, -0.7SD), height (H) of 173 cm (95th centile, +1.6 SD), and marked microcephaly (OFC of 49 cm, <2nd centile, -4.9SD). Brain MRI was suggestive of microcephaly *vera*.

B-III-2 was born at term after an uneventful pregnancy. Newborn screening tests were normal. The boy evolved with important speech impairment (with dyslalia), despite speaking the first words at the age of 1 year; hyperactivity, repetitive and restrictive social behaviors were noted. He presented conspicuous dyspraxia, which interfered negatively with his learning and motor abilities; he also showed some difficulties in reading and counting. Given this constellation of signs and symptoms, a diagnostic of ASD was established. His physical examination at the age of 9 years revealed a weight of 23 kg (5th centile, -0.9 SD), a height of 131 cm (34th centile, -0.4 SD), and microcephaly (OFC of 48 cm, <2nd centile, -3.5 SD). Brain MRI did not reveal any alterations.

Both parents had learning disabilities and barely finished elementary school. The mother also presented microcephaly (OFC of 51cm, <2nd centile, -3.1SD), and speech impairment. A paternal uncle presented significant delay in his speech acquisition, being able to speak only at the age of 8 years.

In common, the mother and her two children presented microcephaly, learning disabilities, and speech impairment.

Molecular analyses

Genomic DNA was extracted from peripheral blood of the three siblings and their mother in Family A, and from the two siblings and their parents in Family B. The children tested negative for fragile X syndrome. Chromosome microarray analysis (CMA) for CNV investigation was performed using a 180 K platform (Agilent Technologies, California, USA), according to the manufacturer's recommendations. The analysis was conducted as described previously (20).

For whole-exome sequencing (WES), libraries were constructed using SureSelect Human All Exon V6 (Agilent Technologies, California, USA), and sequenced on an Illumina HiSeq platform. Sequence alignment to the reference genome hg19 was done through the BWA-MEM algorithm from the BWA program (21). SortSam and MarkDuplicates tools from PICARD (v.1.8, <http://broadinstitute.github.io/picard/>) were used to convert the SAM file into BAM and to mark the PCR duplicates, respectively. Also, we used the GATK 3.7 (22) to realign indels (Realigner TargetCreator and IndelRealigner), and to recalibrate the basis (BaseRecalibrator, BQSR), getting the BAM file to be used for variant calling. Variant calling and recalibration of SNPs and indels (VQSR) were performed using UnifiedGenotyper and VariantRecalibrator tools from GATK 3.7, respectively, to a set of 45 individuals. Multiallelic variants were split up into different lines, using the script `split_multiallelic_rows.rb` from Atlas2 (23), thus obtaining the final VCF files for analysis. Annotations of the VCF files were carried out through the VarSeq software (Golden Helix Inc, Montana, USA) and Varstation platform (<https://varstation.com/en/>), and candidate variants were filtered according to the following criteria: variant allele frequency ≥ 0.3 ; read depth ≥ 20 ; genotype

quality ≥ 17 ; population frequencies $\leq 1\%$ (1 K genomes, <https://www.internationalgenome.org/>; gnomAD, <https://gnomad.broadinstitute.org/>; and ABraOM (24), and effect missense or loss of function. Variant prioritization was performed through the web tool VarElect (<https://varelect.genecards.org/>), using the phenotypes "intellectual disability", "developmental delay", "hyperextensible joints" for individual A-II-3; "intellectual disability", "autism", "hyperextensible joints" for individual A-II-4; "microcephaly", "developmental delay", "learning disability", "glaucoma", "speech impairment" for individual B-III-1; and "speech delay", "microcephaly", "autism", "developmental delay" for individual B-III-2.

Results

Overlapping class I 17p13.3 microduplications were detected by CMA in affected individuals from two unrelated families. Genomic features of the duplicated 17p13.3 segments are depicted in Figure 2a.

In Family A, CMA was performed in the three affected half-brothers and an interstitial 17p13.3 microduplication encompassing 730 kb was disclosed only in individuals A-II-2 and A-II-3: arr[GRCh38] 17p13.3(1113701_1844036)x3, ISCN 2016 (Figure 2b). This microduplication was not detected in their mother, and FISH analysis excluded the possibility of a maternal balanced rearrangement (data not shown); fathers were unavailable for testing. WES was performed for the half-brothers A-II-3 and A-II-4. A-II-3 was found to carry 603 rare coding non-synonymous variants

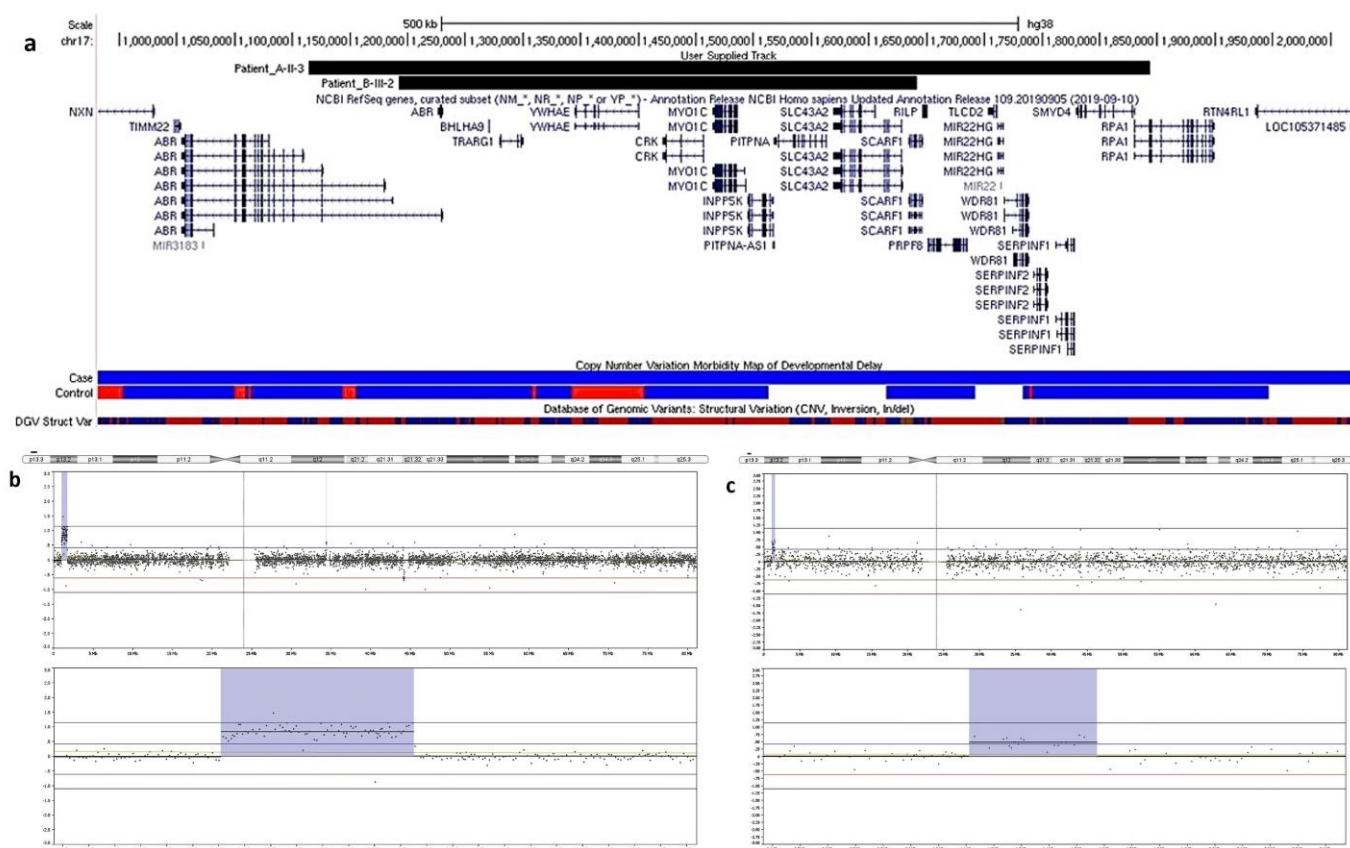


Fig. 2. 17p13.3 microduplications in Families A and B. (a) Genomic features of the duplicated 17p13.3 segment, according to CMA mapping for each individual represented in (b) and (c) - the curated isoforms of the affected genes (NCBI Ref Seq genes track) are shown as dark blue lines, in which the vertical bars denote exons (images derived from the UCSC Genome Browser, freeze October 2020); (b) CMA profile showing the microduplication at 17p13.3 in individual A-II-3 from Family A; (c) CMA profile showing the microduplication at 17p13.3 in individual B-III-2 from Family B.

Table 1. Rare coding non-synonymous variants detected in individuals A-II-3, B-III-1 and B-III-2.

	Gene	Genomic Coordinates (hg38)	ID	Inheritance	ACMG classification (2015)	Variant		Exon	Frequencies		
						HGVS c.	HGVS p.		1K Genomes	Gnom AD Exomes	ABra OM
A-II-3	<i>LDLR</i>	19:11129602	rs137853964 ClinVar: 375840	---	Pathogenic	NM_000527.5:c.2479G>A	p.Val827Ile	17	0.0004	0.001	Absent
B-III-1	<i>CYP11B1</i>	2:38071251	rs79204362 ClinVar: 7739	Mother	Pathogenic	NM_000104.3:c.1103G>A	NP_000095.2:p.Arg368His	3	0.004	0.006	Absent
B-III-2	<i>RORA</i>	15:60511244	rs771655652	Father	VUS	NM_134260.2:c.901G>A	NP_599022.1:p.Val301Met	6	Absent	Absent	Absent
B-III-1/ B-III-2	<i>DIP2B</i>	12:50718953	rs768972285	Father	Pathogenic	NM_173602.3:c.2962-2_2962-1delAG	N/A	Intron 24 (splicing)	Absent	Absent	Absent

(582 missense, three frameshift, 11 nonsense, three splicing, two stop-loss, and four initiator codon variants), while A-II-4 was found to carry 606 variants (578 missense, 13 frameshift, 10 nonsense, three splicing, one stop-loss, and one initiator codon variants). Pathogenic variants related to their phenotypes were not identified, including in the analysis of 1,809 genes related to intellectual disability/developmental disorders (DDD – Deciphering Developmental Disorders project) and 391 genes related to autism (SFARI Gene project). A pathogenic variant in the low density lipoprotein receptor gene (*LDLR*; OMIM *606945; NM_000527.5:c.2479G>A; p.Val827Ile; reported in ClinVar: 375840) was detected in A-II-3, being a secondary finding (Table 1). Rare variants were not observed in genes mapped to the microduplication segment. In family B, an interstitial 450 kb microduplication at 17p13.3 was detected in the proband B-III-1 and his sister B-III-2, inherited from their mother (B-II-1): arr [GRCh38] 17p13.3 (1192285_1641601) x3 mat, ISCN 2016 (Figure 2c).

WES for investigating rare variants was performed in the siblings and their mother. Excluding synonymous, the mother was found to carry 489 rare coding variants (455 missense, 12 frameshift, 13 nonsense, and eight splicing variants). Her daughter B-III-1 carried 467 variants

(433 missense, 19 frameshift, eight nonsense, and seven splicing variants). Her son B-III-2 had 522 rare variants (484 missense, 16 frameshift, 14 nonsense, seven splicing, and one stop-loss variant).

No rare variants were observed in genes mapped to the microduplication segment in the three affected individuals. However, three rare coding variants that could be related to the children's phenotypes were identified, all in heterozygous state (Table 1; classification followed the ACMG 2015 criteria) (25). A maternally inherited pathogenic variant in the cytochrome P450 family 1 subfamily B member 1 gene (*CYP11B1*; OMIM *601771; NM_000104.3:c.1103G>A; p.Arg368His; reported in ClinVar: 7739) was identified in B-III-1; no additional small intragenic deletions or duplications in *CYP11B1* were found in a follow-up analysis. A paternally inherited variant of uncertain significance (VUS) was observed in the RAR related orphan receptor A gene (*RORA*; OMIM *600825; NM_134260.2:c.901G>A; p.Val301Met) in B-III-2. In addition, a paternally inherited pathogenic variant (splice site mutation) was detected in both siblings in the disco interacting with protein 2 homolog B gene (*DIP2B*; OMIM *611379; NM_173602.3:c.2962-2_2962-1delAG).

Discussion

We described two unrelated families in which class I 17p13.3 microduplications segregated in association with variable phenotypes.

In Family A, only two of the three affected half-brothers, A-II-2 and A-II-3, both presenting similar phenotypes, were carriers of the 17p13.3 microduplication; the absence of the CNV in blood cells of their mother led to the hypothesis of mosaicism, with the microduplication being present at least in her germline, as it was inherited by two of her sons from unrelated fathers. However, since the fathers were not available for testing, the possibility of false paternity cannot be excluded. The clinical signs of these two half-brothers included delayed speech acquisition and moderate intellectual disability, traits commonly described in the literature in individuals carrying this type of microduplication (3, 4, 6). In A-II-2, perinatal events could have contributed to the severity of his phenotype; he also had recurrent inner ear infections, a feature reported in several patients carrying class I and class II 17p13.3 microduplications, although never recognized as a symptom of this syndrome (3, 6). Of note, the three half-brothers presented joint hypermobility, a feature reported in 17p13.3 microduplications (6); however, this is a quite unspecific sign and its presence in the patient who did not carry the microduplication suggests the interaction with other genes.

The exome analysis of A-II-3 and A-II-4 did not reveal any rare variant associated with their phenotypes, but a pathogenic mutation in the *LDLR* gene was found in A-II-3, constituting a secondary finding (26). *LDLR* is associated with autosomal dominant familial hypercholesterolemia (OMIM #143890 - hypercholesterolemia, familial, 1), and this particular variant was detected by Durst *et al.* (2017) in eight patients presenting modestly elevated low-density lipoprotein cholesterol (LDL-C) levels, thus being a relevant information in the genetic counseling process (27). Therefore, the

phenotype of the half-brothers A-II-2 and A-II-3 were probably mainly due to the presence of the 17p13.3 microduplication, although the possibility of an undetected pathogenic variant segregating in this family remains.

In Family B, the siblings inherited the class I 17p13.3 microduplication from their less affected mother, whose phenotypic manifestations were microcephaly, mildly impaired speech, and learning difficulties, which reinforce the variability of expression of this pathogenic CNV (5, 7, 10, 11). The boy B-III-2 exhibited autism with severe speech delay, very common traits in individuals with class I 17p13.3 microduplication (4), and microcephaly. His sister also had learning difficulties, impaired speech, and microcephaly, in addition to congenital glaucoma.

Although learning difficulty, autism, and speech impairment could be explained by the 17p13.3 microduplication (4, 6), features such as microcephaly and congenital glaucoma observed in Family B, as well as strabismus in individuals of Family A, were not previously related to this CNV. We performed an analysis of glaucoma-related genes in the girl, and found that she was heterozygous for a maternally inherited pathogenic missense variant in the *CYP11B1* gene, whose mutations are the most common cause of primary congenital glaucoma (OMIM #231300 - glaucoma 3, primary congenital, A), corresponding to about 50% of the cases identified in the Brazilian population (28). However, this pathogenic variant alone is not sufficient to explain her phenotype, as glaucoma due to *CYP11B1* mutations shows typically an autosomal recessive inheritance (29), and the other three *CYP11B1* variants in this patient were classified as benign (intronic or at the 3' and 5' UTRs). We also investigated *LTBP2*, *TEK*, and *MYOC*, three genes related to congenital glaucoma; *MYOC*, particularly, is suggested to play a role in the disease together with *CYP11B1*, characterizing a possible digenic inheritance of the phenotype (30).

However, the detected variants in *LTBP2*, *TEK*, and *MYOC* were predicted to be benign or VUS, being predominantly intronic, making it difficult to determine if one of them could be a contributing factor to her glaucoma. A possible explanation for this particular phenotype could be the CNV itself acting as a second-hit for the *CYP11B1* variant, considering that *CRK*, one of the genes encompassed by the 17q13.3 microduplication in Family B, has been already implicated in intraocular pressure, a susceptibility factor for glaucoma, in a genome-wide association study (31). Her mother also carries both variants, but she has not gone through ocular evaluation.

A VUS in the *RORA* gene was found in the boy B-III-2. The RORA protein is a transcriptional regulator whose levels *in vitro* are lower in the frontal cortex of normal males compared to age-matched females (32). Heterozygous mutations in this gene are a known cause of intellectual developmental disorder with or without epilepsy or cerebellar ataxia (OMIM #618060 - intellectual developmental disorder with or without epilepsy or cerebellar ataxia); interestingly, missense changes in the protein ligand-binding domain (exons 6 to 10), as detected here, were reported to lead to autistic features and mild intellectual disability with reduced penetrance, due to haploinsufficiency (33). These data are in accordance with our findings since patient B-III-2 carries a missense variant in exon 6 of *RORA* and presents ASD associated with speech delay. This variant was inherited from his father, who had learning disability, but no autistic features, and might be adding to the boy's phenotype, who also carries the 17p13.3 microduplication, as a second-hit (19), then supporting the role of *RORA* variants in neurodevelopmental disorders, and as a candidate gene for autism.

It is noteworthy that a rare splicing variant affecting the *DIP2B* gene was also detected in the siblings from Family B, inherited from their father.

A CGG-repeat expansion in *DIP2B*, associated with the fragile site FRA12A at chromosome 12q13.1, was described as the molecular basis of dominant intellectual disability (OMIM #136630 - mental retardation, FRA12A type; (34); the authors proposed that reduced expression of *DIP2B* in the brain due to CGG-repeat methylation could mediate the neurocognitive problems associated with the FRA12A, although with incomplete penetrance and variable expressivity. After this initial report, other patients with *DIP2B* mutations were not described; hence, *DIP2B* can be considered an intellectual disability candidate gene, deserving further investigation, and it is possible that different types of *DIP2B* loss-of-function mutations could lead to neurodevelopmental defects. Altogether, data point out that the splicing *DIP2B* variant identified in Family B probably contributed to the learning disability phenotype of their carriers, providing new evidence of its impact on neurodevelopment.

In Family B, both siblings and their mother have microcephaly, which is not a common feature of class I 17p13.3 microduplications, excepting those cases in which the *PAFAH1B1* gene is involved (2, 4-6, 8). Although the mother had toxoplasmosis during B-III-1 pregnancy, none of the children presented any of the classic signs of severe congenital toxoplasmosis, such as chorioretinitis, intracranial calcifications, and hydrocephalus (35). Microcephaly is a common feature in Miller-Dieker syndrome, which necessarily involves the deletion of the *PAFAH1B1* and *YWHAE* genes, among others present in the so-called MDS telomeric critical region, such as *CRK* and *MYO1C* (1). The patient reported by Ho et al. (2012) and the siblings herein reported are the only ones to have microcephaly without *PAFAH1B1* being duplicated (2-5). It is known that aberrant neuronal migration accounts for a substantial proportion of cases of congenital microcephaly and intellectual disability (36, 37). Functional evidence demonstrates a wide expression of *YWHAE* in the

brain, playing an important role in neuronal signaling, as well as in the differentiation of neuronal progenitor cells, which is consistent with the pathophysiology of microcephaly (11, 36). Therefore, it is possible that microcephaly, although rare, could also be a clinical sign of the class I 17p13.3 microduplication, encompassing only the *YWHAE* gene.

In conclusion, we detected additional pathogenic variants in the carriers of class I 17p13.3 microduplication associated with their phenotypes in one of the two studied families. Rare variants were disclosed in genes related to autism, congenital glaucoma, and intellectual disability; in particular, we provided new evidence regarding the contribution of *RORA* and *DIP2B* to neurocognitive deficits such as autism and intellectual disability, respectively. These results showed that additional genetic investigation in 17p13.3 microduplication carriers can lead to the identification of modifier variants of the expressivity of this pathogenic CNV. Finally, we suggest that microcephaly is a rare clinical feature related to the presence of the class I 17p13.3 microduplication.

Accession Numbers

The 17p13.3 microduplications and *LDLR*, *CYP11B1*, *RORA*, and *DIP2B* genomic variants have been submitted to ClinVar under IDs SCV001251972, SCV001251973, SCV001438313, SCV001251969, SCV001251970, and SCV001438312, respectively.

Acknowledgements

The authors would like to thank the patients and their families and the funding agencies CEPID/FAPESP (grant number 2013/080828-1) and CNPq (grant numbers 157816/2018-4, 140271/2020-1) for supporting this work.

Conflict of interest

The authors have no conflict of interest to declare.

References

- Cardoso C, Leventer RJ, Ward HL, et al. Refinement of a 400-kb critical region allows genotypic differentiation between isolated lissencephaly, Miller-Dieker syndrome, and other phenotypes secondary to deletions of 17p13.3. *Am J Hum Genet* 2003;72:918-30.
- Bi W, Sapir T, Shchelochkov OA, et al. Increased *LIS1* expression affects human and mouse brain development. *Nat Genet* 2009;41:168-77.
- Roos L, Jonch AE, Kjaergaard S, et al. A new microduplication syndrome encompassing the region of the Miller-Dieker (17p13 deletion) syndrome. *J Med Genet* 2009;46:703-10.
- Bruno DL, Anderlid BM, Lindstrand A, et al. Further molecular and clinical delineation of co-locating 17p13.3 microdeletions and microduplications that show distinctive phenotypes. *J Med Genet* 2010;47:299-311.
- Ho AC, Liu AP, Lun KS, et al. A newborn with a 790 kb chromosome 17p13.3 microduplication presenting with aortic stenosis, microcephaly and dysmorphic facial features - is cardiac assessment necessary for all patients with 17p13.3 microduplication? *Eur J Med Genet* 2012;55:758-62.
- Curry CJ, Rosenfeld JA, Grant E, et al. The duplication 17p13.3 phenotype: analysis of 21 families delineates developmental, behavioral and brain abnormalities, and rare variant phenotypes. *Am J Med Genet A* 2013;161A:1833-52.
- Henry RK, Astbury C, Stratakis CA, et al. 17p13.3 microduplication including *CRK* leads to overgrowth and elevated growth factors: A case report. *Eur J Med Genet* 2016;59:512-6.
- Farris N, Wu H, Said-Delgado S, et al. 17p13.3 quadruplication: a prenatal and postpartum clinical characterization of a copy number variant. *Cold Spring Harb Mol Case Stud* 2018;4.
- Blazejewski SM, Bennison SA, Smith TH, et al. Neurodevelopmental Genetic Diseases Associated With Microdeletions and Microduplications of Chromosome 17p13.3. *Front Genet* 2018;9:80.
- Hyon C, Marlin S, Chantot-Bastaraud S, et al. A new 17p13.3 microduplication including the *PAFAH1B1* and *YWHAE* genes resulting from an unbalanced X;17 translocation. *Eur J Med Genet* 2011;54:287-91.
- Noor A, Bogatan S, Watkins N, et al. Disruption of *YWHAE*

gene at 17p13.3 causes learning disabilities and brain abnormalities. *Clin Genet* 2018;93:365-7.

12. Girirajan S, Rosenfeld JA, Coe BP, et al. Phenotypic heterogeneity of genomic disorders and rare copy-number variants. *N Engl J Med* 2012;367:1321-31.

13. Rosenfeld JA, Coe BP, Eichler EE, et al. Estimates of penetrance for recurrent pathogenic copy-number variations. *Genet Med* 2013;15:478-81.

14. Nevado J, Mergener R, Palomares-Bralo M, et al. New microdeletion and microduplication syndromes: A comprehensive review. *Genet Mol Biol* 2014;37:210-9.

15. Watson CT, Marques-Bonet T, Sharp AJ, et al. The genetics of microdeletion and microduplication syndromes: an update. *Annu Rev Genomics Hum Genet* 2014;15:215-44.

16. Capra V, Mirabelli-Badenier M, Stagnaro M, et al. Identification of a rare 17p13.3 duplication including the BHLHA9 and YWHA6 genes in a family with developmental delay and behavioural problems. *BMC Med Genet* 2012;13:93.

17. Kiiski K, Roovere T, Zordania R, et al. Prenatal diagnosis of 17p13.1p13.3 duplication. *Case Rep Med* 2012;2012:840538.

18. Shen Y, Si N, Liu Z, et al. 17p13.3 genomic rearrangement in a Chinese family with split-hand/foot malformation with long bone deficiency: report of a complicated duplication with marked variation in phenotype. *Orphanet J Rare Dis* 2018;13:106.

19. Girirajan S, Rosenfeld JA, Cooper GM, et al. A recurrent 16p12.1 microdeletion supports a two-hit model for severe developmental delay. *Nat Genet* 2010;42:203-9.

20. Oliveira D, Leal GF, Sertie AL, et al. 10q23.31 microduplication encompassing PTEN decreases mTOR signalling activity and is associated with autosomal dominant primary microcephaly. *J Med Genet* 2019;56:543-7.

21. Aligning sequence reads, clone sequences and assembly contigs with BWA-MEM [database on the Internet]2013. Available from: <https://arxiv.org/abs/1303.3997>.

22. McKenna A, Hanna M, Banks E, et al. The Genome Analysis Toolkit: a MapReduce framework for analyzing next-generation DNA sequencing data. *Genome Res* 2010;20:1297-303.

23. Challis D, Yu J, Evani US, et al. An integrative variant analysis suite for whole exome next-generation sequencing data. *BMC Bioinformatics* 2012;13:8.

24. Naslavsky MS, Yamamoto GL, de Almeida TF, et al. Exomic variants of an elderly cohort of Brazilians in the ABraOM database. *Hum Mutat* 2017;38:751-63.

25. Richards S, Aziz N, Bale S, et al. Standards and guidelines for the interpretation of sequence variants: a joint consensus recommendation of the American College of Medical Genetics and Genomics and the Association for Molecular Pathology. *Genet Med* 2015;17:405-24.

26. Kalia SS, Adelman K, Bale SJ, et al. Recommendations for reporting of secondary findings in clinical exome and genome sequencing, 2016 update (ACMG SF v2. 0): a policy statement of the American College of Medical Genetics and Genomics. *Genet Med* 2017;19:249-55.

27. Durst R, Ibe UK, Shpitzen S, et al. Molecular genetics of familial hypercholesterolemia in Israel-revisited. *Atherosclerosis* 2017;257:55-63.

28. Qashqai M, Suri F, Yaseri M, et al. P.Gly61Glu and P.Arg368His Mutations in CYP1B1 that Cause Congenital Glaucoma may be Relatively Frequent in Certain Regions of Gilan Province, Iran. *J Ophthalmic Vis Res* 2018;13:403-10.

29. Reis LM, Tyler RC, Weh E, et al. Analysis of CYP1B1 in pediatric and adult glaucoma and other ocular phenotypes. *Mol Vis* 2016;22:1229-38.

30. Kaur K, Reddy AB, Mukhopadhyay A, et al. Myocilin gene implicated in primary congenital glaucoma. *Clin Genet* 2005;67:335-40.

31. Huang L, Chen Y, Lin Y, et al. Genome-wide analysis identified 17 new loci influencing intraocular pressure in Chinese population. *Sci China Life Sci* 2019;62:153-64.

32. Sayad A, Noroozi R, Omrani MD, et al. Retinoic acid-related orphan receptor alpha (RORA) variants are associated with autism spectrum disorder. *Metab Brain Dis* 2017;32:1595-601.

33. Guissart C, Latypova X, Rollier P, et al. Dual Molecular Effects of Dominant RORA Mutations Cause Two Variants of Syndromic Intellectual Disability with Either Autism or Cerebellar Ataxia. *Am J Hum Genet* 2018;102:744-59.

34. Winnepeninckx B, Debacker K, Ramsay J, et al. CGG-repeat expansion in the DIP2B gene is associated with the fragile site FRA12A on chromosome 12q13.1. *Am J Hum Genet* 2007;80:221-31.

35. McAuley JB. Congenital Toxoplasmosis. *J Pediatric Infect Dis Soc* 2014;3 Suppl 1:S30-5.

36. Gilmore EC, Walsh CA. Genetic causes of microcephaly and lessons for neuronal development. *Wiley Interdiscip Rev Dev Biol* 2013;2:461-78.

37. Alcantara D, O'Driscoll M. Congenital microcephaly. *Am J Med Genet C Semin Med Genet* 2014;166C:124-39.