

Effect of *Urtica dioica* Leaf Alcoholic and Aqueous Extracts on the Number and the Diameter of the Islets in Diabetic Rats

Durdi Qujeq^{1,2*}, Mohsen Tatar², Farideh Feizi³, Hadi Parsian^{1,2}, Alieh Sohan Faraji³, Sohrab Halalkhor²

1. Cellular and Molecular Biology Research Center (CMBRC), Babol University of Medical Sciences, Babol, Iran.

2. Department of Biochemistry and Biophysics, Faculty of Medicine, Babol University of Medical Sciences, Babol, Iran.

3. Department of Anatomical Sciences, Faculty of Medicine, Babol University of Medical Sciences, Babol, Iran.

Submitted 28 January 2013; Accepted 3 March 2013

Urtica dioica has been known as a plant that decreases blood glucose. Despite the importance of this plant in herbal medicine, relatively little research has been done on effects of this plant on islets yet. The objective of the current study was to evaluate the effect of dried *Urtica dioica* leaf alcoholic and aqueous extracts on the number and the diameter of the islets and histological parameters in streptozotocin-induced diabetic rats. Six rats were used in each group. Group I: Normal rats were administered saline daily for 8 weeks. Group II: Diabetic rats were administered streptozotocin, 50 mg/kg of body weight; Group III: Diabetic rats were administered dried *Urtica dioica* leaf aqueous extracts for 8 weeks; Group IV: Diabetic rats were administered dried *Urtica dioica* leaf alcoholic extracts for 8 weeks. The animals, groups of diabetic and normal, were sacrificed by ether anaesthesia. Whole pancreas was dissected. The tissue samples were formalin fixed and paraffin embedded for microscopic examination. Histologic examination and grading were carried out on hematoxylin-eosin stained sections. The effects of administration of dried *Urtica dioica* leaf alcoholic and aqueous extracts to diabetic rats were determined by histopathologic examination. The pancreas from control rats showed normal pancreatic islets histoarchitecture. Our results also, indicate that the pancreas from diabetic rats show injury of pancreas tissue while the pancreas from diabetic rats treated with dried *Urtica dioica* leaf alcoholic and aqueous extracts show slight to moderate rearrangement of islets. According to our findings, dried *Urtica dioica* leaf alcoholic and aqueous extracts can cause a suitable repair of pancreatic tissue in streptozotocin-induced diabetic experimental model.

Key words: Diabetes, pancreas, *Urtica dioica*, rat, alcoholic and aqueous extract

Urtica dioica has been known as a medicinal plant in the world (1). It is known for its use against diabetes in folk medicine (2). Several experimental studies have investigated the role of

Urtica dioica (UD) as a hypoglycemic agent (3-7). It has been widely used in traditional natural treatments for diabetes (1, 5) and based on these data has been applied to medical use for many years

* Cellular and Molecular Biology Research Center (CMBRC), Babol University of Medical Sciences, Ganjafrooz Avenue, Babol, Iran.
Email: d.qujeq@mubabol.ac.ir, dqujeq@hotmail.com

in the treatment of diabetic diseases (6). UD is also known for its use against diabetes in folk medicine (7-9). As reported by many other investigators *U. dioica* is a plant belonging to the plant family Urticaceae. The blood sugar lowering effect of *U. dioica* as a medicinal plant has been reported (10).

U. dioica leaves extract given parenterally possesses a hypoglycemic effect in alloxan hyperglycemic rats (11). *Urtica dioica* extract had hypoglycemic and antidiabetic activities (12). The extract of UD was unable to enhance the glucose utilization directly (13).

In view of the above mentioned varied unique pharmaceutical and biological application of dried *Urtica dioica* leaf extracts, it may be pragmatic to say that this plant have the potential to be used as active compound in diabetes. The objective of the current study was to evaluate the effect of dried *Urtica dioica* leaf alcoholic and aqueous extracts on the number and the diameter of the islets and histological parameters in streptozocin-induced diabetic rats.

Materials and Methods

Preparation of *Urtica dioica* leaves

Urtica dioica leaves were purchased from herbalists in Babol, Iran. The leaves were separated and dried at room temperature while keeping away from direct sunlight and then were grounded into powder.

Preparation of the aqueous and alcoholic powder of *Urtica dioica* leaf extracts

In order to prepare the aqueous concentrate, 200 g of room temperature dried *Urtica dioica* leaves were infused in two litres of distilled water and were heated at 80 °C (Behdad–water bath) for 30 minutes with occasional stirrings. The extract of *Urtica dioica* leaves was filtered. The non soluble part was then separated using a mesh and the solution was passed two times through Whatman paper No. 2, and the aqueous part was evaporated on a rotator evaporator (K-1Karwerke, GMBH SCo

KG, Germany, TYP: RVo6-ML, 010388949) at 75°C to reduce the solution volume to 1/5 of the initial value. For the preparation of ethanolic solution, 200 g of dried leaves was dissolved in one litre of 96% ethanol and mixed by a shaker (Labtron–Ls-100) for 24 hrs at room temperature. Again the non soluble part was separated using a mesh and the solution was passed two times through Whatman paper No. 2. The macerate was filtered, and ethanol was evaporated on a rotator evaporator at 60°C under the vacuum to reduce the solution volume to 1/5 of the initial value. The powder of *Urtica dioica* leaves was percolated by aqueous (60°) solvent for 24 hrs. The extract was filtered and concentrated under vacuum at 60°C. Chromatography and purity tests for qualification analysis were carried out. Both aqueous and ethanolic solutions were kept four days under hood to let the solvents evaporate. Finally, the extract was stored at -20 °C until its use within 1 week.

Isolation and purification of powder of *Urtica dioica* leaf extracts by chromatography

1 ml of crude extract was loaded onto a sephadex G-20 packed column and the column was washed with 10 mM Tris-HCl, pH 7.2. Fractions with different optical densities were collected. All fractions were stored at -20°C. The fraction 2 was the most effective at increasing glucose uptake *in vitro* as well as *in vivo* in hyperglycemic rats.

Animals

Male adult rats of 200-250 g were fed on pellet diet and tap water for full acclimatization. The rats were divided into four groups (each group including 6 rats). Rats of closed colony were prepared from the animal center of Babol University of Medical Sciences, Babol, IRAN. Age-matched rats were used as control animals. The rats were housed in suspended bracket cages in a climate-controlled room at 22±5 °C with 12L:12D lighting cycle. Feed and water were provided *ad libitum*. All procedures were in accordance with animal experimental guidelines of Babol University

of Medical Sciences. The approval of the Ethics Committee of Babol University was also obtained (# 3546, 1390/2/7; 1815, 1389/7/6).

Diabetic induction

Diabetes was induced by intraperitoneal injection (50 mg/kg, i.p) of 0.6 ml of freshly prepared solution of streptozotocin (STZ) dissolved in distilled cold normal saline. Rats were not fed 14 hrs before injection. In addition, 0.7 ml normal saline was injected to rats in the control groups. Rats with fasting glycemia more than 250 mg/dl were used as diabetic. Blood samples for glucose measurements were taken from the tail vein. Diabetes was confirmed by measuring the glucose concentration.

Animals administration

Animals were randomly divided into four groups. Six rats were used in each group: (I) the normal group, normal saline daily administered for 7 days. (II) the diabetic group, animals that received 50 mg/kg streptozotocin intraperitoneally and did not receive any extract. (III) the treatment group, diabetic induced by one dose of intraperitoneally injection of 50 mg STZ which then received 15 mg/kg daily aqueous extract of *Urtica dioica* leaf, for 56 days. (IV) the hyperglycemic animals that received 50 mg/kg streptozotocin intraperitoneally and treated with ethanolic extract. Before experiments and after 72 hrs, while rats were not fed for 14 hrs, their blood samples were obtained from tail vein. Glucose and insulin of blood serum were measured. Then, 24 hrs after obtaining blood samples rats were treated orally with 10 mg/kg/day *Urtica dioica* leaf extracts or distilled water (as the control) for 56 days. Upon completion of this period, the blood samples were obtained again to measure the glucose and insulin levels.

Histological tests

Eight weeks from the start of the experiment, all animals in the four groups were sacrificed by ether anesthesia. Whole pancreas was

dissected. The tissue samples were fixed in formalin %10 and paraffin embedded for microscopic examination in accordance with routine laboratory procedures. Histopathology examination and grading were carried out on haematoxylin and eosin stained sections at 5- μ m thickness (Leitz 1512, Germany). The size and cellularity of islets were evaluated by olympus BX41 light microscope and motic image plus 2.0 ML.

Statistical analysis

All values have been presented as mean \pm standard error. All tests were carried out in triplicate. Statistical analysis were done using SPSS version 16.0. The significance of differences between the mean values were determined by analysis of variance (ANOVA) or was determined using an unpaired two-tailed Student's t-test, and a *p* value of less than 0.05 was considered statistically significant.

Results

Effect of dried *Urtica dioica* leaf alcoholic and aqueous extracts on number of islets and islets diameter in normal and diabetic rats was shown in Table 1. Our results indicate that administration of streptozotocin intraperitoneally reduce the cellularity and diameter of islets compared to the control group. Administration of dried *Urtica dioica* leaf ethanolic extracts significantly increased the cellularity and diameter of islets in treated group compared to diabetic group. Also, the diameter and cellularity of islets in rats treated with *Urtica dioica* leaf aqueous extracts significantly increased. There were no abnormalities in the pancreas of normal rats (Fig.1). Diabetic rats showed injury of pancreas tissue (Fig.2). The Diabetic rats treated with ethanolic *Urtica dioica* leaf extracts showed moderate repair of pancreatic tissue (Fig.3). Diabetic rats treated with aqueous *Urtica dioica* leaf extracts also showed slight to moderate repair of pancreatic tissue, probably due to partial regeneration of the pancreatic cells (Fig.4).

Table 1. Comparison of the effect of *Urtica dioica* leaf extracts on the islets diameter in normal and diabetic rats.

| Group treatment | Islets diameter(μm) |
|---|---------------------|
| Normal | 34.94± 24.60 |
| Diabetic | 13.20±7.35 |
| Diabetic + <i>aqueous Urtica dioica</i> leaf extracts | 25.58±12.18 |
| Diabetic + <i>alcoholic Urtica dioica</i> leaf extracts | 26.37±14.67 |

All data have been presented as mean ± standard error, P<0.05.

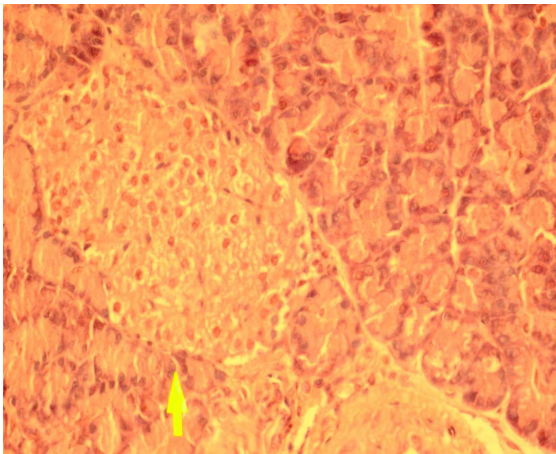


Fig 1. The pancreas from control rat (haematoxylin and eosin, original magnification ×40).

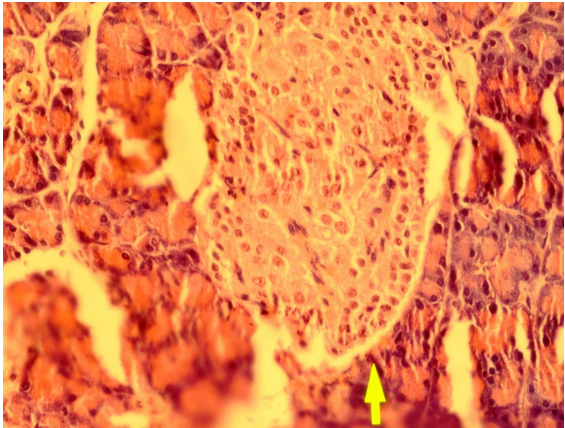


Fig 3. The pancreas from a diabetic rat treated with ethanol extract of *Urtica dioica* leaf extracts (haematoxylin and eosin, original magnification ×40).

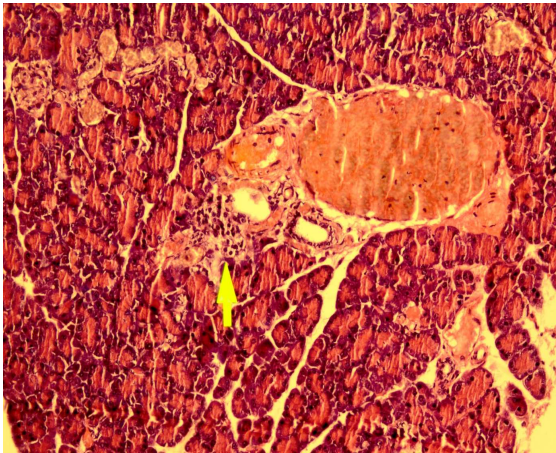


Fig 2. The pancreas from diabetic (haematoxylin and eosin, original magnification ×40).

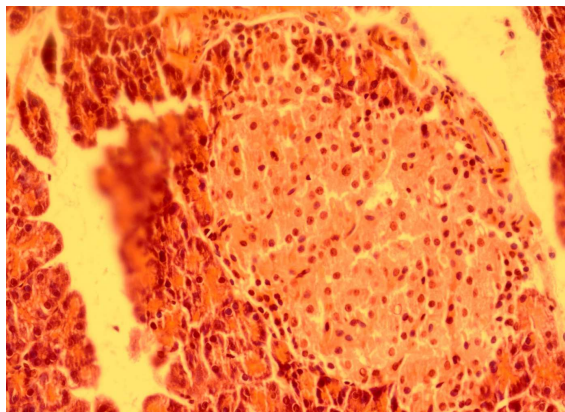


Fig 4. The pancreas from a diabetic rat treated with aqueous extract of *Urtica dioica* leaf extracts (haematoxylin and eosin, original magnification ×40).

Discussion

Histopathological aspects of pancreatic structure in diabetic models have received less attention. In the present study, we assessed the

pancreatic changes at light microscopy level and studied the effect of dried *Urtica dioica* leaf alcoholic and aqueous extracts on the pancreas of diabetic rats. According to our findings, dried

Urtica dioica leaf alcoholic and aqueous extracts may have been a protective effect or repairative effect on islets of pancreas tissue in experimental model. The cellularity and diameter of islets were decreased after streptozocin treatment. This study showed that the administration of dried *Urtica dioica* leaf extracts after induction of diabetes in rats protects the islets so diameter and cellularity of islets were not diminished or may be replaced by duplication of remained cells or pancreatic ducts. (4). These data confirm earlier studies (5, 6).

Moreover; investigators showed that *Urtica dioica* was a potent stimulator of insulin release of β -cells (6). Also others reported that *Urtica dioica* has hypoglycemic activity and β -cell regenerative potency (14). But, our observations are not in agreement with the results obtained by other investigators (15) who did not observe a hypoglycemia activity of aqueous extract of the powder of *Urtica dioica* leaf extracts. In this study, in treatment group the dried *Urtica dioica* leaf extracts can cause repair activity after eight weeks of administration in streptozotocin diabetic rats. Therefore, administration of dried *Urtica dioica* leaf extracts after inducing diabetes in rats could prevent the pancreas damage. The exact mechanism of the pancreatic changes due to dried *Urtica dioica* leaf extracts in animal diabetic models is not clear, but there are several possible mechanisms of these alterations in the pancreatic cells. These changes may be influenced by components present in the dried *Urtica dioica* leaf extracts. Based on the beneficial effects of plant materials in improving tissue regeneration, we hypothesized that effect of dried *Urtica dioica* leaf extracts may promote the pancreatic ability to normal function.

The improved function of pancreas after treatment could be attributed to this beneficial dried *Urtica dioica* leaf extracts effect. An accelerated recovery and improved function after pancreatic injury could be attributed to the promotion of endogenous repair pathway. Therefore, in future it

will be important to examine the effect of dried *Urtica dioica* leaf extracts in diabetic experimental model.

Acknowledgments

We express our gratitude to the staff of Departments of Biochemistry and Anatomical Sciences, Babol University of Medical Sciences for their assistance in blood and pancreas tissue samples collection. This investigation was a collaborative work of the Cellular and Molecular Biology Research Center and the Faculty of Medicine. This study was supported by grants # 8930336, 1390/2/21 and # 8929121 from the Research Council of Babol University of Medical Sciences. Also, we thank Mr. Shikhzadeh for his excellent technical assistance.

References

1. Gunther RT, Goodyer J. The Greek Herbal of Dioscorides. NewYork: Hafner Publishing; 1959.
2. Grieve M. A Modern Herbal. England: Penguin; 1980.
3. Newall CA, Anderson LA, hillipson JD. Herbal medicines: a guide for health-care professionals. London: The pharmaceutical press; 1996.
4. O'Neill KE, Eberhard D, Tosh D. Origin of beta-cells in regenerating pancreas. Bioessays 2008;30:617-20.
5. El HM, Bnouham M, Bendahou M, et al. Inhibition of rat platelet aggregation by *Urtica dioica* leaves extracts. Phytother Res 2006;20:568-72.
6. Kavalali G, Tuncel H, Goksel S, et al. Hypoglycemic activity of *Urtica pilulifera* in streptozotocin-diabetic rats. J Ethnopharmacol 2003;84:241-5.
7. Petlevski R, Hadzija M, Slijepcevic M, et al. Glutathione S-transferases and malondialdehyde in the liver of NOD mice on short-term treatment with plant mixture extract P-9801091. Phytother Res 2003;17:311-4.
8. Burrowes JD, Van Houten G. Herbs and dietary supplement use in patients with stage 5 chronic kidney disease. Nephrol Nurs J 2006;33:85-8.
9. Grover JK, Vats V, Rath SS, et al. Traditional Indian anti-diabetic plants attenuate progression of renal damage in streptozotocin induced diabetic mice. Journal of Ethno-

pharmacology 2001;76:233-8.

10. Golalipour M.J. G, Ghafari S, Kouri V, et al. Proliferation of the β -Cells of Pancreas in Diabetic Rats Treated with *Urtica dioica*. Int J Morphol 2010;28:399-404.

11. Qujeq D, Davary S, Moazzi Z, et al. Effect of *Urtica dioica* leaf extract on activities of nucleoside diphosphate kinase and acetyl coenzyme, a carboxylase, in normal and hyperglycemic rats. Afr J Pharm Pharmacol 2011;5:792-6.

12. Ahangarpour A, Mohammadian M, Dianat M. Antidiabetic effect of hydroalcoholic *Urtica dioica* leaf extract in male rats with fructose-induced insulin resistance. Iran J Med Sci 2012;37:181-6.

13. Mobaseri M, Aliasgarzadeh A, Bahrami A, et al. Efficacy of the Total Extract of *Urtica dioica* on the glucose utilization by the Human Muscle Cells. J Clin Diagn Res 2012;6:437-40.

14. Farzami B, Ahmadvand D, Vardasbi S, et al. Induction of insulin secretion by a component of *Urtica dioica* leave extract in perfused Islets of Langerhans and its in vivo effects in normal and streptozotocin diabetic rats. J Ethnopharmacol 2003;89:47-53.

15. Roman Ramos R, Alarcon Aguilar F, Lara Lemus A, et al. Hypoglycemic effect of plants used in Mexico as antidiabetics. Arch Med Res 1992;23:5.64-9.