Babol University Of Medical Sciences

IJMCM, Spring 2026, VOL 15, NO 2

International Journal of Molecular and Cellular Medicine

Journal homepage: www.ijmcmed.org

CASE REPORT

Longitudinal Functional and Safety Outcomes in Chronic Post-Ischemic Stroke Following a Multimodal Regenerative Medicine Protocol: A Case Report

Daryl Joel Dumdum[1,2*], Andrea Jhen Dela Casa-Dumdum[3], Marthew Alneo Molina[3]

1. SH360 Stem Cell Research Institute, Davao City, Philippines
2. Sure Health 360 Center for Regenerative Medicine and Cell Therapy, Lanang Premiere Doctors Hospital, Davao City, Philippines
3. SH360 Medical Corporation, Davao City, Philippines

ARTICLE INFO

Received: 2026/08/24
Revised: 2026/09/15
Accepted: 2026/09/22

ABSTRACT

Chronic neurological deficits frequently persist after ischemic stroke despite advances in acute treatment, secondary prevention, and rehabilitation. Mesenchymal stromal cell (MSC)-based regenerative approaches and their secreted factors, including extracellular vesicles such as exosomes, have emerged as potential adjuncts to promote neuroplasticity and functional recovery, although clinical evidence remains limited. A 73-year-old man with chronic post-ischemic stroke underwent an individualized multimodal regenerative protocol integrated with standard medical care and rehabilitation. The treatment primarily involved intravenous allogeneic umbilical cord-derived mesenchymal stromal cell (MSC) therapy followed by maintenance MSC-derived secretome therapy, with other supportive interventions, and follow-up over six months. Clinical outcomes were assessed using the National Institutes of Health Stroke Scale (NIHSS), Modified Rankin Scale (mRS), Modified Ashworth Scale (MAS), Barthel Index, Six-Minute Walk Test (6MWT), Energy Visual Analog Scale (VAS), neurological examination, and patient-reported outcomes. Muscle spasticity improved (MAS 3 to 1), walking endurance increased (6MWT 220–360 m), and Energy VAS improved (3/10 to 8/10). Grip strength, right upper-limb sensation, balance, and gait stability improved, while independence in daily activities was maintained. NIHSS and mRS scores remained unchanged. During follow-up, the patient experienced transient hypotension and a recurrent ischemic stroke; based on the available clinical information, a definitive causal relationship with the regenerative interventions could not be established. No serious adverse event was definitively attributed to the regenerative interventions based on the available clinical assessment. This case demonstrates the feasibility of integrating UC-MSC and MSC-derived secretome-based regenerative therapy into chronic stroke rehabilitation. Although functional improvements were documented, causal conclusions cannot be drawn from a single case. Prospective controlled studies are needed to establish safety and clinical effectiveness.

Keywords: Ischemic stroke; Mesenchymal stromal cells; MSC-derived secretome; Extracellular vesicles; Exosomes; Neurorehabilitation.

***Corresponding**:
Daryl Joel Dumdum
Address:
SH360 Stem Cell Research Institute.
Sure Health 360 Center for Regenerative Medicine and Cell Therapy.
Lanang Premiere Doctors Hospital, J.P. Laurel Avenue, Lanang, Davao City 8000, Philippines.
E-mail:
info@surehealth360.com

Cite this article: Dumdum D, et al. Longitudinal Functional and Safety Outcomes in Chronic Post-Ischemic Stroke Following a Multimodal Regenerative Medicine Protocol: A Case Report. International Journal of Molecular and Cellular Medicine. 2026; 15(2):1493-1509. DOI: 10.22088/IJMCM.BUMS.15.2.1493

© The Author(s).
Publisher: Babol University of Medical Sciences
This work is published as an open access article distributed under the terms of the Creative Commons Attribution 4.0 License (http://creativecommons.org/licenses/by-nc/4). Non-commercial uses of the work are permitted, provided the original work is properly cited.

[Downloaded from ijmcmed.org on 2026-11-23]

[DOI: 10.22088/IJMCM.BUMS.15.2.1493]

Stroke remains one of the leading causes of death and long-term disability worldwide, with ischemic stroke accounting for approximately 85% of all cerebrovascular events. In accordance with the Global Burden of Disease Study 2021, the stroke continues to be a health burden around the world, with an increase in its prevalence in aging individuals and disability despite advancements in its prevention and acute treatment. Stroke survivors suffer from various long-term motor, sensory, cognitive, and functional impairment that affects their quality of life and brings great socioeconomic burdens to patients, caregivers, and health care systems across the globe (1). The current management approach for ischemic stroke includes prompt reperfusion, secondary prevention, and multidisciplinary rehabilitation. Despite the advancements in acute stroke care that help in improving mortality rates, the process of neurorehabilitation reaches a plateau in the chronic stage of stroke and leaves many patients suffering from various disabilities, despite the length of rehabilitation period. Thus, the need for novel treatment approaches to improve neuroplasticity, affect the post-stroke microenvironment and help in endogenous repair appears urgent (2-7).

One of the most promising regenerative approaches includes mesenchymal stromal cells (MSCs). The reason behind the use of such cells is that they have many beneficial characteristics, including immunomodulatory and anti-inflammatory effects, pro-angiogenesis and neurotrophic capabilities. Present research shows that these cells affect tissue regeneration via paracrine signaling pathways, rather than direct cell replacement, and their effect includes inflammation modulation, angiogenesis induction, and endogenous neuroregeneration. According to recent trials and systematic reviews, intravenous application of MSCs appears to be feasible and safe, with positive signals related to functional outcomes. Nevertheless, there is a great deal of heterogeneity in such parameters as cell origin, production process, dose, route of administration, timing, and patient population (3-8). Equally, interest has been raised towards cell-free strategies for regeneration, including extracellular vesicles and secretomes of MSCs. The biological products comprise cytokines, chemokines, growth factors, messenger RNA, microRNA, lipids, and various other signaling molecules, which are thought to be involved in mediating the paracrine actions of MSCs. Extracellular vesicles, including exosomes, may represent one component of MSC paracrine signaling and can transport bioactive molecules between cells. Various experimental and translational studies have shown that MSC-derived secreted factors and extracellular vesicles can help modulate neuroinflammation, induce angiogenesis, maintain blood-brain barrier integrity, and induce neuroplasticity after cerebral ischemia. However, the scientific evidence base is still mainly preclinical, and no robust clinical evidence proving their efficacy in patients of ischemic stroke has been obtained yet (9-12).While MSC therapy and MSC-derived secretome, which may contain extracellular vesicles, have attracted increasing interest in ischemic stroke, longitudinal clinical observations describing their use in chronic post-ischemic stroke remain limited. Other supportive regenerative approaches have also been explored; however, the cellular and paracrine mechanisms associated with MSCs and their secreted products are of particular interest for promoting post-stroke repair and neuroplasticity.

This case report describes the six-month clinical course of a patient with chronic post-ischemic stroke who underwent an individualized multimodal regenerative medicine protocol integrated with standard medical management and rehabilitation, with particular emphasis on intravenous allogeneic umbilical cord-derived MSC therapy and subsequent MSC-derived secretome therapy. The objective of this report is to describe the clinical course, longitudinal functional outcomes, and safety observations associated with this multimodal approach, without attributing the observed changes to any individual intervention, while contributing hypothesis-generating clinical evidence regarding MSC- and secretome-based regenerative approaches for chronic ischemic stroke.

Case Presentation

Patient Information

A 73-year-old Caucasian male patient sought consultation at the Sure Health 360 Center for Regenerative Medicine and Cell Therapy, Davao City, Philippines, for evaluation of an adjunctive regenerative approach because of persistent neurological deficits following a previous ischemic stroke. Despite prior conventional medical management and rehabilitation, he continued to

[Downloaded from ijmcmed.org on 2026-11-23]

[DOI: 10.22088/IJMCM.BUMS.15.2.1493]

experience residual neurological impairment and sought additional treatment options that might support further functional improvement.

His chief complaints were weakness in his right upper extremity with diminished sensory and fine motor abilities, an unsteady gait, poor balance, fatigue, and reduced exercise tolerance. He was still able to do his activities of daily living independently, but these problems made him functionally impaired and insecure while walking.

Clinical History

The patient developed an ischemic stroke in 2024. After undergoing appropriate treatment of his stroke, he underwent multidisciplinary rehabilitation. Though there was partial recovery from his stroke, the improvement of his function stopped in the chronic stage, with residual motor and sensory impairment on the right upper limb along with problems related to balance and gait, and decreased endurance. The patient had a history of coronary artery disease with a prior myocardial infarction that occurred nearly two decades ago, which had resulted in him developing chronic heart failure; his condition was still clinically compensated despite being under ongoing follow-up from a cardiologist. He also had a history of substantial tobacco exposure, representing an additional vascular risk factor. In addition, the patient had a history of generalized anxiety disorder and had been taking benzodiazepines for almost two decades. At home, the patient was receiving aspirin 81 mg once daily for secondary cardiovascular and cerebrovascular prevention, atorvastatin 40 mg once daily for lipid-lowering therapy, carvedilol 6.25 mg twice daily as part of chronic heart-failure and coronary artery disease management, and clonazepam 0.5 mg once daily at night for long-standing generalized anxiety disorder. These medications were continued under the supervision of his treating physicians.

There was no history of hypertension, diabetes mellitus, chronic kidney disease, chronic pulmonary disease, autoimmune disease, cancer, or any drug allergies in the patient's past medical history. There was no family history of inherited neurological disease.

Initial Clinical Assessment

On presentation, the patient was fully awake and oriented, with no signs of acute distress. His vital signs were normal, and there was no clinical evidence of recurrences of any cerebrovascular accidents or neurologic decline. Examination was remarkable for the persistence of weakness in the right upper extremity with marked decrease in sensation and decreased strength as compared to the opposite side. He had clinically significant spasticity, consistent with a baseline Modified Ashworth Scale score of 3. The patient had mild gait instability and poor balance but was still able to walk independently without any ambulatory aids.

His main complaints include chronic fatigue, exercise intolerance, persistent numbness of the right upper extremity, and decreased confidence when walking. Cardiac exam showed regular cardiac rhythm without signs of acute decompensation of heart failure. No clinical signs of acute cardiopulmonary instability were observed at baseline. The rest of his physical examination was nonremarkable.

Baseline Functional Assessment

Objective criteria for the patient's level of brain impairment and functioning were determined at baseline using clinically validated outcome measures to serve as a reference for subsequent changes during the six-month follow-up period as illustrated in Table 1. According to Table 1, the patient had a mild neurological dysfunction with respect to overall functioning (scores of 2 on mRS and NIHSS scales), while he demonstrated moderate clinical spasticity (score of 3 on MAS scale), poor walking endurance and low energy perception, yet was completely independent in ADLs (Barthel Index was equal to 100/100. Thus, these results showed that the patient had certain functional impairments which could be followed longitudinally during the observation period. These data were indicative of mild neurological dysfunction in terms of upper extremity involvement, muscle hypertonia, decreased endurance, and energy perception, yet intact independence in ADLs.

Diagnostic Assessment

The diagnosis of chronic ischemic stroke was confirmed taking into account the patient's clinical history, past neuroimaging showing cerebral infarction, neurological assessment, and neurological dysfunction which could not be reversed through standard rehabilitation. Prior to starting the treatment protocol under the regenerative medicine program, the patient was subjected to pre-treatment evaluation

[Downloaded from ijmcmed.org on 2026-11-23]

[DOI: 10.22088/IJMCM.BUMS.15.2.1493]

involving an analysis of medical history, neurological and cardiovascular evaluation, laboratory work up, and functional status evaluation. There were no findings indicating ongoing infection, acute stroke, acute coronary syndrome, decompensated heart failure, or any other identified clinical contraindication to proceeding with the planned intervention based on the available assessment.

Baseline Vascular and Cardiac Evaluation: Before initiation of regenerative therapy, the patient underwent vascular and cardiovascular assessment because of his previous ischemic stroke and cardiovascular history. Carotid Doppler ultrasonography showed no hemodynamically significant carotid artery stenosis. Baseline electrocardiography demonstrated sinus rhythm without an acute ischemic pattern, and cardiac evaluation showed clinically compensated chronic heart failure without evidence of acute decompensation.

Ambulatory rhythm monitoring did not demonstrate sustained atrial fibrillation or another clinically significant arrhythmia. Major vascular risk factors included advanced age, previous ischemic stroke, established coronary artery disease with a remote myocardial infarction, chronic heart failure, and substantial previous tobacco exposure. No history of hypertension or diabetes mellitus was documented.

Table 1. Baseline Functional Assessments

Outcome Measure	Baseline
Modified Rankin Scale (mRS)	2
National Institutes of Health Stroke Scale (NIHSS)	2
Modified Ashworth Scale (MAS)	3
Barthel Index	100/100
Six-Minute Walk Test (6MWT)	220 m
Energy Visual Analog Scale (VAS)	3/10

Clinical Decision-Making

After multidisciplinary assessment, the patient was judged suitable for regenerative therapy due to the presence of residual neurological deficits that had stabilized after completing standard rehabilitation therapy. The therapeutic approach was designed to support and complement rather than replace standard stroke care and focused on intravenous allogeneic umbilical cord-derived mesenchymal stromal cell (UC-MSC) therapy followed by MSC-derived secretome therapy, with other supportive interventions incorporated as part of the multimodal regenerative protocol. The aims were to explore longitudinal functional changes and assess the safety and feasibility of the overall multimodal approach.

Prior to the commencement of the intervention, a thorough informed consent was obtained. The patient was educated on the fact that the regenerative intervention being considered is still experimental and was informed about the current level of evidence, the uncertainty of therapeutic benefit, potential risks and complications, available alternative treatment options, and the need to continue standard stroke management and secondary prevention. Upon discussion, the patient decided to go ahead with the proposed intervention.

Therapeutic Intervention

Overview of the Multimodal Regenerative Medicine Protocol

Based on the multidisciplinary assessment and collaborative decision-making, the patient was subjected to a personalized multimodal regenerative medicine approach conducted by Sure Health 360 Center for Regenerative Medicine and Cell Therapy. The intervention was delivered as an adjunctive treatment to the conventional evidence-based approach for stroke management and multidisciplinary rehabilitation. The regenerative strategy centered on allogeneic umbilical cord-derived mesenchymal stromal cell (UC-MSC) therapy and subsequent MSC-derived secretome therapy, with other interventions serving supportive roles before and after cellular therapy.

The protocol was made up of 6 sequential phases:

1. Hyperbaric Oxygen Therapy (HBOT)
2. Metabolic Optimization
3. Cellular Priming

[Downloaded from ijmcmed.org on 2026-11-23]

[DOI: 10.22088/IJMCM.BUMS.15.2.1493]

4. Intravenous Allogeneic Umbilical Cord-Derived Mesenchymal Stromal Cell (UC-MSC) Therapy
5. Early Post-Infusion Support
6. Maintenance MSC-Derived Secretome Therapy

The sequence was selected based on the biological rationale of preparing the systemic and tissue microenvironment before MSC administration, providing supportive care during the immediate post-infusion period, and maintaining MSC-derived paracrine support through secretome therapy during longitudinal follow-up. Throughout treatment, conventional secondary stroke prevention, pharmacologic therapy, and multidisciplinary rehabilitation were continued without interruption.

Phase I – Hyperbaric Oxygen Therapy

The treatment began with hyperbaric oxygen therapy performed by soft shell hyperbaric chamber at 1.5 ATA, following the institutional treatment protocol. The treatment was performed as a preconditioning measure prior to UC-MSC administration, and all standard procedures for monitoring of vital parameters and treatment tolerance were carried out.

HBOT was incorporated as an adjunctive preconditioning modality before cellular therapy. The patient completed the planned treatment course without evidence of oxygen toxicity, barotrauma, seizure activity, or treatment-limiting complications.

Phase II – Metabolic Optimization

Following the initial HBOT course, the patient underwent an individualized metabolic optimization program while continuing maintenance HBOT. Intravenous therapy included nicotinamide adenine dinucleotide (NAD^+), antioxidant therapy, mitochondrial cofactors, vitamin supplementation, and metabolic support administered according to the institutional protocol.

The aim of this stage was to deliver metabolic and supportive care at the time of UC-MSC administration. Infusion tolerance was good and no infusion-related adverse events were noted which were clinically significant.

Phase III – Cellular Priming

The patient received a standardized cellular priming protocol (IV metabolic and antioxidant support and routine premedication) immediately before UC-MSC administration to reduce the likelihood of infusion-related hypersensitivity reactions. The priming phase did not have any complications.

Phase IV – Intravenous Allogeneic Mesenchymal Stromal Cell Therapy

The patient was intravenously infused with 100 million allogeneic human umbilical cord-derived mesenchymal stromal cells (UC-MSCs), which is about 2 × 10 6 cells per kilogram of body weight. The UC-MSC product was derived from human umbilical cord tissue obtained from a healthy 28-year-old female donor following full-term delivery, with written donor consent and screening for transmissible infectious diseases.

The umbilical cord tissue was processed under aseptic Good Manufacturing Practice (GMP) conditions, and the isolated cells were expanded in culture using a xeno-free, serum-free MSC culture medium at 37°C in 5% CO_2 . Cells were expanded to passage 3 and cryopreserved until clinical use. Before administration, the product was thawed and assessed for viability, sterility, cellular identity, and safety. Post-thaw cell viability was greater than 90%. Immunophenotypic characterization demonstrated positivity for CD73, CD90, and CD105 and absence of hematopoietic markers CD34 and CD45, consistent with the expected MSC phenotype. The final product was additionally tested for bacterial and fungal sterility, mycoplasma, endotoxin, and other routine product-release safety parameters before intravenous administration.

The infusion was performed under continuous physician supervision with routine monitoring of vital signs and clinical status. An MSC-derived neurosecretome was also administered on the day of cell therapy as part of the institutional regenerative treatment strategy. The MSC-derived neurosecretome was produced from cultured umbilical cord-derived MSCs maintained under aseptic Good Manufacturing Practice conditions. The parental MSCs were expanded to passage 3 in serum-free/xeno-free culture medium at 37°C in 5% CO_2 . After reaching the required confluence, the cells were washed and maintained in conditioned medium for 24–48 hours. The conditioned medium was then collected and subjected to sequential centrifugation and filtration to remove cells and cellular debris, followed by concentration under controlled processing conditions.

[Downloaded from ijmcmed.org on 2026-11-23]

[DOI: 10.22088/IJMCM.BUMS.15.2.1493]

The final secretome preparation was aliquoted and stored at −80°C until clinical use. Before administration, the preparation underwent quality-control assessment for sterility, purity, total protein content, extracellular-vesicle-associated characteristics, and biological activity. MSC-derived secretome contains a mixture of paracrine mediators and may include extracellular vesicles. For the preparation administered in this case, the available certificate of analysis documented extracellular-vesicle-associated characterization, including particle size and concentration, EV-associated markers, selected protein and microRNA profiling, and an in vitro potency assessment. The MSC-derived secretome preparation contained extracellular vesicle-enriched fractions with a mean particle size of approximately 100–150 nm and a particle concentration in the range of 10^{9} –10^{10} particles/mL.

The vesicle fraction demonstrated expression of commonly used extracellular-vesicle-associated markers, including CD63, CD81, and CD9. Protein profiling identified paracrine factors associated with angiogenic and neurotrophic activity, including VEGF, BDNF, and HGF, while selected regulatory microRNAs associated with neuroprotection and angiogenesis, such as miR-21 and miR-126, were detected. Biological activity was assessed using an in vitro potency assay based on cell viability/proliferation and angiogenic activity, with the preparation meeting the predefined institutional release criteria before administration. No infusion-related reactions, allergic events, cardiopulmonary instability, or other immediate complications were observed during or immediately after administration.

Phase V – Early Post-Infusion Support

Metabolic support therapy was administered following the UC-MSC infusion period under the institution's regenerative protocol as supportive care during the early post-infusion period. The patient maintained clinical stability throughout this period, and no adverse effects from the therapy were reported.

Phase VI – Maintenance Regenerative Therapy

Regenerative maintenance therapy was carried out continuously over the follow-up period and included repeated injections of MSC-derived secretome, which may contain a range of paracrine mediators, including extracellular vesicles, along with hyperbaric oxygen maintenance therapy as per the personalized regimen. About two months post administration of MSCs, the patient went abroad for about a month's time, leading to a halt in maintenance HBOT. No subjective/objective neurological deterioration was seen in this period of time. After returning home, the maintenance therapy started without any problem until the occurrence of a recurrent cerebrovascular event during the follow-up period.

Safety Monitoring

Follow-ups were conducted during the treatment period by multidisciplinary clinical assessment. This involved performing neurological exams, assessments of outcomes, reactions to infusions, cardiorespiratory stability, adverse events that were not immediate, and treatment tolerance. Events that occurred during the follow-up period, which include a hypotensive event and an ischemic stroke, will be discussed in the Safety and Adverse Clinical Events section. Based on the available clinical information, no definite causal relationship between these events and the regenerative interventions could be established.

This therapy was carried out using a step-by-step multimodal protocol of regenerative medicine, which is aimed at supplementing conventional stroke treatment and rehabilitation procedures. The flowchart representing treatment stages and their goals is shown in Figure 1 below.

Figure 1 illustrates that the treatment strategy employed a step-by-step protocol starting with baseline evaluation through hyperbaric oxygen therapy, metabolic optimization, cellular priming, allogeneic UC-MSC treatment, early post-infusion support, MSC-derived secretome maintenance therapy, and long-term follow-up. Each stage was aimed at providing supportive care and enabling continual monitoring of clinical outcomes and safety.

After multidisciplinary evaluation and informed consent, the patient was subjected to step-by-step regenerative medicine protocol combined with conventional stroke treatment and rehabilitation. This protocol included baseline clinical evaluation, hyperbaric oxygen therapy, metabolic optimization, cellular priming, intravenous administration of allogeneic umbilical cord-derived mesenchymal stromal cells (UC-MSCs), early post-infusion support, MSC-derived secretome maintenance therapy, and long-term clinical follow-up.

[Downloaded from ijmcmed.org on 2026-11-23]

[DOI: 10.22088/IJMCM.BUMS.15.2.1493]

Follow-up and Outcomes

Follow-up was conducted in the longitudinal fashion on the schedule during the six-month observation period. Evaluations were carried out periodically and included neurological exams, objective measures of functional status, adverse event monitoring, and subjective measures of functional status. Pharmacologic treatment, secondary stroke prophylaxis, and multidisciplinary rehabilitation continued throughout the observation period. During the early months of follow-up, improvements were observed in selected clinical domains after initiation of the multimodal regenerative medicine protocol, including UC-MSC administration and subsequent MSC-derived secretome therapy. Improvements were mainly seen in the areas of muscle tone, sensation, exercise tolerance, balance, and energy .Neurological examination showed steady improvement in sensory function in the right arm along with improved grip strength and decreased muscle spasticity. Improvement in fine motor skills was observed as well when compared to the patient's baseline values; however, mild neurologic impairments were still present. Patient maintained independent walking ability without assistance. Neurological disability score was consistently stable according to the standardized tests with steady improvement in selected functions.

NIHSS and mRS scores were stable throughout the entire follow-up period with improvements observed in muscle tone, physical abilities, and energy level. At the six-month assessment, the Modified Ashworth Scale (MAS) score improved from 3 to 1, Six-Minute Walk Test (6MWT) score improved from 220 m to 360 m, while Energy Visual Analog Scale (VAS) score improved from 3/10 to 8/10.

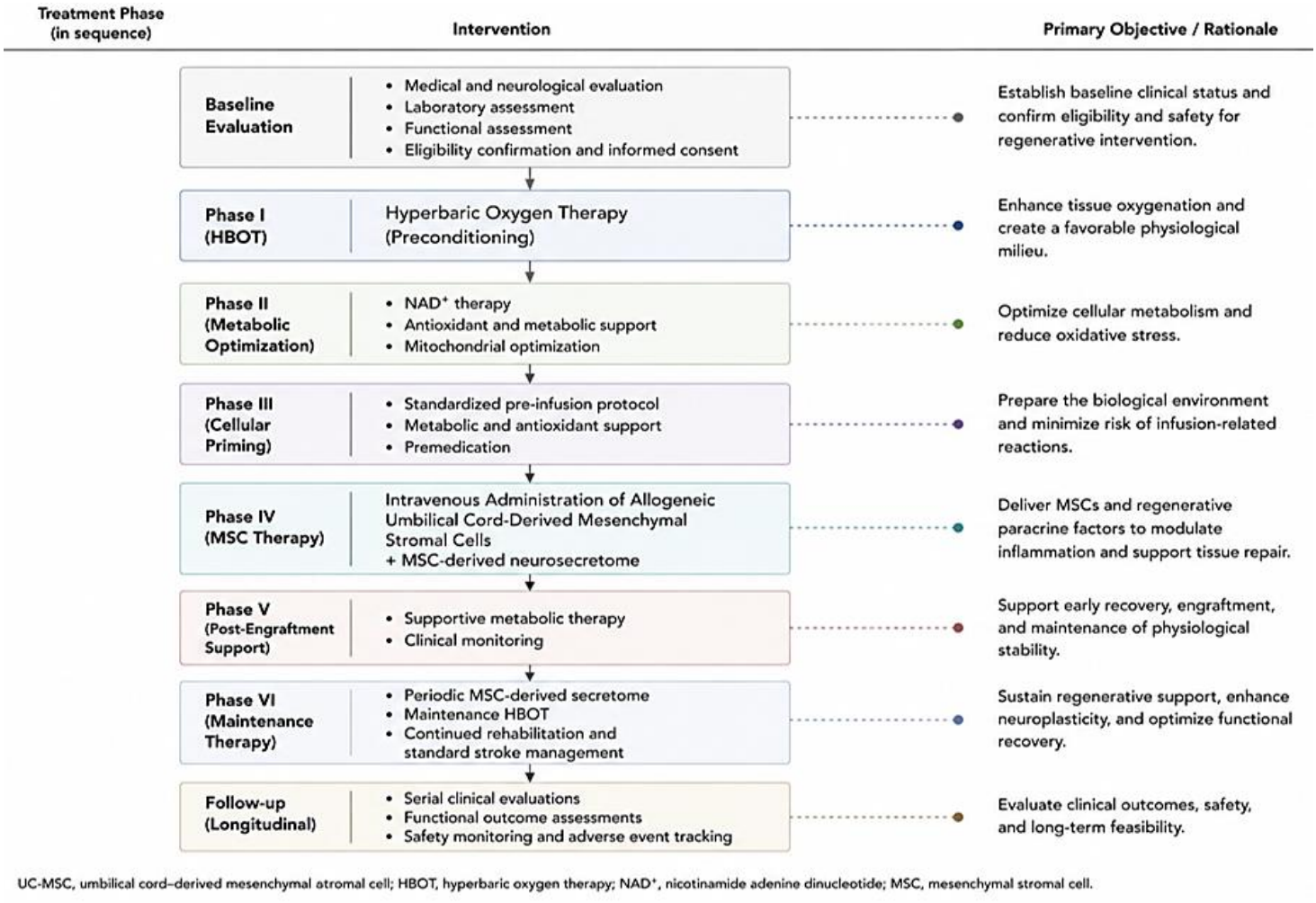

Figure 1. Multimodal Regenerative Medicine Treatment Protocol

[Downloaded from ijmcmed.org on 2026-11-23]

[DOI: 10.22088/IJMCM.BUMS.15.2.1493]

The score on the Barthel Index remained unchanged at 100/100, reflecting maintenance of independence in ADLs throughout the observation period. The patient expressed satisfaction with the improvements he experienced in terms of his endurance, mobility, and overall quality of life. The patient noted that it was easier for him to carry out everyday activities, he felt more confident when walking, and he did not feel as fatigued while being physically active. There was no sign of deterioration in the patient's cognitive functioning, speech, ability to swallow and ADLs during follow-up appointments.

In general, the longitudinal assessments showed stable functional status with improvements in some clinical outcomes during the observation period. Because multiple interventions were delivered concurrently, these observed changes cannot be attributed specifically to UC-MSC therapy or MSC-derived secretome therapy. Table 2 provides a summary of the serially measured clinical outcomes.

Table 2. Longitudinal Functional Outcome Measures

Outcome Measure	Baseline	1 Month	3 Months	6 Months
NIHSS	2	2	2	2
Modified Rankin Scale (mRS)	2	2	2	2
Modified Ashworth Scale (MAS)	3	2	1	1
Barthel Index	100	100	100	100
Six-Minute Walk Test (6MWT), m	220	Not assessed	Not assessed	360
Energy VAS (0–10)	3	Not assessed	Not assessed	8
Right Upper Extremity Sensation	Markedly diminished	Improved	Further improved	Sustained improvement
Grip Strength	Reduced	Improved	Further improved	Sustained improvement
Balance	Mild instability	Improved	Improved	Stable
Ambulation	Independent	Independent	Independent	Independent

As depicted in Table 2, the neurological disability scales did not change during the follow-up period, while progressive gains were seen in muscle spasticity, sensation in the upper extremities, grip strength, balance, endurance for walking, and energy. Independence in performing activities of daily living was also preserved throughout the entire observation period. These findings represent observed longitudinal changes within a multimodal treatment setting and should not be attributed to any single intervention.

Safety Monitoring and Adverse Clinical Events

The patient was monitored prospectively for safety during the six-month observation period. Clinical assessment included regular neurological examination, monitoring of vital signs, evaluation for infusion reactions, cardiopulmonary assessment, and observation for delayed adverse events. Vascular and Coagulation Safety Monitoring: Thrombotic and coagulation-related safety monitoring was performed before and after intravenous UC-MSC administration. Baseline evaluation included platelet count, prothrombin time (PT), international normalized ratio (INR), activated partial thromboplastin time (aPTT), and routine hematologic assessment. These parameters were reassessed following the infusion as part of clinical safety monitoring. No clinically significant thrombocytopenia, coagulation abnormality, or laboratory evidence suggestive of an acute thrombotic complication was identified during the immediate post-infusion period.

Clinical monitoring also included assessment for new neurological symptoms, limb swelling, respiratory compromise, chest pain, and other manifestations potentially suggestive of thromboembolic complications. No acute infusion reactions,

[Downloaded from ijmcmed.org on 2026-11-23]

[DOI: 10.22088/IJMCM.BUMS.15.2.1493]

hypersensitivity reactions, infectious complications, or clinically apparent thromboembolic events were observed during or immediately after administration of allogeneic umbilical cord-derived mesenchymal stromal cells (UC-MSCs) and subsequent MSC-derived secretome therapy. Approximately two months after MSC administration, the patient traveled abroad for about one month, which led to temporary cessation of maintenance hyperbaric oxygen therapy.

In the course of follow-up, the patient presented a brief period of hypotension occurring during the course of hyperbaric oxygen treatment. Systolic/diastolic blood pressure reduced to approximately 80/60 mmHg; heart rate was 60 beats per minute. Glucose levels in capillary blood were measured to be 5.5 mmol/L. The patient was admitted to the ED for further evaluation. Repeated examination showed that spontaneous normalization of the vital parameters took place (systolic/diastolic blood pressure – 110/80 mmHg, heart rate – 63 beats per minute) without any signs of myocardial ischemia, neurological disorders, or acute comorbidities. At approximately Month 4 of follow-up, the patient presented with neurological complaints of dysarthria and right hemiparesis and was hospitalized due to these manifestations. Imaging study revealed acute stroke in the left cerebral artery territory on the background of chronic right temporoparietal-occipital infarcts.

The patient was managed according to guidelines for acute stroke. Clinical assessment identified several established vascular risk factors, including a history of ischemic stroke, coronary artery disease, chronic heart failure, and advanced age. The recurrent cerebrovascular event occurred several months after the initial UC-MSC administration. Although no immediate infusion-related toxicity or procedural complication had been observed, a causal relationship between the regenerative interventions and the recurrent stroke cannot be definitively established or excluded in a single case. After stabilization and standard stroke management, follow-up continued.

Several previously observed functional improvements persisted, including muscle tone, exercise tolerance, and independence in activities of daily living. Similarly, the relationship between the hypotensive episode and the regenerative interventions could not be determined with certainty from this single clinical observation. No treatment-related serious adverse event was definitively identified during the observation period based on the available clinical assessment.In order to have a clear picture of the clinical history of the patient as well as the treatment process, the chronological presentation of interventions performed, the clinical events that occurred, and the functional recovery during the six months of observation is presented in Figure 2 below. Figure 2 summarizes the chronological clinical course of the patient from baseline evaluation through six months of follow-up. The principal regenerative interventions included intravenous umbilical cord-derived mesenchymal stromal cell (UC-MSC) administration followed by maintenance MSC-derived secretome therapy, alongside hyperbaric oxygen therapy, metabolic optimization, cellular priming, rehabilitation, and evidence-based secondary stroke prevention. Functional assessments were performed longitudinally using standardized neurological and functional outcome measures. During follow-up, the patient experienced a transient hypotensive episode and a recurrent ischemic stroke, both of which were managed according to standard clinical practice. These events were documented as part of the longitudinal safety assessment, without assigning a definitive causal relationship to the regenerative interventions. Follow-up continued after recovery, and functional outcomes were reassessed at six months after the Month 4 recurrent stroke and subsequent stabilization.

Patient Perspective

The patient had pre-program regenerative medicine history that included constant weakness of the right upper extremity, hand deficiency, gait problems, decreased stamina and restrictions of daily living activities despite prior traditional stroke therapy and rehabilitation. These residual deficits impacted on his self-confidence, autonomy and general quality of life. Follow-up showed that the patient stated that he slowly started to feel better in relation to upper-extremity sensation, hand grip, walking stability, endurance, and confidence in his ability to perform normal daily activities. Another aspect he reported was an improvement in energy levels and involvement in family and social activities. The above observations were aligned with those reported by family members who reported that there were improvements in the mobility, balance and general engagement when the follow-up was done.

[Downloaded from ijmcmed.org on 2026-11-23]

[DOI: 10.22088/IJMCM.BUMS.15.2.1493]

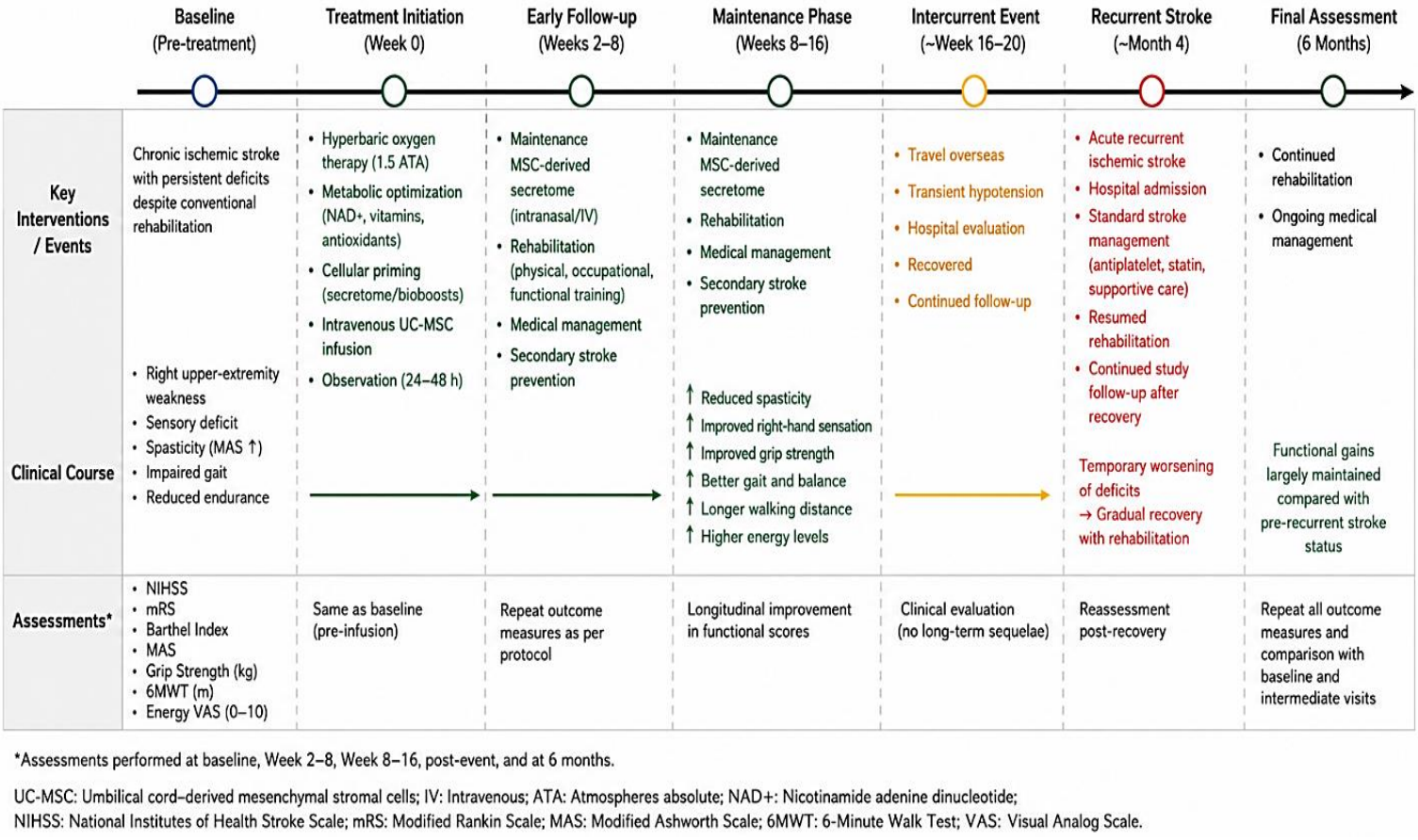

Figure 2. Clinical timeline of multimodal regenerative therapy, follow-up, and major clinical events.

The patient understood that the regenerative interventions were experimental adjunctive treatments and were not intended to replace evidence-based stroke management. He was also aware that clinical benefit could not be guaranteed. He expressed satisfaction with the multidisciplinary approach, which integrated regenerative medicine with ongoing medical therapy, secondary stroke prevention, and rehabilitation. Following the recurrent ischemic stroke, he remained motivated to continue rehabilitation and long-term vascular risk-factor modification under the guidance of his treating physicians.

Written informed consent was obtained for treatment, longitudinal clinical follow-up, and publication of this anonymized case report. The patient reviewed this narrative before manuscript submission and confirmed that it accurately reflected his clinical experience. The patient perspective was prepared from contemporaneous clinical documentation and follow-up interviews and reviewed by the patient before submission.

Discussion

Principal Findings

This case report describes the six-month clinical course of a 73-year-old man with chronic post-ischemic stroke who underwent an individualized multimodal regenerative medicine protocol integrated with conventional secondary prevention and multidisciplinary rehabilitation. The principal regenerative interventions were intravenous administration of allogeneic umbilical cord-derived mesenchymal stromal cells (UC-MSCs) and subsequent MSC-derived secretome therapy, which may contain extracellular vesicles as components of its paracrine milieu. HBOT, metabolic optimization, and cellular priming were incorporated as supportive components of the protocol. It was observed that during the observation period, there was improvement in muscle tone, walking endurance, sensation in the right upper extremity, grip strength, balance, gait stability, and energy level. The Modified Ashworth

[Downloaded from ijmcmed.org on 2026-11-23]
[DOI: 10.22088/IJMCM.BUMS.15.2.1493]

Scale improved from 3 to 1, the Six-Minute Walk Test increased from 220 m to 360 m, and the Energy Visual Analog Scale improved from 3/10 to 8/10. The Barthel Index remained 100/100, indicating preservation of independence in activities of daily living. NIHSS and modified Rankin Scale scores remained stable, suggesting that the observed changes were more apparent in domain-specific functional outcomes than in global disability measures.

The patient subsequently developed a recurrent ischemic stroke during follow-up. After guideline-directed acute stroke management, several previously documented functional gains were maintained. No immediate treatment-related serious adverse event was identified; however, a causal relationship between the recurrent stroke and the regenerative interventions cannot be definitively established or excluded from a single case. Because UC-MSC therapy, secretome administration, HBOT, metabolic optimization, cellular priming, rehabilitation, and conventional medical management were delivered within the same multimodal protocol, the contribution of any individual component cannot be determined. Accordingly, these findings should be regarded as exploratory and hypothesis-generating rather than evidence of therapeutic efficacy.

Mesenchymal Stromal Cell Therapy in Ischemic Stroke

The use of mesenchymal stromal cells has been explored in ischemic stroke owing to their immune-modulatory, trophic, angiogenic, and neuroprotective functions. It has now become evident that the effect of these cells is mainly mediated through paracrine effects rather than any direct engraftment or replacement of the dead neurons. They are thought to secrete cytokines, chemokines, growth factors, extracellular vesicles, including exosome-sized vesicles, and regulatory nucleic acid molecules, which may affect microglial activation, peripheral immune response, endothelial function, angiogenesis, synaptogenesis, and neurogenesis.

Clinical trials, however, have produced inconsistent results. In one phase 2 clinical trial called the MASTERS study, multipotent adult progenitor cells administered intravenously in patients with ischemic stroke were safe and well-tolerated in the acute phase of the disease, although the efficacy endpoint was not achieved.

The phase 2/3 TREASURE trial likewise demonstrated that IV allogeneic stem cell therapy was well-tolerated when used in the early phase after acute ischemic stroke (18–36 hours post-stroke) but did not yield any clinically meaningful improvements in a predefined short-term clinical outcome endpoint compared to placebo treatment. These findings illustrate that biological plausibility and acceptable short-term safety do not necessarily translate into clinical efficacy. The STARTING-2 trial assessed intravenous infusion of autologous, preconditioned MSCs for patients with chronic major ischemic stroke. The delivery of MSCs was well-tolerated and safe, but no statistically significant improvements were seen on a predefined primary modified Rankin Scale outcome after 90 days of treatment.

Other randomized clinical trials have shown better motor results. Jaillard et al. showed that autologous mesenchymal stem cells increased motor recovery after subacute ischemic stroke; however, due to small sample size, timing of intervention, and selection of outcome measure and cell preparation, a direct comparison with other clinical trials is difficult. Phase 2 clinical trial with intravenous bone marrow-derived mesenchymal stem cells in subacute middle cerebral artery infarction was found to be safe; however, there were no neurological or functional differences between groups at 12 months, even though there was a reported difference in the volume of infarction.

In summary, intravenous MSC-based therapy appears feasible and has generally shown acceptable short-term safety in clinical studies, whereas evidence for efficacy remains inconsistent. Differences in cell source, donor characteristics, manufacturing processes, passage number, cell viability, dose, route and timing of administration, stroke severity, rehabilitation exposure, and outcome measures may contribute to this variability. Accordingly, the present case should be interpreted within a field in which safety evidence is more consistent than evidence of therapeutic efficacy.

Biological Plausibility of the Multimodal Regenerative Approach

The scientific basis for the multimodal approach to regenerative medicine outlined in this patient report is based on the current scientific understanding of the biological basis of recovery from ischemic stroke. Recovery after such a condition involves a variety of processes including inflammation control, vascular

[Downloaded from ijmcmed.org on 2026-11-23]

[DOI: 10.22088/IJMCM.BUMS.15.2.1493]

adaptation, cellular metabolism, extracellular communication, and activity-dependent plasticity. Unlike using only one method of treatment, in the present case, multiple physiological processes that might be contributing to natural healing were aimed at. Most importantly, this protocol is intended to complement the established principles of medical treatment of stroke patients. Currently, it has been proven that the therapeutic effects of mesenchymal stromal cells (MSCs) are exerted mainly via paracrine mechanisms. Earlier models of regenerative medicine were based on the idea that transplanted MSCs could serve as direct replacements for the damaged neurons; yet, many experimental studies have proved that only a limited number of donor cells survive in the central nervous system post systemic transplantation. In contrast, the major role of MSCs seems to be that of secretion of biologically active molecules that affect the host's microenvironment, reduce secondary damage, and induce the host's repair mechanisms. This finding has revolutionized our understanding of how MSC therapy works (1-5).

The secretome of the MSC is made up of a variety of cytokines, chemokines, growth factors, extracellular matrix proteins, lipid mediators, messenger RNA, microRNA, and extracellular vesicles, which are involved in cell-cell communications. Pre-clinical studies have reported that the mediators might lower the level of microglial activation, induce polarization towards anti-inflammatory phenotypes, decrease pro-inflammatory cytokine synthesis, increase angiogenesis, repair the endothelium, maintain the integrity of the blood-brain barrier, and improve neuronal survival. Moreover, the role of several other functions such as axonal sprouting, dendritic remodeling, survival of oligodendrocytes, and synaptic plasticity has been proposed for the MSC-derived mediators, thus aiding functional recovery in stroke patients (2-6). Recent attention has been paid to extracellular vesicles (EV), which include exosomes, as mediators of MSC biology. These vesicles contain the protein, lipids, messenger RNA, and microRNA, which influence the recipient cells without the requirement of persistent presence of the transplanted MSCs (13-14). Pre-clinical studies have shown improvement in angiogenesis, neurogenesis, axonal remodeling, and behavioral recovery with MSC-derived EVs treatment in stroke models. These findings have generated increasing interest in cell-free regenerative therapies because they may preserve many of the beneficial paracrine effects of MSCs while reducing several theoretical risks associated with live-cell transplantation, such as limited cell survival, manufacturing variability, and cryopreservation-related injury. Nevertheless, clinical evidence supporting EV or secretome therapy in ischemic stroke remains limited, and standardized manufacturing, characterization, potency assays, and dosing strategies have yet to be established. Consequently, extracellular vesicle therapy should currently be regarded as investigational (15-18).

The present case incorporated maintenance MSC-derived secretome therapy after intravenous UC-MSC administration. Although this sequencing was based on a proposed paracrine rationale, its biological contribution cannot be determined from this single case. Secretome therapy was administered alongside rehabilitation, hyperbaric oxygen therapy, metabolic optimization, cellular priming, and standard stroke care; therefore, the contribution of any individual component cannot be separated. The sequence should consequently be regarded as a multimodal clinical protocol rather than evidence of therapeutic synergy. HBOT was incorporated as a supportive component; although it has been investigated for potential effects on tissue oxygenation, angiogenesis, cerebral perfusion, and neuroplasticity, current evidence remains heterogeneous and does not establish it as a restorative treatment for chronic ischemic stroke (19-20). Metabolic optimization and cellular priming were also incorporated as supportive components before UC-MSC therapy; however, their individual contributions to the observed clinical outcomes cannot be determined.

Recovery after chronic stroke involves multiple interacting processes, including immune modulation, vascular adaptation, synaptic remodeling, motor relearning, and activity-dependent neuroplasticity. Accordingly, the functional changes observed in this case should be interpreted within the context of the complete multimodal management strategy rather than as evidence of a specific regenerative mechanism.

The observed changes were largely domain-specific, involving spasticity, walking endurance, balance, gait stability, upper-extremity sensation, grip strength, and energy, while global disability measures remained stable. Because this was an uncontrolled single case involving multiple simultaneous

[Downloaded from ijmcmed.org on 2026-11-23]

[DOI: 10.22088/IJMCM.BUMS.15.2.1493]

interventions, these observations cannot establish causal or mechanistic relationships. Additional translational research that includes neuroimaging, molecular biomarker, standardized secretome characterization, and multi-dimensional functional testing is necessary to explain the biological mechanisms related to MSC- and secretome-based methods.

Interpretation of the Recurrent Ischemic Stroke

The repeated ischemic stroke, which took place at approximately Month 4 following the start of the multimodal regenerative protocol, is a significant safety event that needs careful interpretation. Such complications should be reported transparently as part of translational medicine and align with CARE principles. In secondary prevention, recurrent ischemic stroke might still happen especially in the elderly with a known vascular disease. In the case, the patient was known to have various vascular risk factors, such as advanced age, prior ischemic stroke, coronary artery disease, chronic heart failure, and prior substantial tobacco exposure.

These susceptible vascular pathologies offer good alternative reasons as to why the stroke frequently recurred, but they do not prove that the occurrence was not related to the regenerative intervention. No immediate infusion-related neurological deterioration, cardiopulmonary instability, hypersensitivity reaction, or clinically apparent thromboembolic complication was documented following UC-MSC administration. Nevertheless, because this is a single case, a causal relationship between the recurrent stroke and the regenerative interventions cannot be definitively confirmed or excluded.

Previous clinical studies, including the MASTERS, TREASURE, and STARTING-2 trials, have generally reported acceptable safety profiles for intravenously administered cellular therapies and have not identified recurrent ischemic stroke as a consistent treatment-related complication.7-9 However, these findings do not exclude uncommon vascular or thrombotic events, particularly because individual trials may have limited ability to detect rare adverse outcomes.

The recurrent event should therefore be interpreted in the context of both the patient's substantial baseline cerebrovascular risk and the theoretical vascular safety considerations associated with intravenous cellular therapy. Assessment of such events requires consideration of temporal relationships, alternative vascular causes, clinical findings, imaging, background disease, and concurrent treatments. In the present case, the available evidence was insufficient to establish treatment-related causality.

Several functional improvements documented before the recurrent stroke, including changes in muscle tone, walking tolerance, balance, and energy, remained evident after acute stroke management. These observations should also be interpreted cautiously because rehabilitation, recovery from the recurrent event, neuroplasticity, and other components of the multimodal management strategy may have contributed. The systematic vascular safety surveillance, adjudicated adverse-event assessment, and extended follow-up of patients with chronic ischemic stroke should be included in future studies to characterize the safety of MSC-based interventions in patients better.

Interpretation of the Functional Outcomes

In the present case, it was found that there was an improvement in a number of functional domains in particular and global neurological disability scores had not significantly changed. The over six months found reductions in muscle spasticity, increased walking tolerance, right upper-extremity sensation and grip strength, enhanced balance and gait stability, and increased patient-reported energy. Conversely, the NIHSS, mRS and Barthel Index scores did not exhibit any or minimal changes. This trend indicates that local adaptations in domains might not be well captured by universal measures of disability.

NIHSS is mainly aimed to measure neurological impairment whereas modified Rankin Scale is used to indicate the general disability. These measures might not be as sensitive to change in endurance, dexterity, or other specific functions in ambulatory patients with chronic deficits. Follow up revealed that the patient was independent, which could also be the reason why the Barthel Index and mRS did not change regardless of the selected functional domains. In regenerative stroke studies, similar differences between measures of disability globally and functional outcomes within a specific functional area have been found.[9-12] These observations reinforce the idea of using multidimensional outcome measure instead of the use of a single global endpoint.

[Downloaded from ijmcmed.org on 2026-11-23]

[DOI: 10.22088/IJMCM.BUMS.15.2.1493]

The decrease in the Modified Ashworth Scale score to 1 indicates a significant change in muscle tone, and the increase in the Six-Minute Walk Test distance to 360 m signifies a positive change in the walking endurance. But these changes are to be understood as functional observations and not as evidence of actual regeneration of the neurons. Several factors might affect walking performance such as rehabilitation, cardiovascular conditioning, gait mechanics, confidence, and physical activity.

The enhancement in the sensation and grip strength of the right upper-extremity were also noted. Nevertheless, quantitative measures of upper-extremity (i.e. Fugl-Meyer Assessment, Action Research Arm Test, Box and Block Test, or instrumented grip dynamometry) were omitted.

This restricts the accuracy of describing the upper-limb recovery. Follow-up also saw an improvement in patient-reported energy. Since post-stroke fatigue is affected by neurological, cardiovascular, psychological, and behavioral factors, as well as factors related to treatment, the improvement in energy seen cannot be linked specifically to the UC-MSC or secretome therapy.

The functional trajectory that was observed was provided in a multimodal treatment environment which consisted of rehabilitation, medical management, metabolic optimization, HBOT, UC-MSC administration and MSC-derived secretome therapy. In this regard, any individual intervention contribution cannot be separated, and the results must be viewed as the exploratory observations of the joint clinical intervention as opposed to demonstrating a certain treatment effect. The multidimensional functional measures, quantitative upper-extremity testing, neuroimaging, and the relevant biomarkers should be included in future research to more fully describe recovery.

Strengths and Limitations

The weaknesses of the single-patient observational design outweigh the strengths of the current case report, but there are still a few strengths of this design. Prospective six-month follow-up of the patient was conducted on the basis of pre-determined neurological and functional outcome measures.

Various complementary tests were employed such as the global disability scales, muscle spasticity, walking endurance, grip strength, sensory functional, balance, gait, and patient-reported energy. This longitudinal and multidimensional measure was a more extensive account of the functional pathway of the patient compared to the use of the global disability scales.

The report also includes an in-depth description of a multimodal regenerative medicine regimen involving intravenous UC-MSC infusion and MSC-derived secretome treatment, including standard stroke management and multidisciplinary rehabilitation. The other strength is that it reported adverse clinical events such as transient hypotension and frequent ischemic stroke as opposed to reporting positive results only. The regenerative interventions were also used as adjuncts to, rather than replacements for, conventional secondary prevention and rehabilitation.

There are a number of significant limitations that need to be highlighted. To start with, it is one uncontrolled case and as such, cannot prove therapeutic efficacy, causality or generalizability. The observed functional changes can be attributed to rehabilitation, natural variability, behavioral changes, increased physical activity, placebo effects or other unmeasured effects.

Second, the multimodal nature of the protocol prevents attribution of the observed outcomes to any individual component. Hyperbaric oxygen therapy, metabolic optimization, cellular priming, UC-MSC administration, MSC-derived secretome therapy, structured rehabilitation, and evidence-based medical care were delivered within the same clinical program. Accordingly, the independent effects of UC-MSCs or the secretome cannot be determined.

The outcome assessment also had limitations. Even though there was a use of standardized neurological measurements, there were no systemic measures of quantitative upper-extremity testing, instrumented gait assessment, validated sensory testing, wearable mobility monitoring, fatigue-specific measures, cognitive assessment, and quality-of-life instruments. The lack of such practices inhibits more specific characterization of domain-specific recovery.

There was also a lack of objective biological correlates. Serial advanced neuroimaging or circulating biomarkers of inflammation, endothelial performance, neurotrophic signaling, extracellular-vesicle kinetics or immune modulation was not evaluated. The available certificate of analysis provided extracellular-vesicle-associated product

[Downloaded from ijmcmed.org on 2026-11-23]

[DOI: 10.22088/IJMCM.BUMS.15.2.1493]

characterization, including particle size and concentration, EV-associated markers, selected protein and microRNA profiling, and an in vitro potency assessment. However, these data do not permit attribution of the patient's clinical course to extracellular vesicles or exosomes specifically, and the report does not provide a comprehensive independent analysis of all manufacturing variables or lot-to-lot variability.

The longitudinal clinical course was complicated by the recurrent ischemic stroke, which complicated its interpretation. Its association with the regenerative interventions cannot be categorically determined or eradicated and the incident added more confounding to the evaluation of subsequent functional results. Lastly, the six months follow up period was adequate to make short and intermediate clinical observations but not to test long term durability or late safety outcomes.

In general, the case can be viewed as a hypothesis-generating clinical observation of feasibility, longitudinal changes in functional aspects, and safety of treatment instead of evidence of efficacy of treatment. Potential controlled trials, characterized by standardization in the characterization of the products used, multidimensional results, mechanistic measures, and extended follow-up are necessary.

Overall Interpretation

The case report entails the longitudinal clinical history of a patient with chronic post-ischemic stroke who underwent a personalized multimodal regenerative medicine protocol that included intravenous UC-MSC infusion and follow-up MSC-secretome therapy, in addition to secondary stroke prevention and multidisciplinary rehabilitation. Six-month follow-up demonstrated that many functional domains, such as muscle spasticity, ambulatory endurance, balance, gait stability, right upper-extremity sensation, grip strength and patient-reported energy improved, whereas global disability scores did not change significantly. The fact that a recurrent ischemic stroke has happened in the course of follow-up also emphasizes the ambiguity of clinical outcomes and safety in a patient with previously known cerebrovascular disease.

The results are to be taken with care. The observed clinical improvements cannot be ascribed to UC-MSC therapy, MSC-derived secretome therapy, or any other combination of the treatment regimen as no comparator was used and multiple therapeutic modalities were administered concurrently. The clinical course can be an expression of the interaction between the effects of rehabilitation, medical treatment, biological variability, compensatory neuroplasticity, and the experimental regenerative therapies. Based on this, this report justifies the possible feasibility of longitudinal observation in a multimodal clinical program, although not treatment efficacy or superiority. In this context, multidimensional functional evaluation and open reporting of positive results as well as negative clinical incidents are significant.

The main contribution of this case is thus not the demonstration of therapeutic efficacy but a documented clinical experience which can guide future research. Randomized controlled trials with standardized manufacturing and treatment protocols, detailed MSC and secretome characterization, mechanistic biomarkers, advanced neuroimaging, multidimensional functional outcomes, and longer follow-up are needed to determine whether MSC- and secretome-based approaches provide meaningful benefit in chronic ischemic stroke. Until such evidence is available, these interventions should remain investigational adjuncts used alongside, and not in place of, evidence-based stroke management.

This case report describes the six-month clinical course of a patient with chronic post-ischemic stroke who underwent an individualized multimodal regenerative medicine protocol centered on intravenous allogeneic umbilical cord-derived mesenchymal stromal cell (UC-MSC) therapy and subsequent MSC-derived secretome therapy, integrated with evidence-based secondary stroke prevention and multidisciplinary rehabilitation. During longitudinal follow-up, improvements were documented in muscle spasticity, ambulatory endurance, balance, gait stability, right upper-extremity sensation, grip strength, and patient-reported energy, while global neurological disability scores remained largely unchanged.

The occurrence of a recurrent ischemic stroke during follow-up was managed according to contemporary standards of care and was transparently reported as part of the patient's clinical trajectory. A definitive causal relationship between this event and the regenerative interventions cannot be established or excluded from this single case. The observations presented in this report should be interpreted within the

[Downloaded from ijmcmed.org on 2026-11-23]

[DOI: 10.22088/IJMCM.BUMS.15.2.1493]

context of a single-patient, uncontrolled clinical experience. Because UC-MSC therapy and MSC-derived secretome administration were delivered alongside supportive interventions, structured rehabilitation, and conventional medical management, it is not possible to attribute the observed functional improvements to any individual intervention. Therefore, the results cannot be viewed as an indication of curative effectiveness or causal advantage. Instead, they should be regarded as exploratory, hypothesis-generating observations regarding the feasibility, longitudinal functional trajectory, and safety considerations of a multimodal regenerative medicine protocol.

The maintenance of functional independence and changes in selected motor and functional domains highlight the value of multidimensional outcome measures in addition to global disability scales. The case also reinforces that investigational regenerative therapies should complement, rather than replace, evidence-based stroke management, including secondary prevention, cardiovascular risk reduction, and coordinated rehabilitation.

The exact contribution of UC-MSC therapy or MSC-derived secretome cannot be determined in this multimodal setting. In addition, although the available certificate of analysis documented extracellular-vesicle-associated characterization of the secretome preparation, these product-level data do not establish that the observed clinical changes were mediated specifically by extracellular vesicles or exosomes; therefore, no exosome-specific therapeutic mechanism can be inferred from this single case.

Further adequately powered controlled studies using standardized manufacturing procedures, detailed product characterization, standardized treatment protocols, mechanistic biomarkers, advanced neuroimaging, multidimensional functional outcomes, and longer follow-up are needed to determine the safety and clinical effectiveness of MSC- and secretome-based approaches in chronic ischemic stroke. Until stronger evidence is available, these interventions should remain investigational adjuncts used alongside established standards of stroke care.

Care Guideline Compliance

This case report was prepared in accordance with the CARE (Case Report) Guidelines (Riley et al., 2017) (19).

Funding

This case report was prepared in accordance with the CARE Guidelines and underwent institutional review by the SH360 Stem Cell Research Institute on January 12, 2026. All patient information was anonymized to protect confidentiality and privacy. Written informed consent was obtained from the patient prior to treatment and separately for publication of this case report, including the use of anonymized clinical information and images. The patient was informed of the purpose of publication and voluntarily consented to the presentation of his clinical course for scientific and educational purposes.

Acknowledgments

The authors sincerely thank the patient and his family for their trust, participation, and willingness to share this clinical experience for educational and scientific purposes.
The authors also acknowledge the physicians, nurses, and allied health professionals of the Sure Health 360 Center for Regenerative Medicine and Cell Therapy and the SH360 Stem Cell Research Institute for their dedication to patient care, clinical documentation, and longitudinal follow-up.

References

1. Feigin VL, Abate MD, Abate YH, et al. Global, regional, and national burden of stroke and its risk factors, 1990–2021: a systematic analysis for the Global Burden of Disease Study 2021. Lancet Neurol. 2024;23(10):973-1003.
2. Kleindorfer DO, Towfighi A, Chaturvedi S, et al. 2021 guideline for the prevention of stroke in patients with stroke and transient ischemic attack: a guideline from the American Heart Association/American Stroke Association. Stroke. 2021;52(7):e364-467.
3. Winstein CJ, Stein J, Arena R, et al. Guidelines for adult stroke rehabilitation and recovery: a guideline for healthcare professionals from the American Heart Association/American Stroke Association. Stroke. 2016;47(6):e98-169.
4. Dawson J, Bejot Y, Christensen LM, et al. European Stroke Organisation (ESO) guideline on pharmacological interventions for long-term

[Downloaded from ijmcmed.org on 2026-11-23]

[DOI: 10.22088/IJMCM.BUMS.15.2.1493]

secondary prevention after ischaemic stroke or transient ischaemic attack. Eur Stroke J. 2022;7(3):I-XLI.
5. Chung JW, Chang WH, Bang OY, et al. Efficacy and safety of intravenous mesenchymal stem cells for ischemic stroke. Neurology. 2021;96(7):e1012-23.
6. Lee J, Chang WH, Chung JW, et al. Efficacy of intravenous mesenchymal stem cells for motor recovery after ischemic stroke: a neuroimaging study. Stroke. 2022;53(1):20-8.
7. Kudo Y. Allogeneic stem cell therapy for acute ischemic stroke. JAMA Neurol. 2024;81(2):154-62.
8. Hassanein ME, Fayad J, Shabana JA, et al. Efficacy and safety of intravenous mesenchymal stem cells for ischemic stroke patients, a systematic review and meta-analysis. Front Stroke. 2024;2:1339331.
9. Shen Z, Tang X, Zhang Y, et al. Efficacy and safety of mesenchymal stem cell therapies for ischemic stroke: a systematic review and meta-analysis. Stem Cells Transl Med. 2024;13(9):886-97.
10. Huang H, Zhang J, Lin J, et al. Efficacy and safety of mesenchymal stem cells in patients with acute ischemic stroke: a meta-analysis. BMC Neurol. 2024;24(1):48.
11. Pittenger MF, Mackay AM, Beck SC, et al. Multilineage potential of adult human mesenchymal stem cells. Science. 1999;284(5411):143-7.
12. Dominici M, Le Blanc K, Mueller I, et al. Minimal criteria for defining multipotent mesenchymal stromal cells. The International Society for Cellular Therapy position statement. Cytotherapy. 2006;8(4):315-7.
13. Caplan AI. Mesenchymal stem cells: time to change the name! Stem Cells Transl Med. 2017;6(6):1445-51.
14. Pratiwi DI, Alhajlah S, Alawadi A, et al. Mesenchymal stem cells and their extracellular vesicles as emerging therapeutic tools in the treatment of ischemic stroke. Tissue Cell. 2024;87:102320.
15. Farzaneh M, Khoshnam SE. Functional roles of mesenchymal stem cell-derived exosomes in ischemic stroke treatment. Curr Stem Cell Res Ther. 2024;19(1):2-14.
16. Kalluri R, LeBleu VS. The biology, function, and biomedical applications of exosomes. Science. 2020;367(6478):eaau6977.
17. Gnecchi M, Zhang Z, Ni A, et al. Paracrine mechanisms in adult stem cell signaling and therapy. Circ Res. 2008;103(11):1204-19.
18. Li X, Lu L, Min Y, et al. Efficacy and safety of hyperbaric oxygen therapy in acute ischaemic stroke: a systematic review and meta-analysis. BMC Neurol. 2024;24(1):55.
19. Riley D, Barber M, Kienle G, et al. CARE 2013 explanations and elaborations: reporting guidelines for case reports. J Clin Epidemiol. 2017;89:218-35.
20. World Medical Association. World Medical Association Declaration of Helsinki: ethical principles for medical research involving human participants. JAMA. 2025;333(1):71-4. doi:10.1001/jama.2024.21972.

[Downloaded from ijmcmed.org on 2026-11-23]

[DOI: 10.22088/IJMCM.BUMS.15.2.1493]