



ORIGINAL ARTICLE

Cardioprotective Potential of Poppy Seed Oil in Doxorubicin-Mediated Cardiotoxicity: Experimental Evaluation in Rats

Tarique Anwer^{1,2*} , Priyanshi Sharma³ , Ankit Verma⁴ , Abdullah Albaqami⁵ , Mohammad Firoz Alam⁶ , Ali Mohammed Ali Hazazi⁶ , Nawazish Alam⁷ , Dalia Daws⁸ 

1. Department of Public Health, College of Applied Medical Sciences, University of Bisha, Bisha, Saudi Arabia.
2. Health and Humanities Research Center, University of Bisha, P.O. Box 225, Bisha, Saudi Arabia.
3. HIMT College of Pharmacy, Dr. A.P.J Abdul Kalam Technical University (AKTU), Greater Noida; India.
4. Department of Pharmacology, School of Pharmaceutical Education and Research, Jamia Hamdard, New Delhi, India.
5. Department of Medical Laboratory Sciences, College of Applied Medical Sciences, University of Bisha, Bisha, Saudi Arabia.
6. Department of Pharmacology & Toxicology, College of Pharmacy, Jazan University, Jazan, Saudi Arabia.
7. Department of Clinical Pharmacy, Pharmacy Practice Research Unit, College of Pharmacy, Jazan University, Jazan, Saudi Arabia.
8. Pharmacy Department, Jazan University Hospital, Jazan University, Jazan, Saudi Arabia.

ARTICLE INFO

Received: 2025/10/2
Revised: 2025/12/16
Accepted: 2026/02/2

ABSTRACT

Doxorubicin (DOX) is a well-known widely-used chemotherapeutic agent in cancer patients. Clinical findings have revealed its association with cardiotoxicity in patients subjected to prolonged administration. Chronic cardiotoxicity may appear after long treatment, with a cumulative dosage exceeding 500–550 mg/m² being a critical risk factor. Poppy seed oil is rich in antioxidants and polyunsaturated fatty acids demonstrated efficacy in attenuating oxidative stress and modulating inflammatory responses. In this study, we have investigated the cardioprotective potential of poppy seed oil in DOX-induced cardiotoxicity model of Wistar rats. DOX was administered (2.5 mg/kg) on alternate days for 14 days to induce cardiotoxicity in groups 2, 3 and 4 rats. Poppy seed oil in dose of 500 and 1000 mg/kg was administered orally for 14 days to groups 3 and 4 rats. Cardiac injury biochemical markers (CK-MB, LDH and Troponin-I), oxidative stress (MDA, SOD, CAT, GSH, GR and GPx), and inflammatory cytokines (TNF- α , IL-6) were assessed. Additionally, histopathological assessment of cardiac tissue was performed to exhibit structural alterations. The administration of poppy seed oil significantly improved cardiac biochemical markers, diminished oxidative stress, and restored antioxidant enzyme levels in DOX-treated rats. It also mitigated myocardial damage, as evidenced by decreased lipid peroxidation and reduced levels of pro-inflammatory cytokines. Histopathological analysis exhibited significant reduction in myocardial degeneration and inflammatory cell infiltration in the poppy seed oil-treated groups. These findings suggest that poppy seed oil may be used as adjunct therapy to reduce chemotherapy-induced cardiac damage, thus warranting further clinical investigation.

Keywords: Cardiotoxicity, Cytokines, Cardiac damage, Doxorubicin, Poppy seed oil, Oxidative damage

*Corresponding:

Tarique Anwer
Address:
Department of Public Health,
College of Applied Medical
Sciences, University of Bisha,
Bisha, Saudi Arabia
E-mail:
manwr@ub.edu.sa

Cite this article: Anwer T, et al. Cardioprotective Potential of Poppy Seed Oil in Doxorubicin-Mediated Cardiotoxicity: Experimental Evaluation in Rats. International Journal of Molecular and Cellular Medicine. 2026; 15 (1):1158-1170. DOI: 10.22088/IJMCM.BUMS.15.1.1158



Introduction

Doxorubicin (DOX) is one of the commonly used chemotherapeutic drug in the treatment of multiple types of cancer. It belongs to the anthracycline class of antibiotics and was initially detected in the bacteria *Streptomyces peucetius var. caesius* (1). The mechanism of action of the in the induction of cancer by DOX is multifaceted, having principal target as DNA of malignant cells. This damage is especially harmful for proliferating cancerous cells (2, 3). DOX adversely affects myocardial cell's capacity to proliferate and survive. Cardiotoxicity is a significant therapeutic dose-limiting toxicity of doxorubicin (4). Research studies have reported that DOX undergoes redox cycling, in which it switches between quinone and semiquinone forms, producing reactive oxygen species (ROS) such O_2^- and H_2O_2 (5). The cytotoxic effects of these ROS are exacerbated by the oxidative damage they inflict on biological components, including DNA, proteins and lipids (6).

Collectively, these processes cause cell stress responses, such as the activation of p53 and other pro-apoptotic pathways, resulting in programmed cell death (apoptosis) (7, 8). While these pathways are very efficient against cancer cells, they also contribute to the drug toxicity in normal tissues, particularly in the heart by producing ROS and causing mitochondrial dysfunction. These ROS induce oxidative damage to cardiomyocytes by damaging their lipids, proteins, and DNA. The heart is highly susceptible because of its high metabolic activity and compromised antioxidant defense, particularly lowered levels of superoxide dismutase and catalase, as compared to other organs (9). Furthermore, doxorubicin targets the mitochondria, where it binds to cardiolipin, a phospholipid required for mitochondrial function. This binding impairs mitochondrial function, resulting in reduced ATP generation and further exacerbating oxidative stress and energy depletion in cardiomyocyte (10). Several strategies have been developed to overcome or minimize doxorubicin-induced cardiotoxicity, aiming to protect the heart while maintaining the drug anticancer efficacy.

The use of chelating agent like dexrazoxane with doxorubicin exhibits potential to reduce the risk of cardiac toxicity by inhibiting the formation of ROS through binding with free iron in cardiac cell (11). Several biomarkers like LDH, Troponin-I, CK-MB and

Troponin-T have been strongly associated with the cardiac function (12). Their assessment (elevated and reduced level) provides significant information about the health of cardiac tissue. Additionally, antioxidant enzyme like SOD, CAT, GSH, GR & GPx and so on have been associated with antioxidant defence system to neutralize oxidants and prevent the cell from oxidative damage (13).

Researchers have drawn attention towards the natural antioxidant for the management of drugs cardiotoxicity. Several research studies have been conducted to investigate promising candidates that have potential to modulate the oxidants level inside the cell. Khan *et al.* described the mitigating effects of *Rumex vesicarius* leaf extract on catecholamine-triggered cardiotoxic responses. In this study, HPLC analysis of aqueous-methanolic *R. vesicarius* leaf extract has been performed and found that several phytoconstituent like kaempferol, Quercetin, Rutin, Emodin, Catechin, Ferulic acid, Coumarin, p-Coumaric acid and Gallic acid were present. These phytoconstituent has antioxidant capacity and has a potential to modulate cell oxidative stress (14). In the search for potent adjuvants, poppy seed oil is considered on the basis of bioactive constituent present to counteract DOX induced cardiotoxicity.

Poppy seed oil, a vegetable oil derived from the seeds of the *Papaver somniferum* plant, commonly known as the opium poppy. Unlike other derivatives of this plant, such as opium, morphine, or codeine, poppy seed oil is non-narcotic and does not contain psychoactive alkaloids. It is primarily incorporated in the culinary, pharmaceuticals and cosmetic industries owing to its characteristic chemical makeup and beneficial properties. Cold-pressed poppy seed oil possesses desirable organoleptic properties, including a light-yellow coloration and a pleasant taste and smell, substantiating its potential as an edible oil. The abundance of several bioactive molecules, like as phytosterols, phospholipids, tocopherols, phenolic substances, and pigments (e.g., carotenoids and chlorophylls)—has been documented in recent research (15). Research outcomes of animal studies suggest that poppy seed oil exhibit antioxidant potential in the hippocampus region after ischemia-reperfusion brain injury (16). Several research studies on other pharmacological potential also indicates that poppy seed oil is a potential candidate to mitigate the tissue damaged by ROS. So, this study was designed to

investigate the potential cardioprotective role of poppy seed oil in mitigating DOX-induced cardiotoxic effect in Wistar rats.

Methods

Animal Procurement

Wistar male rats (4–5-week-old) weighing between 200 and 220g were acquired from the CAHF, AIIMS, New Delhi subsequent to the approval of the study protocol by IAEC of the College and CCSEA, India (2024/HIMT/IAEC/FB/011). Animals were quarantine under 12 hr day/night cycle for 7 days within the temperature 25–27 °C with the availability of commercially standard A-grade feed and tap water *ad libitum* throughout the study period. All the tests were performed in accordance with CCSEA guideline. Animals were monitored daily for signs of distress, changes in feeding/weight, abnormal posture, or inactivity. Any animal exhibiting severe or persistent distress, >20% weight loss, or the inability to access food/water could have been humanely euthanized, although no such events occurred during the study.

Drug and Chemicals

Poppy seed oil was purchased from the Arian enterprises Pvt Ltd, New Delhi, whereas doxorubicin was gift sample from Alkem Pharmaceuticals Pvt Ltd, Mumbai, India. Anti-inflammatory, cardiac markers and apoptotic markers assay kits were purchased from Elabscience & ELK Biotechnology, USA. Additional chemicals used in the study were sourced from ISO-certified suppliers and met analytical grade standards.

Study Design

The study design comprised of 5 group consisting of 7 animals that were placed in each group. Group 1 (Normal control): Received normal saline (1 ml/kg, orally) for 14 days. Group 2 (DOX-control): Received DOX 2.5 mg/kg i.p. for 14 days alternatively to induce cardiotoxicity (17). Group 3 (Poppy seed oil treatment 1 + DOX-treated): Received poppy seed oil in the dosage of 500 mg/kg p.o. followed by DOX treatment alternatively for 14 days. Group 4 (Poppy seed oil treatment 2 + DOX-treated): Received poppy seed oil in the dosage of 1000 mg/kg p.o. followed by DOX alternatively for 14 days (18). Group 5 (Poppy seed oil only): Received only poppy seed oil in the dosage of 1000 mg/kg p.o. for 14 days.

Poppy seed oil emulsion was prepared by using emulsifying agent (Acacia gum 5% w/v) and administered orally for 14 days. The body weight of all the animals was taken every three days. The rats were anesthetized on day 15 by giving thiopental injection (40 mg/kg, i.p.) in order to obtain blood sample by exsanguination. The collected blood was subjected to centrifugation at 3000 rpm for 15 minutes and the supernatant serum was collected. The serum obtained was employed to assess the cardiac injury markers (CK-MB, LDH, and Troponin-I) in conjunction with inflammatory cytokines like tumor necrosis factor- α and interleukins (TNF- α , IL-6, and IL-1 β) and apoptotic indices (caspase-3 and 9). After that, all the animal were scarified and heart of all the animals from each group were excised and cleaned with distilled water. One heart from each group was kept in 10% formalin for fixation and further histopathological studies. The remaining hearts were subjected to prepare tissue homogenate for further biochemical estimation.

Tissue Homogenate Preparation

After sacrifice, heart tissues were excised, rinsed in ice-cold saline, blotted on filter paper and weighed. Whole tissue (typically ~2–2.5 g) was homogenized in 20 mL of ice-cold phosphate buffer (50 mM, pH 7.4). The tissue underwent homogenization in the initial stage using a homogenizer and then subjected to centrifugation at 800–1000 \times g for 5 minutes at 4°C. The subsequent supernatant was stored in a new tube for the determination of lipid peroxidation (LPO). The leftover supernatant underwent to a final phase of centrifugation at 10,500 \times g for 15 minutes at 4 °C to get the post-mitochondrial supernatant (PMS). The PMS was later used to measure the amounts of antioxidant indicators such as reduced glutathione (GSH), glutathione reductase (GR), glutathione peroxidase (GPx), superoxide dismutase (SOD) and catalase (CAT).

Oxidative Stress Markers

The protein content of the samples was measured using the Lowry et al. technique (19), which is an important parameter in the estimate of oxidative stress markers. LPO test was performed to assess the MDA content using Ohkawa et al. technique (20). We have used method of Jollow et al. to estimate GSH (21), whereas Mohandas et al. methodology was used to estimate GPx and GR (22). The method of Claiborne

was used to assess CAT, while the Marklund approach was used to determine SOD activity (23, 24). All enzyme activities and oxidative stress markers were normalized to protein content and are reported as units per mg protein (U/mg protein) protein as specified below.

Cardiac Serum Markers

Diagnostic assay kits (True chemie (CK-MB), Elabscience (LDH and Troponin I)) with manufacturer proposed procedure was used to estimate the serum concentrations of cardiac markers, including LDH, Troponin-I, and CK-MB.

Inflammatory Cytokines Markers

ELISA kits were used to quantify inflammatory markers (TNF- α , IL-6, and IL-1 β) as per the manufacturer's protocol.

Apoptotic Markers

Apoptosis-related markers, namely Caspase-3 and Caspase-9 were assessed through the diagnostic ELISA kit as per the information provided by the manufacturer.

Histopathological Assessment

One heart from each group was excised immediately after sacrifice, washed in cold saline, and fixed in 10% neutral-buffered formalin (NBF) for 24–48 hours. Following fixation, tissues were routinely processed, dehydrated through graded ethanol, cleared in xylene, and embedded in paraffin blocks. Paraffin-embedded hearts were sectioned at a thickness of 4–5 μ m using a rotary microtome and mounted on glass slides.

Sections were stained with hematoxylin and eosin (H&E) following standard histological procedures (hematoxylin staining for 5–7 min, differentiation, bluing, eosin staining for 1–2 min).

Statistical Analysis

The results of all parameters were collected and analyzed by one way ANOVA followed by Tukey's pots hoc using GraphPad Prism to establish statistical significance. All data are presented as mean \pm SEM. The means of each group was compared with other groups and the p-value of less than 0.05 were presumed to be statistically significant.

Results

Oxidative Stress Markers

MDA level

Table 1 represents MDA levels in the cardiac tissue homogenate of all group animals. Group-2 exhibits elevated MDA level when compared to group-1. Group-3 and 4 where poppy seed oil was given in 500 mg/kg & 1000 mg/kg dose showed significant decrease in MDA levels relative to group-2. The reduced MDA level suggests a graded protective response proportional to the dose of poppy seed oil against DOX induced cardiac tissue damage. Group-5, where only poppy seed oil at maximum dose of 1000 mg/kg was administered showed no distinct variation in MDA level as compared to group-1, establishing its safety to use at this dose.

SOD, CAT, GSH, GR & GPx level

Table 1 represents antioxidant enzyme levels. DOX treated group-2 animals indicate reduced the levels of antioxidant enzymes in the heart tissue homogenate compared to group-1. However, the poppy seed oil treatment in group-3 and 4 at doses of 500 mg/kg & 1000 mg/kg confirmed elevation in SOD, CAT, GSH, GR & GPx levels when compared it with group-2, suggesting a dose-dependent protective effect. When higher dose of poppy seed oil was given (1000 mg/kg) to group 5 animals, indicates normal levels of these antioxidant enzymes relative to group-1.

Table 1. Poppy seed oil ameliorated antioxidative enzymes level in DOX-induced cardiotoxicity in rats.

Parameters	Group-1	Group-2	Group-3	Group-4	Group-5
MDA	409.60 \pm 16.35	807.4 \pm 12.49****	717 \pm 14.54###	535.33 \pm 10.25####	438 \pm 13.47 ns
SOD	90.48 \pm 2.58	44.17 \pm 1.45****	55.45 \pm 0.93###	75.41 \pm 1.37####	85.14 \pm 2.34 ns

Parameters	Group-1	Group-2	Group-3	Group-4	Group-5
CAT	520.6±28.29	167.7±13.61****	267.4±14.41###	313.8±24.90####	448.2±15.2 ns
GSH	55.96±2.25	24.55±1.43****	34.43±1.08###	43.06±1.02####	52.29±1.94 ns
GR	1335.9±33	810±20.22****	1005.6±25###	1136.03±28####	1287.45±23 ns
GPx	115.64±4.78	51.98±7.35****	88.78±7.88##	105.89±4.40####	108.89±3.74 ns

Results showing quantitative data of SOD, CAT, GSH, GR and GPx (**** $p < 0.0001$ compared to group-1, #### $p < 0.0001$, ### $p < 0.001$, ## $p < 0.01$ compared to group-2, $^{ns}p > 0.05$ compared to group-1)

Cardiac Markers Level

CK-MB level

The levels of CK-MB in the serum of all groups are presented in figure 1. Group-2 showed significantly elevated level of CK-MB upon equated to group-1. Following the administration of poppy oil at doses 500 mg/kg & 1000 mg/kg to group-3 and 4 animals showed reduction in CK-MB level upon equated to group-2. When the higher dose of poppy seed oil was given (1000 mg/kg) to group 5 animals, showed no notable change in CK-MB level compared to group-1, establishing its safety to use at this dose.

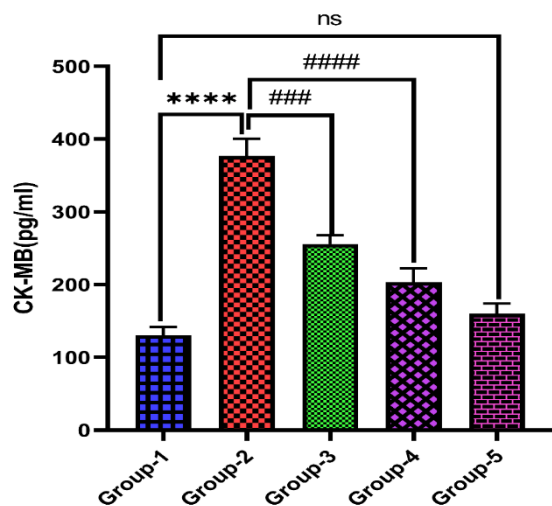


Figure 1. Represent CK-MB level (** $p < 0.0001$ compared to group-1; #### $p < 0.0001$, ### $p < 0.001$ compared to group-2; $^{ns}p > 0.05$ compared to group-1).**

LDH level

The levels of LDH in the serum of all groups are presented in figure 2. The LDH level in group-2 animals was found to be significantly elevated upon equated to group-1. Following administration of poppy oil at doses 500 mg/kg & 1000 mg/kg to group-3 and 4 animals showed reduction in LDH level upon equated to group-2. When the higher dose of poppy seed oil was given (1000 mg/kg) to group 5 animals, showed no notable change in LDH level compared to group-1, demonstrating its safety to use at this dose.

animals showed reduction in LDH level upon equated to group-2.

When the higher dose of poppy seed oil was given (1000 mg/kg) to group 5 animals, showed no notable change in LDH level upon equated to group-1, demonstrating its safety to use at this dose

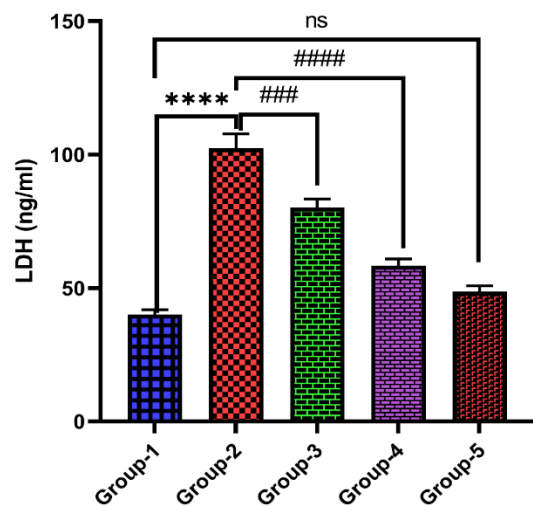


Figure 2. Represent LDH level (** $p < 0.0001$ compared to group-1; #### $p < 0.0001$, ### $p < 0.001$ compared to group-2; $^{ns}p > 0.05$ compared to group-1).**

Cardiac Troponin-I level

Figure 3 represents serum cTnI levels of all group animals. A significant increase in cTnI levels was observed in group-2 relative to group-1.

Following the administration of poppy oil at doses 500 mg/kg & 1000 mg/kg to group-3 and 4 animals revealed marked reduction in cTnI level relative to group-2. When the higher dose of poppy seed oil was given (1000 mg/kg) to group 5 animals, shows non-significant change in cTnI level when relative to group-1, demonstrating that this dose can be safely used.

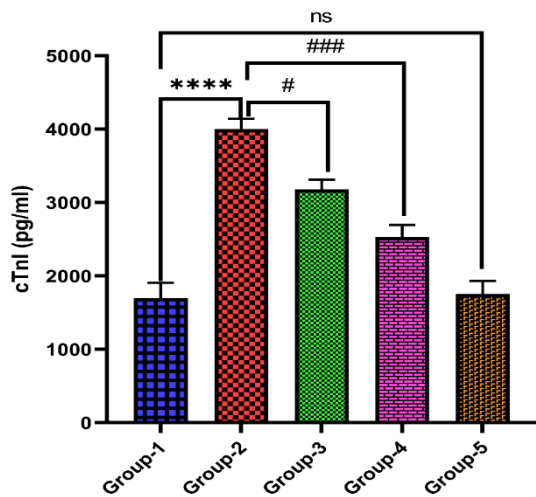


Figure 3. Represent Troponin-I level (**** $p < 0.0001$ compared to group-1; # $p < 0.05$, ### $p < 0.001$ compared to group-2; $ns > 0.05$ compared to group-1).

Inflammatory Cytokines Markers

TNF- α level

The levels of TNF- α in the serum of all group animals are presented in Figure 4. Group-2 in which doxorubicin was given showed elevated TNF- α level relative to group-1. Groups-3 and 4 where poppy oil was given at 500 mg/kg & 1000 mg/kg doses exhibited reduction in TNF- α level relative to group-2. When the higher dose of poppy seed oil was given (1000 mg/kg) to group 5 animals, showed non-significant change in TNF- α level when related to group-1, demonstrating that this dose could be safely used.

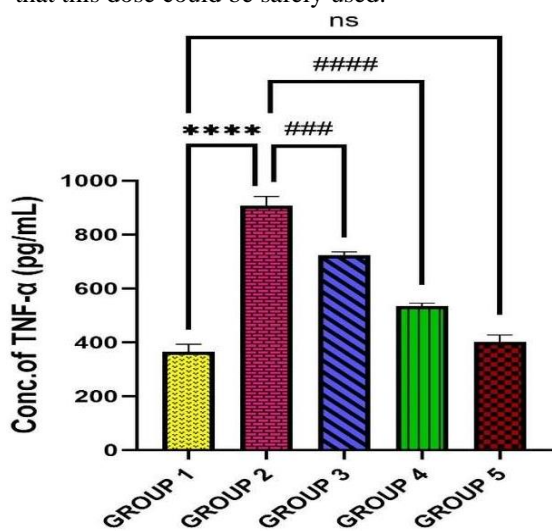


Figure 4. Represent TNF- α level (**** $p < 0.0001$ compared to group-1; ##### $p < 0.0001$, ### $p < 0.001$ compared to group-2; $ns > 0.05$ compared to group-1).

IL-6 level

Figure 5 represents IL-6 levels in the serum of all group animals. Group-2 where DOX was given at exhibited elevation in IL-6 level when compared to group-1. Groups-3 and 4 where poppy seed oil was given 500 mg/kg & 1000 mg/kg doses showed reduction in IL-6 level when compared with group-2. The reduced IL-6 levels suggested a dose-dependent protective effect of poppy seed oil against DOX induced cardiotoxicity. Group-5 where only poppy seed oil was given at 1000 mg/kg dose did not show any notable change in IL-6 level when compared with group-1.

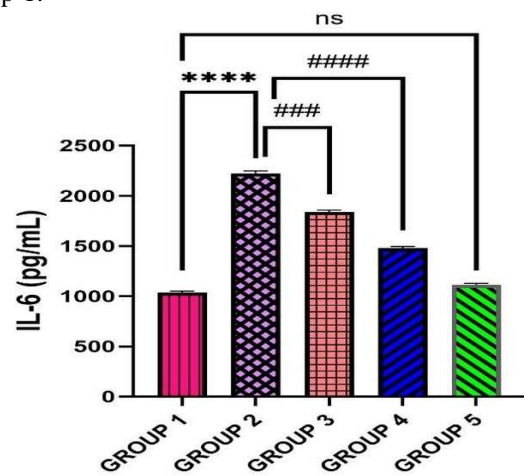


Figure 5. Represent IL-6 level (**** $p < 0.0001$ compared to group-1; ##### $p < 0.0001$, ### $p < 0.001$ compared to group-2; $ns > 0.05$ compared to group-1).

IL-1 β level

Figure 6 represents IL-1 β levels of all group animals.

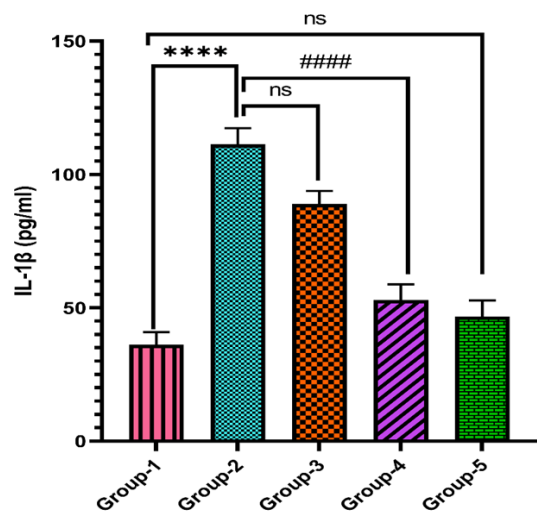


Figure 6. Represent IL-1 β level. (**** $p < 0.0001$ compared to group-1; ##### $p < 0.0001$, $ns > 0.05$ compared to group-2; $ns > 0.05$ compared to group-1).

DOX-treated group 2 exhibited elevation in IL-1 β level in comparison to group-1. Poppy seed oil treated groups 3 and 4 showed reductions in IL-1 β level in comparison group-2. The reduced IL-1 β levels suggest a dose-dependent protective effect of poppy seed oil against DOX induced cardiotoxicity. Group-5 where only poppy seed oil at 1000 mg/kg was administered did not show any notable changes in IL-1 β level in comparison to group-1.

Apoptotic Markers

Caspase-3 & 9 level

Figures 7 and 8 represent caspase-3 & 9 levels of all group animals. DOX-treated group-2 exhibited elevation in both apoptotic markers level when it is compared to group-1. Poppy seed oil treated groups 3 and 4 demonstrated reduction in level of caspase-3 & 9 in comparison to group-2.

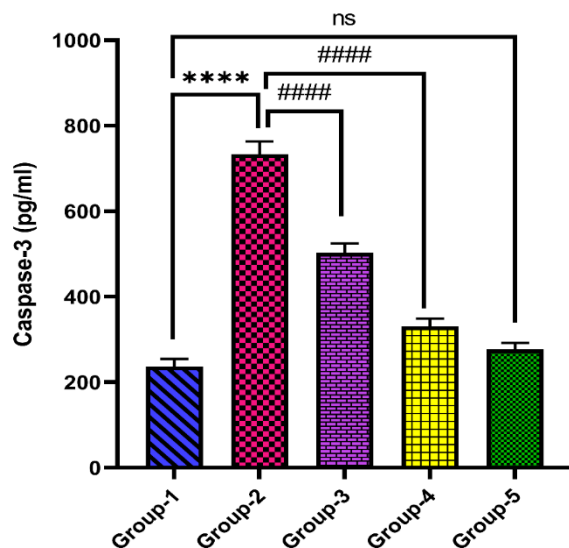


Figure 7. Represent caspase-3 level (**** $p < 0.0001$ compared to group-1; ##### $p < 0.0001$, compared to group-2; $^{ns}p > 0.05$ compared to group-1).

The reduced level of apoptotic markers suggests a dose-dependent protective effect of poppy seed oil against DOX induced cardiotoxicity. Group-5, where only poppy seed oil at 1000 mg/kg was administered did not show any notable change in the levels of caspase in comparison to group-1.

Histopathological Analysis

Figure 9 represents histopathological analysis of cardiac tissue of all group animals. Group-1 shows normal cardiomyocytes with normal structure of cardiac tissue.

Group 2, where DOX was administered signify changes in the shape of cardiomyocytes such as foci of

cardiomyocytes with pronounced vacuolization of cytoplasm and haemorrhages at the site of necrosis and inflammation. Loss of myocytes indicated by yellow circle mark. Administration of poppy seed oil to groups 3 (500 mg/kg) and group 4 (1000 mg/kg) restored the degenerative changes in the cardiac tissue.

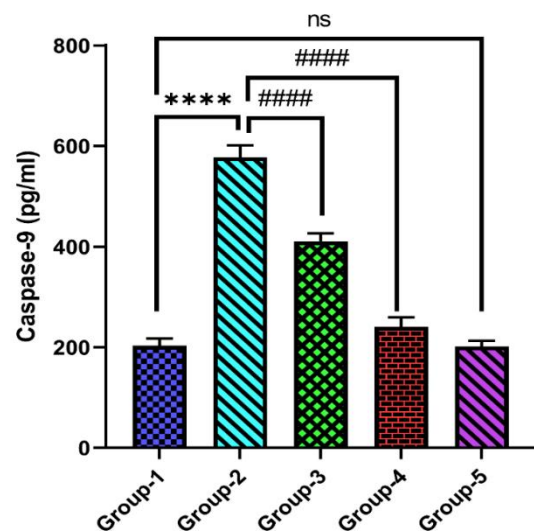


Figure 8. Represent caspase-9 level (**** $p < 0.0001$ compared to group-1; ##### $p < 0.0001$, $^{###}p < 0.001$ compared to group-2; $^{ns}p > 0.05$ compared to group-1).

Discussion

Doxorubicin classified as an anthracycline antibiotic, is widely administered in chemotherapy protocols for a variety of cancers, including leukaemia, breast cancer and lymphomas. Despite its potent antitumor activity, DOX's clinical utility is limited due to its significant toxicity, particularly its cardiotoxic effects. DOX intercalates into the base pair region of the DNA helix, which is one of its key mechanisms. This intercalation distorts the native structure of DNA, thereby interrupting transcription and replication processes necessary for protein synthesis and cell division. Furthermore, DOX inhibits topoisomerase II, an enzyme necessary to reduce supercoiling during replication of DNA. They interference with the rejoining of cleaved DNA strands resulting in the DNA strand breakage accumulation. Previous studies have demonstrated the basic processes of DOX-induced toxicity and oxidative stress, validating both its beneficial side effects and therapeutic usefulness (25). Lefrak et al., found that the risk of congestive heart failure increases significantly as the total dose of doxorubicin given to a patient goes beyond 550 mg/m².

At doses between 500 and 550 mg/m², only 4% experienced heart failure. When the dose increased slightly to between 551 and 600 mg/m², the risk jumped to 18%. At doses of 601 mg/m² or more, the

risk rose dramatically to 36% (26). Other experimental and clinical findings have substantiated these findings, identifying cumulative anthracycline exposure as a principal determinant of cardiotoxic risk (27).

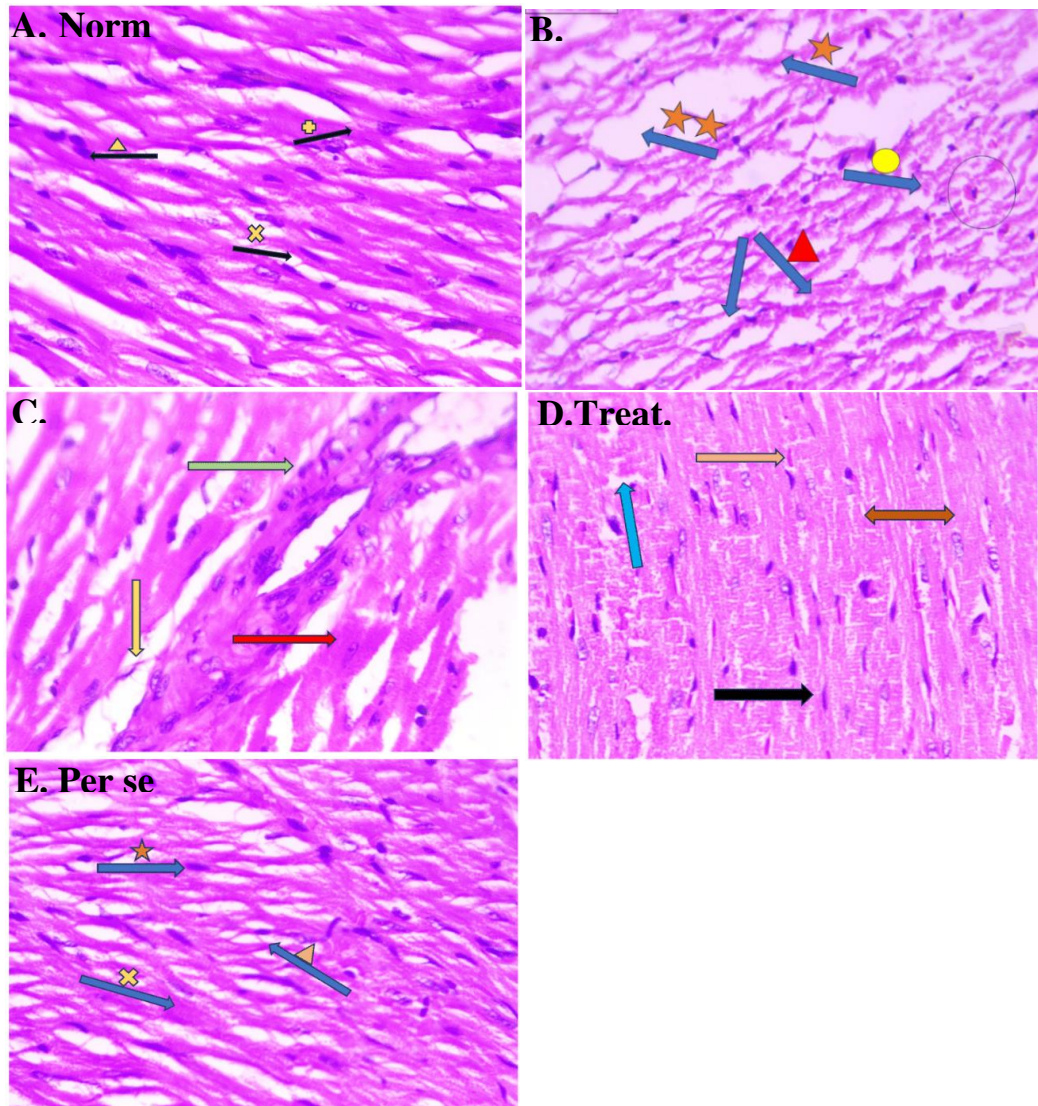


Figure 9. Represent histopathological analysis of heart tissue.

Group-1 (A) shows normal cardiomyocytes (rods like unit) denoted by yellow triangle. Myofibrils (filaments) shown by yellow x mark and striated, branched cardiac muscle indicated by plus sign. Group-2 (B) shows cardiomyopathy (changes in the shape of cardiomyocytes i.e. foci of cardiomyocytes with pronounced vacuolization of cytoplasm & haemorrhages at the site of necrosis) shown by single orange star mark. Loss of myocytes indicated by yellow circle mark. Denaturing of cardiac muscle cell and the connective tissue that's surrounds these cells represent by brown colour triangle with two arrows. edema shown by two stars with yellow colour & inflammatory cells indicated in circle. Group-3 (C) Loss of myocytes are seen comparatively less infiltration macrophages seen represent by green colour arrow. Cellular debris are clean and provisional Matrix is formed indicated by yellow arrow. Reestablishment of affected tissue and organ is observed shown by red colour arrow. Group-4 (D) Rebranching of cardiac muscle can be seen indicated by black colour arrow. Mild oedematous cells are seen represent by blue arrow. Reduced inflammation leads to regain shape of cardiomyocytes shown by orange arrow. Chemokines (CXCL1, CCL2, CXCL12) gets suppressed by angiogenic factors which leads to decreases necrosis and apoptosis of the cells shown by two-way arrow. Group-5 (E) Showing normal cardiomyocytes (orange star) As like normal myofibrils (cross yellow sign) & showing striated, branched cardiac muscle (yellow triangle).

Linder et al., describes data long-term cardiac adverse effects of cancer therapies are becoming more noticeable in 12 million cancer patients who have been effectively treated. Between 1 to 5% exhibit evidence of cancer therapy-related cardiac dysfunction (CTRCD), and 20% of these individuals have asymptomatic LV function decrease (4). The predominant mode of action is attributed to the production of ROS during the drug redox cycle. Recent studies have explored the complex mechanisms involved in DOX-induced toxicity, emphasizing that regulation of autophagy may be a promising strategy to mitigate its cardiotoxic effect (28).

Zeng et al. explored the mechanistic basis of curcumin's cardioprotective action against FFA-induced myocardial injury through modulation of oxidative stress and inflammatory pathways (Nrf2 and NF- κ B) in cellular and animal model. In this study, H9C2 cardiomyoblasts subjected to palmitate exhibited enhanced ROS production, inflammatory signalling, apoptosis, and hypertrophy, indicative of cardiotoxic stress. Curcumin treatment effectively suppressed these increased markers (29). Mesquita *et al.* elucidated the cardioprotective mechanisms of Ginkgo biloba extract (GBE) in the context of prolonged β -adrenergic stimulation, with a focus on the involvement of M2 muscarinic receptors and NO-mediated pathways. In this study, GBE treatment (100 mg/kg/day) was found to counteract the autonomic dysregulation and baroreflex impairment caused by prolonged β -adrenergic receptor activation (4.5 mg/kg/day) (30).

Similarly, another research study has evaluated the ability of antioxidants such as resveratrol and curcumin to mitigate the oxidative damage caused by DOX (31). The outcome of this study revealed that these bioactive compounds reduced ROS levels and enhanced mitochondrial activity, thereby attenuating DOX-induced cardiotoxicity. In our previous two research studies we have investigated that telmisartan and green tea extract demonstrated insightful protective benefits against DOX-induced cardiotoxicity (6, 8). Furthermore, there has been increasing interest in the discovery and development of DOX analogue and advanced drug delivery systems to reduce toxicity. Research studies have proven that liposomal formulation of DOX significantly reduces cardiotoxicity without diminishing its anticancer potential (32).

Further investigation of natural products and bioactive compounds is necessary to mitigate the adverse effects of DOX while enhancing its anticancer potential. Poppy seed oil is noted for its rich composition of bioactive chemicals, demonstrates considerable antioxidant action, mostly owing to its tocopherol (vitamin E) and phenolic content (33). A proven antioxidant, vitamin E protects cells from oxidative stress brought on by free radicals (34). Poppy seed oil's antioxidant properties are essential for lowering oxidative stress, which is a major contributor to the development and course of chronic illnesses including cardiovascular disease. Poppy seed oil's phenolic contents, which may neutralize free radicals, lower inflammation, and shield cells from oxidative damage, further enhance its antioxidant qualities (35).

This research's main goal was to assess poppy seed oil's possible therapeutic benefits in reducing DOX-induced cardiac injury prior to DOX treatment. Evaluation of blood cardiac biomarkers, including troponin, CK-MB, and LDH. To detect heart toxicity, I provided vital clinical practice insights. Doxorubicin is known to cause cardiotoxicity, as seen by increased CK-MB and LDH values. Prior research studies have reported that DOX treatment resulted in elevated levels of LDH and CK-MB (34, 35). In our research study we found significant increase in LDH and CK-MB activity following DOX treatment. This rise in LDH and CK-MB levels indicated cardiac cell injury caused by DOX; this could potentially was caused by overproduction of free radicals and lipid peroxides.

The administration of poppy seed oil at two different doses effectively attenuated the increased levels of LDH and CK-MB, reflecting a dose-dependent effect. However, the higher dose (treatment control 2) was more effective in reducing LDH and CK-MB levels, suggesting better protection against doxorubicin-induced cardiac injury. Troponin I is also a specific marker for cardiac injury. In this study, doxorubicin-treated animals showed lower levels of troponin I. Troponin I levels, on the other hand, increased significantly after treatment with both dosages of poppy seed oil, with the higher dose (treatment group 2) exhibiting a more noticeable increase. This implies that the increased dosage of poppy seed oil may aid in the heart repair processes in addition to offering protection against cardiac damage.

Reactive oxygen intermediates produced during metabolism is one of the main mechanisms of DOX-

induced cardiotoxicity. Redox cycling occurs in cells when DOX's quinone structure is reduced to a semiquinone radical, which then reacts with molecular oxygen to produce superoxide anions ($O_2^{\cdot-}$). The hydroxyl ion (OH^{\cdot}) and hydrogen peroxide (H_2O_2), which are precursors of these superoxide's, have the capacity to cause significant oxidative damage to biological components such as proteins, lipids, and genetic material (36). The heart's naturally low levels of antioxidant enzymes like catalase and superoxide dismutase make it particularly susceptible to doxorubicin-mediated oxidative stress. The susceptibility of cardiac tissue is further influenced by its high metabolic activity and dependence on the activity of mitochondria.

The accumulation of ROS produced by DOX in the mitochondria results in mitochondrial malfunction, permeabilization of the mitochondrial membrane by mPTP opening, and the eventual death of cardiomyocytes. One of the main causes of DOX-induced cardiomyopathy, which may lead to heart failure, is oxidative stress (37, 38). To evaluate the antioxidant potential of poppy seed oil in DOX-induced cardiotoxic mice, the research assessed a number of oxidative stress indicators, such as glutathione reduced (GSH), superoxide dismutase (SOD), catalase (CAT), glutathione reductase (GR), and malondialdehyde (MDA). Lipid peroxidation is measured by MDA, which was markedly increased when DOX was administered, indicating oxidative damage. MDA levels were significantly lower in both groups treated with poppy seed oil than in the group treated with DOX. On the other hand, MDA levels decreased more in treatment control 2 (a larger dosage of poppy seed oil), suggesting that it was more effective in preventing oxidative stress. While GR aids in maintaining the equilibrium of reduced and oxidized glutathione, GSH is a vital antioxidant that shields our cells from oxidative damage (39).

For cells to protect themselves against oxidative stress, both are essential. When poppy seed oil was administered to both treatment control groups, GSH, GPx, and GR levels increased, but the DOX-treated group showed a significant decrease in these parameters. GSH and GR levels significantly increased in treatment control 2 (higher dosage of poppy seed oil), highlighting the greater dose of poppy seed oil's improved antioxidant action. Superoxide radicals must be neutralized by SOD, and oxidative

damage may be avoided using catalase to break down hydrogen peroxide into oxygen and water. Both SOD and CAT levels were much lower in the DOX-treated control group. According to this research, poppy seed oil treatment raised the levels of both antioxidant enzymes. The idea that a greater dosage of poppy seed oil provides better protection against oxidative stress and more effectively strengthens the antioxidant defence system is further supported by the fact that treatment control 2 was more successful in restoring SOD and CAT levels.

Alongside cellular oxidative stress, the activation of inflammatory pathways plays a crucial role in the pathophysiology of drug-induced cardiotoxicity. It was reported that DOX generates reactive oxygen species (ROS), which subsequently induces oxidative stress within the cell (40). High ROS production may damage cellular components and activate nuclear factor kappa B (NF- κ B), a transcriptional regulator of inflammation. NF- κ B activation encourages an inflammatory response by increasing the production of pro-inflammatory cytokines including IL-6 & TNF- α & IL-1 β . These pro-inflammatory cytokines promote inflammation and tissue damage by recruiting immune cells (like neutrophils) to the site of injury (41).

It also increases the permeability of blood vessels, allowing further infiltration of immune cells into the cardiac tissue. The anti-inflammatory potential of poppy seed oil was assessed by measuring these cytokines level in serum. Diseased control group where DOX was administered showed increase in the level of these cytokines. The lower dose of poppy seed showed a remarked reduction in cytokines level, while the higher dose of poppy seed oil showed significant decrease in these cytokines level. This result suggests that the higher dose of poppy seed oil is more effective in mitigating inflammatory cytokines level. In addition to the inflammatory cytokine activation, apoptotic pathway activation also plays an important role in cell death by activating apoptotic caspases such as caspase-9 and caspase 3.

These caspases are important in the apoptotic signalling cascade which is responsible for programmed cell death. Apoptosis is tightly regulated process that preserves tissue homeostasis by removing damaged or harmful cells. Both caspases belong to the cysteine-aspartic protease family involved in controlled cellular disintegration. When mitochondrial stress occurs, pro-apoptotic Bcl-2 family members

such as Bax and Bak break the mitochondrial outer membrane, releasing cytochrome c into the cytosol. Cytochrome C, together with dATP, binds to apoptotic protease activating factor-1 (Apaf-1), generating a heptameric complex known as the apoptosome. The apoptosome recruits procaspase-9, facilitating its dimerization and autoactivation. Activated caspase-9 cleaves and activates downstream executioner caspases, primarily caspase-3, initiating the apoptotic execution phase. A recent research study has reported that Aegelin (a natural alkaloid derived from *Aegle marmelos*) significantly modulates DOX-induced liver damage by targeting oxidative stress, caspase and NF- κ B mediated cellular events (42).

Our study findings revealed that DOX treated group-2 had elevated levels of these apoptotic markers, which clearly indicates that DOX administration leads to apoptosis of cardiac cell. While group-3 and 4 (treatment groups) demonstrated marked reduction in caspase-3 and 9 levels that clearly indicates antiapoptotic potential of poppy seed oil.

The histopathological examination of a rat's heart showed notable variations between the treatment, diseased and normal groups. The cardiac tissue in the normal group has intact myofibrils, well-organised, striated muscle fibres, and normal cardiomyocytes. With vacuolization, myocyte loss, necrosis and inflammation, the diseased group (DOX-treated) exhibits cardiomyopathy, a sign of significant heart injury. Early phases of tissue healing are indicated by treatment group 1 showing decreased myocyte loss, decreased inflammation and the development of a provisional matrix. With restored cardiomyocyte structure, decreased edema and re-branching of the heart muscle, treatment group 2 exhibits even greater recovery. Similar to the normal group, the per se group, which received solely poppy seed oil, has normal cardiomyocytes with intact myofibrils.

The outcome of this study provides persuasive evidence that poppy seed oil possesses significant cardioprotective potential against DOX-induced cardiotoxicity in experimental animals. Poppy seed oil administration effectively attenuated elevated levels of cardiac biomarkers, oxidative stress, lipid peroxidation and inflammatory cytokines as well as improved myocardial antioxidant enzyme levels. It also mitigated histopathological alterations in the cardiac tissue. The cardioprotective potential demonstrated by poppy seed oil is likely attributed to the rich composition of

polyunsaturated fatty acids, antioxidants, and several other bioactive compounds. This study emphasizes the therapeutic potential of poppy seed oil as a natural, dietary intervention to alleviate cardiotoxic effects associated with doxorubicin. Further clinical studies are required to explore its translational application and elucidate the molecular pathways involved. Incorporating poppy seed oil into preventive or adjunctive strategies may hold promise in improving cardiac health during cancer treatment.

Supplementary Materials: The corresponding author shall furnish the raw data in an Excel spreadsheet format together with analytical results obtained from GraphPad prism software, contingent upon a personal request.

Acknowledgement

The authors are thankful to the Deanship of Graduate Studies and Scientific Research at University of Bisha for supporting this work through the Fast-Track Research Support Program

References

1. Akhtar N, Khan RA. Liposomal systems as viable drug delivery technology for skin cancer sites with an outlook on lipid-based delivery vehicles and diagnostic imaging inputs for skin conditions'. *Prog Lipid Res.* 2016;64:192-230.
2. Thorn CF, Oshiro C, Marsh S, et al. Doxorubicin pathways: pharmacodynamics and adverse effects. *Pharmacogenet Genomics.* 2011;21(7):440-6.
3. Tacar O, Sriamornsak P, Dass CR. Doxorubicin: an update on anticancer molecular action, toxicity and novel drug delivery systems. *J Pharm Pharmacol.* 2013;65(2):157-70.
4. Linders AN, Dias IB, Lopez Fernandez T, et al. A review of the pathophysiological mechanisms of doxorubicin-induced cardiotoxicity and aging. *NPJ Aging.* 2024;10(1):9.
5. Kong CY, Guo Z, Song P, et al. Underlying the Mechanisms of Doxorubicin-Induced Acute Cardiotoxicity: Oxidative Stress and Cell Death. *Int J Biol Sci.* 2022;18(2):760-70.
6. Iqbal M, Dubey K, Anwer T, et al. Protective effects of telmisartan against acute doxorubicin-induced cardiotoxicity in rats. *Pharmacol Rep.* 2008;60(3):382-90.

7. Aubrey BJ, Kelly GL, Janic A, et al. How does p53 induce apoptosis and how does this relate to p53-mediated tumour suppression? *Cell Death Differ.* 2018;25(1):104-13.
8. Alam MF, Khan G, Safhi MM, et al. Thymoquinone Ameliorates Doxorubicin-Induced Cardiotoxicity in Swiss Albino Mice by Modulating Oxidative Damage and Cellular Inflammation. *Cardiol Res Pract.* 2018;2018:1483041.
9. D'Oria R, Schipani R, Leonardini A, et al. The Role of Oxidative Stress in Cardiac Disease: From Physiological Response to Injury Factor. *Oxid Med Cell Longev.* 2020;2020:5732956.
10. Wu BB, Leung KT, Poon EN. Mitochondrial-Targeted Therapy for Doxorubicin-Induced Cardiotoxicity. *Int J Mol Sci.* 2022;23(3).
11. Lebrecht D, Geist A, Ketelsen UP, et al. Dexrazoxane prevents doxorubicin-induced long-term cardiotoxicity and protects myocardial mitochondria from genetic and functional lesions in rats. *Br J Pharmacol.* 2007;151(6):771-8.
12. Jacob R, Khan M. Cardiac Biomarkers: What Is and What Can Be. *Indian J Cardiovasc Dis Women WINCARS.* 2018;3(4):240-4.
13. Jomova K, Alomar SY, Alwasel SH, et al. Several lines of antioxidant defense against oxidative stress: antioxidant enzymes, nanomaterials with multiple enzyme-mimicking activities, and low-molecular-weight antioxidants. *Arch Toxicol.* 2024;98(5):1323-67.
14. Saqib F, Ali A, Ahmedah HT, et al. Cardioprotective, hypotensive and toxicological studies of *Populus ciliata* (Wall. ex Royle). *Biomed Pharmacother.* 2021;142:112065.
15. Melo D, Alvarez-Orti M, Nunes MA, et al. Nutritional and Chemical Characterization of Poppy Seeds, Cold-Pressed Oil, and Cake: Poppy Cake as a High-Fibre and High-Protein Ingredient for Novel Food Production. *Foods.* 2022;11(19).
16. Gupcso K, Kokai Z, Balint M, et al. Studies on Sensory and Phytochemical Characteristics of Poppy (*Papaver somniferum* L.) Varieties for Their Oil Utilisation. *Foods.* 2023;12(17).
17. Dulf PL, Coada CA, Florea A, et al. Mitigating Doxorubicin-Induced Cardiotoxicity through Quercetin Intervention: An Experimental Study in Rats. *Antioxidants (Basel).* 2024;13(9).
18. Nomier Y, Khuwaja G, Penakalapati SR, et al. Ethnopharmacological evaluation of Poppy seed oil in combination with Tramadol on behavioral paradigm and on dopamine, and cytokines levels. *Eur Rev Med Pharmacol Sci.* 2023;27(5):2077-90.
19. Waterborg JH, Matthews HR. The lowry method for protein quantitation. *Methods Mol Biol.* 1984;1:1-3.
20. Ohkawa H, Ohishi N, Yagi K. Assay for lipid peroxides in animal tissues by thiobarbituric acid reaction. *Anal Biochem.* 1979;95(2):351-8.
21. Jollow DJ, Mitchell JR, Zampaglione N, et al. Bromobenzene-induced liver necrosis. Protective role of glutathione and evidence for 3,4-bromobenzene oxide as the hepatotoxic metabolite. *Pharmacology.* 1974;11(3):151-69.
22. Mohandas J, Marshall JJ, Duggin GG, et al. Low activities of glutathione-related enzymes as factors in the genesis of urinary bladder cancer. *Cancer Res.* 1984;44(11):5086-91.
23. Marklund S, Marklund G. Involvement of the superoxide anion radical in the autoxidation of pyrogallol and a convenient assay for superoxide dismutase. *Eur J Biochem.* 1974;47(3):469-74.
24. Claiborne A, Fridovich I. Purification of the o-dianisidine peroxidase from *Escherichia coli* B. Physicochemical characterization and analysis of its dual catalytic and peroxidatic activities. *J Biol Chem.* 1979;254(10):4245-52.
25. Al-Harbi NO, Imam F, Nadeem A, et al. Protection against tacrolimus-induced cardiotoxicity in rats by olmesartan and aliskiren. *Toxicol Mech Methods.* 2014;24(9):697-702.
26. Lefrak EA, Pitha J, Rosenheim S, et al. A clinicopathologic analysis of adriamycin cardiotoxicity. *Cancer.* 1973;32(2):302-14.
27. Cardinale D, Colombo A, Lamantia G, et al. Anthracycline-induced cardiomyopathy: clinical relevance and response to pharmacologic therapy. *J Am Coll Cardiol.* 2010;55(3):213-20.
28. Koleini N, Kardami E. Autophagy and mitophagy in the context of doxorubicin-induced cardiotoxicity. *Oncotarget.* 2017;8(28):46663-80.
29. Zeng C, Zhong P, Zhao Y, et al. Curcumin protects hearts from FFA-induced injury by activating Nrf2 and inactivating NF-kappaB both in vitro and in vivo. *J Mol Cell Cardiol.* 2015;79:1-12.
30. Mesquita TRR, de Jesus ICG, Dos Santos JF, et al. Cardioprotective Action of Ginkgo biloba Extract

- against Sustained beta-Adrenergic Stimulation Occurs via Activation of M(2)/NO Pathway. *Front Pharmacol.* 2017;8:220.
31. Arruda FS, Tome FD, Milhomem AC, et al. Curcumin Attenuates Doxorubicin-Induced Cardiac Oxidative Stress and Increases Survival in Mice. *Pharmaceutics.* 2024;16(8).
 32. Gyongyosi M, Lukovic D, Zlabinger K, et al. Liposomal doxorubicin attenuates cardiotoxicity via induction of interferon-related DNA damage resistance. *Cardiovasc Res.* 2020;116(5):970-82.
 33. Chow CK. Vitamin E and oxidative stress. *Free Radic Biol Med.* 1991;11(2):215-32.
 34. Lobo V, Patil A, Phatak A, et al. Free radicals, antioxidants and functional foods: Impact on human health. *Pharmacogn Rev.* 2010;4(8):118-26.
 35. Munir S, Hafeez R, Younis W, et al. The Protective Effect of Citronellol against Doxorubicin-Induced Cardiotoxicity in Rats. *Biomedicines.* 2023;11(10).
 36. Cappetta D, De Angelis A, Sapio L, et al. Oxidative Stress and Cellular Response to Doxorubicin: A Common Factor in the Complex Milieu of Anthracycline Cardiotoxicity. *Oxid Med Cell Longev.* 2017;2017:1521020.
 37. Alam MF, Hijri SI, Alshahrani S, et al. Zingerone Attenuates Carfilzomib-Induced Cardiotoxicity in Rats through Oxidative Stress and Inflammatory Cytokine Network. *Int J Mol Sci.* 2022;23(24).
 38. Pagan LU, Gomes MJ, Martinez PF, et al. Oxidative Stress and Heart Failure: Mechanisms, Signalling Pathways, and Therapeutics. *Oxid Med Cell Longev.* 2022;2022:9829505.
 39. Khan G, Alam MF, Alshahrani S, et al. Trastuzumab-Mediated Cardiotoxicity and Its Preventive Intervention by Zingerone through Antioxidant and Inflammatory Pathway in Rats. *J Pers Med.* 2023;13(5).
 40. Songbo M, Lang H, Xinyong C, et al. Oxidative stress injury in doxorubicin-induced cardiotoxicity. *Toxicol Lett.* 2019;307:41-8.
 41. Alam MF, Ajeibi AO, Safhi MH, et al. Therapeutic Potential of Capsaicin against Cyclophosphamide-Induced Liver Damage. *J Clin Med.* 2023;12(3).
 42. Alsahli TG, Alharbi KS, Alenezi SK, et al. Aegeline improves doxorubicin-induced liver toxicity by modulating oxidative stress and Bax/Bcl2/caspase/NF-kappaB signaling. *Sci Rep.* 2025;15(1):27203.