Babol University Of Medical Sciences

IJMCM, Autumn 2025, VOL 14, NO 4

International Journal of Molecular and Cellular Medicine

Journal homepage: www.ijmcmed.org

CASE REPORT

Pulmonary toxoplasmosis in a multiple myeloma patient: A Case report and literature review

Asgar Baghernejad Nesheli[1], Somayeh Sadeghi[2], Mahdi Fakhar[3,4], Sara Ghandi[5], Sadegh Fattahi[6], Eissa Soleymani[4,7], Abbasali Eskandarian[1]*

1. Department of Medical Parasitology and Mycology, Faculty of Medicine, Isfahan University of Medical Sciences, Isfahan, Iran.
2. Department of Internal Medicine, Alzahra Hospital, Isfahan University of Medical Sciences, Isfahan, Iran.
3. Department of Medical Microbiology and Immunology, School of Medicine, Qom University of Medical Sciences, Qom, Iran
4. Iranian National Registry Center for Lophomoniasis and Toxoplasmosis, Imam Khomeini Hospital, Mazandaran University of Medical Sciences, Sari, Iran.
5. Toxoplasmosis Research Center, Communicable Diseases Institute, Department of Parasitology, Mazandaran University of Medical Sciences, Sari, Iran.
6. North Research Center, Pasteur Institute of Iran, Amol, Iran.
7. Department of Parasitology and Mycology, Faculty of Medicine, Mazandaran University of Medical Sciences, Sari, Iran.

ARTICLE INFO

Received: 2025/06/28
Revised: 2025/08/12
Accepted: 2025/10/05

***Corresponding**:
Abbasali Eskandarian
Address:
Department of Parasitology and Mycology, Faculty of Medicine, Mazandaran University of Medical Sciences, Sari, Iran
E-mail:
aeskandarian@med.mui.ac.ir

ABSTRACT

Pulmonary toxoplasmosis is a rare but potentially fatal opportunistic infection, most often reported in HIV-infected individuals. Its occurrence in non-HIV immunocompromised patients—particularly those with hematologic malignancies like multiple myeloma (MM)—is exceedingly rare and diagnostically challenging due to nonspecific clinical and radiologic features. While *Toxoplasma gondii* infection is typically mild in immunocompetent hosts, it can cause severe disease in immunocompromised populations. A literature review was conducted using PubMed, Scopus, and Google Scholar (January 2000–May 2025) with keywords: 'pulmonary toxoplasmosis,' 'multiple myeloma,' 'non-HIV,' 'immunocompromised,' and 'BAL PCR.' Only English-language case reports and reviews were included, with emphasis on studies from endemic regions and the past five years. We report a 49-year-old Iranian man with newly diagnosed IgG kappa MM who presented with fever, chills, vomiting, and dyspnea. Chest CT revealed a 4.2 × 3.8 cm consolidation in the posterior segment of the right lower lobe. T. gondii infection was confirmed via bronchoalveolar lavage (BAL) through tachyzoite detection on Giemsa stain and molecular identification using qPCR and nested PCR targeting the Gra6 gene. He showed transient clinical improvement and was discharged on hospital day 7. Unfortunately, he died at home within 48 hours due to MM progression, before anti-toxoplasmosis therapy was initiated. This case underscores the diagnostic difficulty of pulmonary toxoplasmosis in non-HIV immunocompromised patients and the importance of molecular BAL testing. Prophylactic measures such as co-trimoxazole should be considered in high-risk MM patients. Guidelines must address screening and management in this vulnerable population.

Keywords: Bronchoalveolar lavage, Co-trimoxazole, Immunocompromised host, Lung, Multiple myeloma, Pulmonary toxoplasmosis, *Toxoplasma gondii*

Cite this article: Baghernejad Nesheli A, et al. Pulmonary toxoplasmosis in a multiple myeloma patient: A Case report and literature review. International Journal of Molecular and Cellular Medicine. 2025; 14 (4):1129-1137. DOI: 10.22088/IJMCM.BUMS.14.4.1129

[Downloaded from ijmcmed.org on 2026-11-23]

[DOI: 10.22088/IJMCM.BUMS.14.4.1129]

© The Author(s).
Publisher: Babol University of Medical Sciences
This work is published as an open access article distributed under the terms of the Creative Commons Attribution 4.0 License (http://creativecommons.org/licenses/by-nc/4). Non-commercial uses of the work are permitted, provided the original work is properly cited.

Introduction

Toxoplasma gondii (T. gondii) is an intracellular parasite that infects different hosts, ranging from humans to animals. It causes zoonotic infections in humans [1-3]. Ingestion of tissue cysts via raw or undercooked meat remains the main route of transmission. Ingestion of *T. gondii* oocysts through contaminated water or tissue cysts in undercooked meat represents a significant mode of transmission, particularly in areas with poor sanitation or culinary practices involving raw meat [4, 5]. Mild or asymptomatic infection is generally observed in healthy hosts. *T. gondii* may cause severe and life-threatening manifestations as an opportunistic pathogen in immunocompromised individuals [2, 6]. Patients who do not have a properly functioning immune system, such as chemotherapy patients, organ transplant recipients, AIDS patients, people on various immunosuppressive treatments, are at high risk of developing severe or fatal toxoplasmosis [7, 8].

In Iran, toxoplasmosis is highly endemic, with seroprevalence rates ranging from 30% to over 50% in the general population, depending on geographic region, dietary habits, and socioeconomic factors [9-11]. Recent studies from Mazandaran and Isfahan provinces have documented increasing reports of severe toxoplasmosis in immunocompromised non-HIV patients, including those with hematologic malignancies and solid organ transplant recipients [12]. Notably, T. gondii DNA has been detected in malignant breast tissues of Iranian breast cancer patients, indicating that the parasite may localize within diverse tumor microenvironments beyond hematologic cancers [13]. Despite this high background seroprevalence, pulmonary toxoplasmosis remains exceptionally rare in Iranian patients with multiple myeloma with no prior documented cases in the national literature to our knowledge [14]. This underscores the diagnostic challenge and highlights the need for heightened clinical suspicion and molecular confirmation in at-risk populations.

In such cases, reactivation of latent *T. gondii* infection is usually responsible or an acute primary *Toxoplasma* infection through the gastrointestinal tract can damage several organs, including the CNS, heart and lung. While rare, pulmonary toxoplasmosis is a serious complication that causes severe pneumonia, pleural effusion, and acute respiratory failure. Historically, some early case series primarily involving AIDS patients with advanced immunosuppression reported pleural effusion in up to 94% of pulmonary toxoplasmosis cases [15]. However, this statistic is not generalizable to non-HIV immunocompromised populations, such as patients with hematologic malignancies. More recent literature and case reports including those in multiple myeloma and solid organ transplant recipients have described variable radiological presentations, including unilateral or bilateral consolidations, ground-glass opacities, nodules, and, in some cases, absence of pleural effusion [16, 17].

Therefore, the absence of pleural effusion should not exclude the diagnosis of pulmonary toxoplasmosis, particularly in non-HIV hosts [16]. It is difficult to diagnose pulmonary toxoplasmosis due to its rarity in immunocompromised patients and the fact that its clinical presentation is nonspecific; for example, this condition is radiologically similar to some infections [18]. It is important to report these cases to make the doctors aware and intervene early. This paper is about a case of pulmonary toxoplasmosis occurring in a patient suffering from multiple myeloma (MM) and the importance of prompt diagnosis.

Case presentation:

A 49-year-old man suffering from multiple myeloma (MM) for three years was sent to Al-Zahra Medical Center, Isfahan, central Iran, in June 2024. The man had undergone 14 cycles of chemotherapy and bone marrow transplantation five months later. For two years he was stable on maintenance pharmacological therapy until was diagnosed again two months before presentation and required four more cycles of chemotherapy. On admission, the patient reported fever, chills, nausea and vomiting.

He was treated for hyperlipidemia and hyperthyroid disease a year ago. As per the latest medication chart, this patient is receiving a combination of the following medications: lithium (300 mg BD), methimazole (5 mg OD), dimetrazole (4 mg OD), pantoprazole (40 mg OD), valacyclovir (500 mg OD) and gemfibrozil (300 mg BD). Empiric broad-spectrum antibiotics (imipenem for gram-negative coverage including Pseudomonas, levofloxacin for atypical pathogens, and teicoplanin for gram-positive coverage including MRSA) were initiated per institutional guidelines for febrile neutropenia with pulmonary infiltrates. Specific anti-toxoplasmosis

[Downloaded from ijmcmed.org on 2026-11-23]

[DOI: 10.22088/IJMCM.BUMS.14.4.1129]

therapy (e.g., trimethoprim-sulfamethoxazole) was not initiated prior to discharge due to the patient's transient clinical improvement and the pending finalization of molecular diagnostic results, which were confirmed post-discharge. Laboratory results showed leukopenia (WBC: 1.4 × 10^9 /L with 14% lymphocytes and 73% neutrophils) and thrombocytopenia (platelets: 45 × 10^9 /L). Serum electrolytes revealed mild hyponatremia (135 mmol/L) and hypokalemia (3.5 mmol/L).

The potassium levels in blood serum were 3.5 mEq/L, hypokalemia. Serological testing (IgG/IgM) and CD4+ T-cell count were not performed due to the patient's critical condition and logistical constraints. Empiric broad-spectrum antibiotics (imipenem, levofloxacin, teicoplanin) were initiated for suspected bacterial pneumonia. A chest CT scan revealed a well-defined, 4.2 × 3.8 cm consolidation with air bronchograms in the posterior segment of the right lower lobe. No pleural effusion, lymphadenopathy, or contralateral involvement was observed. Chest X-ray (CXR) corroborated these findings, showing a dense, homogeneous opacity in the right lower zone (Figure. 1). For more diagnosis, the doctor used bronchoscopy. They sent the samples of bronchoalveolar lavage (BAL) to the parasitology laboratory at the Faculty of Medicine for microscopic examination using *Giemsa, acid-fast, and modified trichrome* ".

Giemsa-stained BAL cytospin preparation revealed multiple intracellular and extracellular tachyzoites, characterized by their classic crescent or banana shape (approximately 2–3 µm wide and 4–7 µm long), confirming active T. gondii infection (Figure. 2).

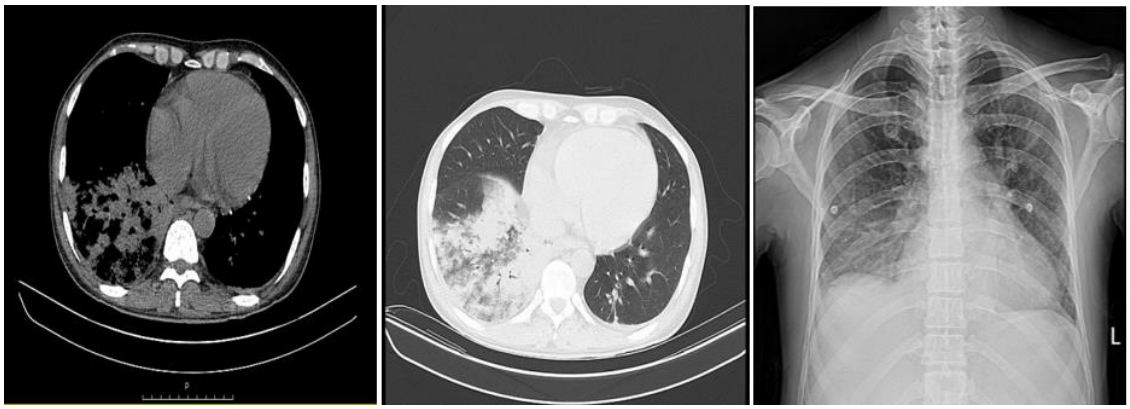

Figure 1. Lung CT scan and Chest X-ray (CXR) showed pneumonia

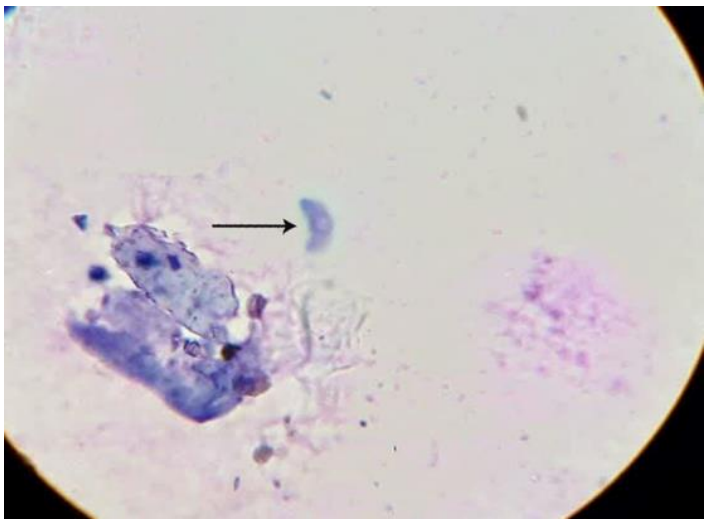

Figure 2. Giemsa-stained bronchoalveolar lavage specimen demonstrating *Toxoplasma gondii* tachyzoites (arrow) in a multiple myeloma patient (400× magnification).

[Downloaded from ijmcmed.org on 2026-11-23]

[DOI: 10.22088/IJMCM.BUMS.14.4.1129]

Given the patient's immunocompromised status and radiological findings, a broad differential was considered, including Pneumocystis jirovecii pneumonia (PJP), cytomegalovirus (CMV) pneumonitis, invasive fungal infection (e.g., Aspergillus), and bacterial pneumonia. BAL fluid was negative for Pneumocystis (via Gomori methenamine silver stain), acid-fast bacilli (for TB), and fungal elements (via KOH and calcofluor white). CMV PCR on BAL was negative. Bacterial and fungal cultures from BAL and blood remained sterile after 5 days of incubation. To confirm the diagnosis at the molecular level, two independent PCR-based assays were used: QPCR (DynaBio kit /Iran), and nested PCR, both targeting Gra6 gene. Real-time PCR targeting the Gra6 gene yielded a positive result with a cycle threshold (Ct) value of 34, indicating a low but detectable parasite load (Figure. 3). Melt curve analysis confirmed amplicon specificity. Nested PCR amplification produced a distinct band of the expected size (XXX bp) in the patient sample, which was concordant with the positive control and absent in the negative control, providing definitive molecular confirmation (Figure. 3 and 4).

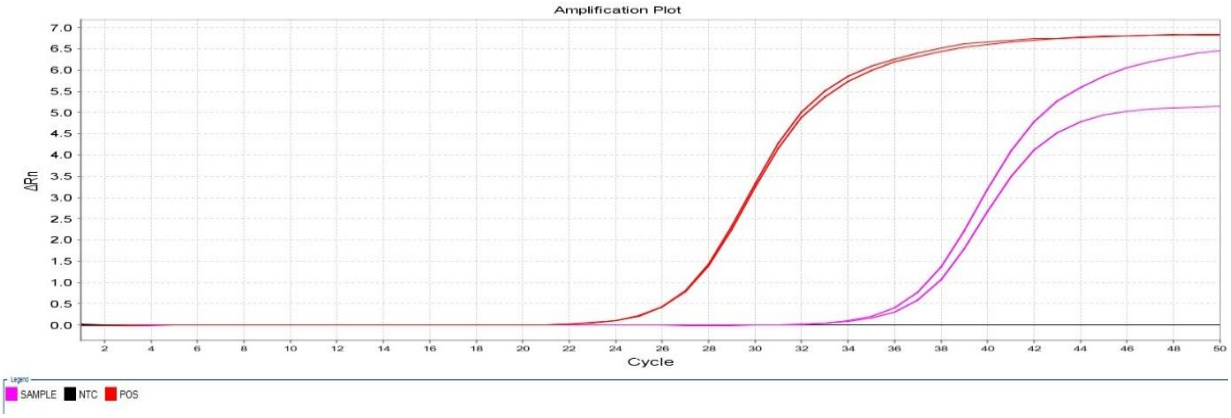

Figure 3. Real-time PCR detection of *Toxoplasma gondii* in bronchoalveolar lavage from a multiple myeloma patient. Amplification plot showing positive fluorescence signal crossing the threshold (Ct = 34). The samples were repeated twice.

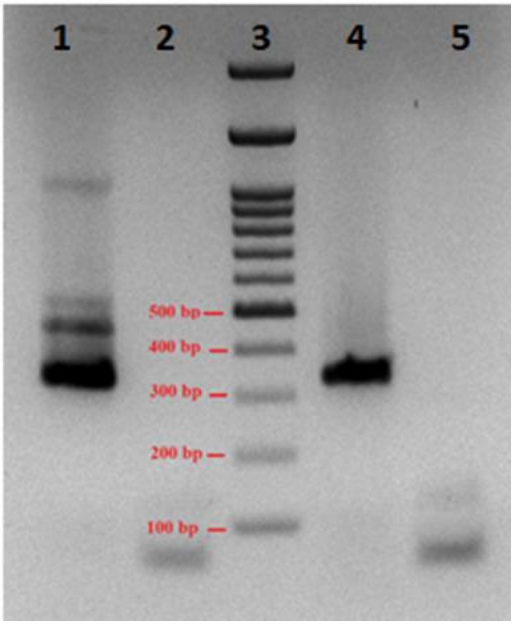

[Downloaded from ijmcmed.org on 2026-11-23]

[DOI: 10.22088/IJMCM.BUMS.14.4.1129]

Figure 4. Gel electrophoresis of Nested PCR products, Positive control (Lane 1), Negative control (Lane 2), Lader (Lane 3), Positive sample (Lane 4), Negative sample (Lane 5).

Positive control samples were included in each assay to ensure the validity of amplification. Specificity of Real-Time PCR was assessed via melting curve analysis, while nested PCR products were visualized by agarose gel electrophoresis. Both molecular methods yielded concordant positive results, providing strong molecular support for the microscopic diagnosis. An expert in infectious diseases started empiric broad-spectrum antibiotic therapy with imipenem, levofloxacin, and teicoplanin.

After treatment was finished, the patient showed signs of improvement, such as a decrease in fever, the ability to eat normally again, and overall relief from symptoms. He was discharged with appropriate follow-up instructions, medication guidance, and education on recognizing warning signs. Despite being scheduled for outpatient hematologic evaluation one-week post-discharge, the patient succumbed to his condition (MM) prior to initiation of specific treatment for toxoplasmosis.

chronological timeline: Day 0: Symptom onset (fever, chills, vomiting, dyspnea). Day 3: Admission to Al-Zahra Hospital. Empiric antibiotics (imipenem, levofloxacin, teicoplanin) initiated. Day 4: Bronchoscopy performed; BAL fluid sent for microbiological and parasitological analysis. Day 7): Patient showed transient clinical improvement (afebrile, tolerating oral intake). Discharged with scheduled outpatient follow-up in 7 days. Day 9: Patient succumbed at home. Day 10: qPCR and nested PCR results finalized, confirming T. gondii infection (CT=28). This study was approved by Ethics Committee of Isfahan University of Medical Sciences (No: IR.MUI.MED.REC. 1403.195).

Discussion

This report presented a rare and fatal case of pulmonary toxoplasmosis in a patient with MM. The case highlights the significant diagnostic and therapeutic challenges posed by opportunistic infections in the immunocompromised populations. Cellular immune deficiency - characteristic of patients with hematologic malignancies like MM, transplant recipients on immunosuppressive regimens, and individuals with chronic kidney failure on hemodialysis - markedly increases susceptibility to opportunistic pathogens. Among protozoan opportunistic infections, *T. gondii* represents one of the most clinically significant etiologic agents in this vulnerable patient population [19]. Patients with MM are prone to severe infections due to both disease-induced immunodeficiency and the effects of intensive chemotherapy. Humoral immune dysfunction (hypogammaglobulinemia) and impaired cellular immunity predispose these patients to infections by opportunistic pathogens, including *T. gondii* [20]. But pulmonary toxoplasmosis is still very rare in people with hematologic malignancies, especially MM. A study of 34,701 patients with hematologic malignancies found only 339 cases of toxoplasmosis. Of those, only one patient with MM had CNS involvement, and two patients with CLL were diagnosed with pulmonary toxoplasmosis [21].

Severe manifestations of toxoplasmosis, such as encephalitis, myocarditis, and chorioretinitis, are usually observed in the patients with profound immunosuppression, particularly those with CD4+ T-cell counts below 0.1×10^8/L [1, 22]. In rare cases, the lungs may be the only affected organ. Although pulmonary toxoplasmosis is predominantly reported in HIV-positive individuals, some cases were not documented in the patients with neoplasms [19]. Acute pulmonary toxoplasmosis can present with nonspecific symptoms, such as cough (productive or dry), myalgia, arthralgia, lymphadenopathy, fever, and dyspnea [23]. A study by Nianhong Lu described a case of a lung cancer patient co-infected with pulmonary toxoplasmosis. The patient had a dry cough, chest pain, swollen lymph nodes above the left clavicle, and right hilar adenopathy. Serological tests, CT scans, and bronchoscopy with BAL all confirmed that the person had toxoplasmosis [24]. Another study from the same year described a patient with a dry cough and fever, but no history of HIV or malignancy. Chest CT revealed scattered patchy areas in both lungs with high-density flocculent shadows and irregular margins. Serological tests detected anti-*T. gondii* IgG antibodies at a titer of 1:600 (modified agglutination test), confirming the infection [25].

The nonspecific nature of symptoms, and radiological overlap with other infectious and inflammatory conditions make diagnosing pulmonary toxoplasmosis challenging [26] Chest radiography

[Downloaded from ijmcmed.org on 2026-11-23]

[DOI: 10.22088/IJMCM.BUMS.14.4.1129]

findings may include reticulonodular infiltrates, nodular opacities, or diffuse lung opacities. The diagnosis is typically established by measuring IgM and IgG antibody titers against *T. gondii* in serum [23]. A study found a case of pulmonary toxoplasmosis in a patient with inflammatory arthritis who was taking prednisone and methotrexate and had a weak immune system. Radiographic results showed patchy airspace disease that was consistent with pneumonia. But PCR and finding tachyzoites in BAL fluid [23]. made it possible to make a definite diagnosis. Similarly, a study by Adurthi et al. emphasized the importance of PCR in confirming the diagnosis [27]. In our case, serological testing alone was not relied upon; BAL samples were sent for Giemsa staining and PCR, both of which confirmed the presence of *T. gondii.* While BAL fluid has been increasingly utilized in Iran not only for detecting opportunistic pathogens like T. gondii but also for molecular profiling in inflammatory lung conditions—as demonstrated in studies of ACE2 expression in ARDS associated with COVID-19 [28] ,its role in diagnosing rare parasitic pneumonias remains underrecognized

The treatment of pulmonary toxoplasmosis typically involves antibiotics from the macrolide or sulfonamide classes. Spiramycin is the drug of choice for pregnant women [25]. A recent case report described a patient with a history of consuming venison who presented with fever, myalgia, and cough. Chest imaging revealed bilateral infiltrates in the lower lobes. Following confirmation of toxoplasmosis via serology and PCR, the patient was treated with sulfamethoxazole and recovered successfully [17]. Pangracio also reported a case of concurrent pulmonary and renal toxoplasmosis in a 38-year-old man that year. He was treated with trimethoprim-sulfamethoxazole and prednisone and had a good response [29]. Francine De Salvador-Guillouët et al. also wrote a case report about a rare strain of pulmonary *T. gondii* that was found through bronchoscopy with BAL, where tachyzoites were found. The patient was successfully treated with pyrimethamine and sulfadiazine [30]. In our case, the patient's symptoms initially improved with broad-spectrum antibiotics, including imipenem, levofloxacin, and teicoplanin. However, unlike similar reports, sulfamethoxazole was not administered. Regarding cancer progression and profound immunosuppression, the patient ultimately died. The patient's death is best understood as the direct consequence of untreated, disseminated pulmonary toxoplasmosis, occurring against a background of advanced, chemotherapy-refractory multiple myeloma. While the patient exhibited transient clinical improvement (afebrile, resumed oral intake) on empiric broad-spectrum antibiotics, this response likely reflected partial control of bacterial co-pathogens or a non-specific anti-inflammatory effect — not resolution of the underlying T. gondii infection. The visualization of tachyzoites and molecular confirmation (CT=28) in BAL fluid indicate active, replicating disease. In profoundly immunocompromised hosts, pulmonary toxoplasmosis progresses rapidly and is uniformly fatal without targeted anti-parasitic therapy. The decision to discharge the patient prior to the return of confirmatory results and initiation of specific treatment created a critical therapeutic gap. We conclude that the fatal outcome was precipitated by the unchecked proliferation of T. gondii, with the underlying MM serving as the permissive substrate that enabled reactivation and dissemination. The delay in diagnosis and treatment — not the MM progression alone — was the proximate cause of death.

TMP-SMX is a well-established, cost-effective agent for preventing Pneumocystis jirovecii pneumonia (PJP) and Toxoplasma gondii reactivation in high-risk immunocompromised populations, including allogeneic stem cell transplant recipients and patients with acute leukemia [31, 32]. However, routine toxoplasmosis prophylaxis is not standard for MM patients outside the context of HIV co-infection. This case, alongside emerging reports [11, 33], argues for a paradigm shift. We propose that TMP-SMX prophylaxis should be considered for MM patients who meet the following criteria: (1) known T. gondii IgG seropositivity (indicating latent infection), (2) planned intensive chemotherapy or stem cell transplantation, and (3) documented prolonged neutropenia (ANC <500/μL for >7 days) or lymphopenia (absolute lymphocyte count <500/μL). In this case, had serostatus been known and positive, prophylaxis could have prevented reactivation. Future clinical guidelines must address this gap for non-HIV immunocompromised hosts, particularly in endemic regions like Iran.

This case underscored the critical need for heightened clinical vigilance and timely therapeutic

[Downloaded from ijmcmed.org on 2026-11-23]

[DOI: 10.22088/IJMCM.BUMS.14.4.1129]

intervention when multiple myeloma patients present with unexplained respiratory symptoms. Considering the substantial mortality associated with pulmonary toxoplasmosis, targeted preventive measures should be prioritized for high-risk immunocompromised populations, particularly those receiving chemotherapy or post-transplant immunosuppression. Also, future research should focus on creating standardized treatment plans and evidence-based diagnostic algorithms for toxoplasmosis in non-HIV immunocompromised hosts. This is because most of the current guidelines are based on cases involving people with HIV.

Limitations and Future Directions

This report has several limitations. First, the absence of an autopsy precludes definitive confirmation of the extent of T. gondii dissemination or the exclusion of other concurrent fatal pathologies. Second, the lack of baseline serology (IgG/IgM) and CD4+ count limits our ability to determine whether this was a reactivation of latent infection or a primary acquisition. Third, the delay in initiating targeted therapy was a direct consequence of the time required for molecular confirmation, highlighting a critical gap in rapid diagnostic pathways for opportunistic infections. Moving forward, we propose the following: (1) Routine Screening: All MM patients in endemic regions should undergo T. gondii IgG serology prior to initiating chemotherapy or stem cell transplantation (2). Prophylaxis Protocol: IgG-positive patients undergoing intensive immunosuppression should receive TMP-SMX prophylaxis (3). Rapid Diagnostics: Hospitals should establish reflex PCR testing for T. gondii (and other key opportunistic pathogens like PJP and CMV) on BAL fluid from immunocompromised patients with unexplained pneumonia (4). Clinical Guidelines: National and international hematology/oncology societies should develop specific guidelines for toxoplasmosis prevention and management in non-HIV immunocompromised hosts, particularly those with hematologic malignancies

Acknowledgement

We express our heartfelt gratitude to Al-Zahra Hospital, associated with Isfahan University of Medical Sciences, for their significant assistance in providing us with the essential data. We declare that appropriate written informed consent was obtained from the patient for the publication of this manuscript and associated images.

Funding

This study was supported by the Isfahan University of Medical Sciences.

References

1. Soleymani E, Babamahmoodi F, Davoodi L, et al. Toxoplasmic Encephalitis in an AIDS Patient with Normal CD4 Count: A Case Report. Iran J Parasitol. 2018;13(2):317-22.
2. Matta SK, Rinkenberger N, Dunay IR, et al. Toxoplasma gondii infection and its implications within the central nervous system. Nat Rev Microbiol. 2021;19(7):467-80.
3. Eskandarian A, Jahani S, Hejazi H, et al. Investigation of Toxoplasma gondii infection in Cutaneous Leishmaniasis patients of the Isfahan province. Int J Infect. 2017;4(2).
4. Almeria S, Dubey J. Foodborne transmission of Toxoplasma gondii infection in the last decade. An overview. Res Vet Sci. 2021;135:371-85.
5. Soleymani E, Faizi F, Heidarimoghadam R, et al. Association of T. gondii infection with suicide: a systematic review and meta-analysis. BMC Public Health. 2020;20(1):766.
6. Eskandarian AA, Jafarnezghad G-A, Akbari M. Seroprevalence of Toxoplasma-specific antibodies in patients suspected to have active toxoplasmosis: A cross-sectional survey. Adv Biomed Res. 2014;3(1):236.
7. Espersen E. Toxoplasmosis. A Survey-and a Case of Acquired Pulmonary Toxoplasmosis. Acta Tuberc Scand. 1957;34(3-4):163-72.
8. Eskandarian A. Seroepidemiology of toxoplasmosis in admitted pregnant women in maternity ward of Kowsar teaching and cure center in Qazvin-2006. Iranian J Med Microbiol. 2009;3(2):73-9.
9. Daryani A, Sarvi S, Aarabi M, et al. Seroprevalence of Toxoplasma gondii in the Iranian general population: a systematic review and meta-analysis. Acta Trop. 2014;137:185-94.
10. Hamidi F, Rostami A, Hosseini SA, et al. Anti-Toxoplasma gondii IgG seroprevalence in the

[Downloaded from ijmcmed.org on 2026-11-23]

[DOI: 10.22088/IJMCM.BUMS.14.4.1129]

general population in Iran: A systematic review and meta-analysis, 2000–2023. Plos one. 2024;19(8):e0307941.
11. Teimouri A, Goudarzi F, Goudarzi K, et al. Toxoplasma gondii infection in immunocompromised patients in Iran (2013–2022): a systematic review and meta-analysis. Iran J Parasitol. 2022;17(4):443.
12. Rafati-Sajedi H, Majidi-Shad B, Jafari-Shakib R, et al. Serological evaluation of toxoplasmosis and related risk factors among HIV+/AIDS patients in northern Iran. Acta Parasitologica. 2021;66(4):1417-23.
13. Kalantari N, Darabi ZA, Siadati S, et al. Detection of Toxoplasma gondii DNA in malignant breast tissues in breast cancer patients. Int j mol cell med. 2017;6(3):190.
14. Salari N, Rahimi A, Zarei H, et al. Global seroprevalence of Toxoplasma gondii in pregnant women: a systematic review and meta-analysis. BMC Pregnancy and Childbirth. 2025;25(1):90.
15. Mizani A, Alipour A, Sharif M, et al. Toxoplasmosis seroprevalence in Iranian women and risk factors of the disease: a systematic review and meta-analysis. Trop Med Health. 2017;45(1):7.
16. Layton J, Theiopoulou D-C, Rutenberg D, et al. Clinical spectrum, radiological findings, and outcomes of severe toxoplasmosis in immunocompetent hosts: a systematic review. Pathogens. 2023;12(4):543.
17. Hayes L, Schwartz A. Severe Disseminated Toxoplasmosis Pneumonia in an Immunocompetent Adult. C67. DON'T FORGET ABOUT THESE UNUSUAL LUNG INFECTIONS: American Thoracic Society; 2023. p. A5629-A.
18. Pomeroy C, Filice GA. Pulmonary toxoplasmosis: a review. Clin Infect Dis. 1992;14(4):863-70.
19. Yazar S, Yaman O, Eser B, et al. Investigation of anti-Toxoplasma gondii antibodies in patients with neoplasia.J. Med. Microbiol. 2004;53(12):1183-6.
20. Nucci M, Anaissie E. Infections in patients with multiple myeloma. Semin Hematol. 2009 Jul;46(3):277-88.
21. Chintakuntlawar A, Kidd M, Al-Kali A, et al. Toxoplasmosis in patients with hematologic malignancies. Leuk. Lymphoma. 2015;56(2):536-8.
22. Desoubeaux G, Cabanne É, Franck-Martel C, et al. Pulmonary toxoplasmosis in immunocompromised patients with interstitial pneumonia: a single-centre prospective study assessing PCR-based diagnosis.J. Clin. Pathol. 2016;69(8):726-30.
23. Abdulkareem A, D'Souza RS, Patel N, et al. A rare case of pulmonary toxoplasmosis in a patient with undifferentiated inflammatory arthritis on chronic methotrexate and corticosteroid therapy. Case Rep. 2017;2017:bcr-2017-221252.
24. Lu N, Liu C, Wang J, et al. Toxoplasmosis complicating lung cancer: a case report. Int. Med. Case Rep. J. 2015:37-40.
25. Shen C-x, Zhang G-l, Song X-l, et al. Toxoplasma gondii pneumonia in an immunocompetent individual. Am. J. Med. Sci. 2015;350(1):70-1.
26. Garg D, Madan N, Qaqish O, et al. Pulmonary toxoplasmosis diagnosed on transbronchial lung biopsy in a mechanically ventilated patient. Cases Rep. Infect. Dis. 2020;2020(1):9710182.
27. Adurthi S, Sahoo T, Chakka K, et al. Acute toxoplasmosis in nonstem cell transplant patients with haematological malignancies: a study from a regional cancer institute in South India.Hematol Oncol. 2008;26(4):229-33.
28. Najafipour R, Mohammadi D, Momeni M, et al. ACE-2 Expression and methylation pattern in bronchoalveolar lavage fluid and bloods of Iranian ARDS COVID-19 patients. IInt. J. Mol. Med. and Cell. Med. 2022;11(1):55.
29. Pangracio E, de Macedo V, Alves PK. Pulmonary and renal toxoplasmosis in an immunocompetent adult patient. J Med Cases. 2023;14(2):50.
30. De Salvador-Guillouët F, Ajzenberg D, Chaillou-Opitz S, et al. Severe pneumonia during primary infection with an atypical strain of Toxoplasma gondii in an immunocompetent young man. J Infect. 2006;53(2):e47-e50.
31. Zmarlicka M, Martin ST, Cardwell SM, et al. Tolerability of low-dose sulfamethoxazole/trimethoprim for Pneumocystis jirovecii pneumonia prophylaxis in kidney transplant recipients. Prog. Transplant. 2015;25(3):210-6.
32. Schwenk HT, Khan A, Kohlman K, et al. Toxoplasmosis in pediatric hematopoietic stem cell transplantation patients. Transplant Cell Ther. 2021;27(4):292-300.

[Downloaded from ijmcmed.org on 2026-11-23]

[DOI: 10.22088/IJMCM.BUMS.14.4.1129]

33. Ahmadpour E, Daryani A, Sharif M, et al. Toxoplasmosis in immunocompromised patients in Iran: a systematic review and meta-analysis. J. Infect. Dev. Ctries. 2014;8(12):1503-10.

[Downloaded from ijmcmed.org on 2026-11-23]

[DOI: 10.22088/IJMCM.BUMS.14.4.1129]