



## Improvement of Corneal Nerve Regeneration in Diabetic Rats Using Wharton's Jelly-Derived Mesenchymal Stem Cells and their Conditioned Medium

Pitra Ariesta Shinta Dewi<sup>1\*</sup>, Ratna Sitompul<sup>2</sup>, Jeanne Adiwinata Pawitan<sup>3, 4, 5</sup>,   
Aroem Naroeni<sup>4, 6</sup>, Radiana Dewayani Antarianto<sup>3</sup>

1. Doctoral Programme Biomedical Sciences, Faculty of Medicine Universitas Indonesia, Jakarta, Indonesia.

2. Department of Ophthalmology, Faculty of Medicine, Universitas Indonesia, Jakarta, Indonesia.

3. Department of Histology, Faculty of Medicine, Universitas Indonesia, Jakarta, Indonesia.

4. Stem Cell Medical Technology Integrated Service Unit, Dr. Cipto Mangunkusumo General Hospital, Faculty of Medicine Universitas Indonesia, Jakarta, Indonesia.

5. Stem Cell and Tissue Engineering (SCTE) Research Center, Indonesia Medical Education and Research Institute (IMERI), Faculty of Medicine, Universitas Indonesia, Jakarta, Indonesia.

6. Virology and Cancer Pathobiology Research Center, Faculty of Medicine, Universitas Indonesia, Jakarta, Indonesia.

### Article type: **ABSTRACT**

#### Original Article

To investigate the efficacy of Wharton's jelly mesenchymal stem cells (WJSCs) and their conditioned medium (CM) for corneal nerve regeneration in rats with diabetic keratopathy. Streptozotocin (STZ)-induced male diabetic (DM) rats (250–300 g) were divided into four groups (n=7/group): Control, DM, DM with WJSCs (DM+WJ), and DM with CM treatment (DM+CM). DM+WJ and DM+CM group received WJSCs or CM, respectively, topically with eye drops. Corneal sensibility, corneal epithelial layer integrity, histology, expression of GAP-43 and TUBB3 on mRNA level and their immunohistochemical expression were examined after two weeks of treatment. There were changes in corneal sensibility and corneal integrity between normal control and diabetic groups with/without WJSC or CM injection. Total central corneal thickness was significantly higher in DM+CM ( $249.81 \pm 43.85 \mu\text{m}$ ) than in control ( $174.72 \pm 44.12 \mu\text{m}$ ,  $P=0.004$ ) and DM groups ( $190.15 \pm 9.63 \mu\text{m}$ ,  $P=0.03$ ). GAP-43 mRNA expression levels of DM+WJ and DM+CM groups were higher compared with DM and control groups. TUBB3 mRNA level was increased after CM ( $P=0.047$ ), but not after WJSCs treatment ( $P=1.00$ ). GAP-43 and TUBB3 immunohistochemical expression of nerve fibers along the epithelial layer significantly increased in DM+WJ and DM+CM compared with DM group. Our findings showed that WJSCs and their CM improved corneal nerve regeneration in rats with diabetic keratopathy.

#### Received:

2022.04.04

#### Revised:

2022.12.22

#### Accepted:

2023.03.06

**Keywords:** Stem cells, Wharton's jelly, conditioned medium, diabetic rats, GAP-43, TUBB3

**Cite this article:** Ariesta Shinta Dewi. P. Improvement of Corneal Nerve Regeneration in Diabetic Rats Using Wharton's Jelly-Derived Mesenchymal Stem Cells and their Conditioned Medium *International Journal of Molecular and Cellular Medicine*. 2022; 11(3):180-196. DOI: 10.22088/IJMCM.BUMS.11.3.180



© The Author(s).

Publisher: Babol University of Medical Sciences

This work is published as an open access article distributed under the terms of the Creative Commons Attribution 4.0 License

(<http://creativecommons.org/licenses/by-nc/4>). Non-commercial uses of the work are permitted, provided the original work is properly cited.

\*Corresponding Author: Pitra Ariesta Shinta Dewi

Address: Doctoral Programme Biomedical Sciences, Faculty of Medicine, Universitas Indonesia.

E-mail: pitraariesta@yahoo.com

## Introduction

Diabetes mellitus (DM) is a chronic metabolic disease with high morbidity and mortality rates worldwide. Its prevalence is currently affecting about 463 million people with expected rise to around 700 million worldwide by the year 2045 (1). DM consists of a group of disorders characterized by hyperglycemia, changes in lipid, carbohydrate and protein metabolism, and an increased risk of neurovascular complications<sup>[2–4]</sup>. Ocular complications in DM include retinal abnormalities (diabetic retinopathy), abnormalities of the lens (diabetic cataract), or structural abnormalities of the cornea (diabetic keratopathy) (2–4). The prevalence of diabetic keratopathy and retinopathy is 47%–70% (3,5–7) and 17.2%–42.6% (7), respectively.

Corneal metabolic disorders in DM are accompanied by accumulation of advanced glycation end-products (AGEs) in Descemet's membrane. AGEs initiate the disruption of the endothelial attachment from the Descemet's membrane and increase production of reactive oxygen species (ROS), thereby resulting in apoptosis of corneal endothelial cells and changing Descemet's membrane composition (8). The thinning of corneal epithelium leads to decreased corneal sensibility, which is associated with nerve fiber degeneration which may consequently lead to worsening of corneal symptoms (9–11). It is important for diabetic keratopathy to be diagnosed and treated early as resistance to routine treatment will occur in later disease.

Examination of corneal nerve regeneration can measure the severity of diabetic keratopathy. Evaluation can be done by immunohistochemical staining for growth associated protein-43 (GAP-43) and beta tubulin III (TUBB3), two markers of nerve regeneration (12,13). GAP-43 is a presynaptic protein located on terminal axons, axon branches, or growth cones; it is important for the development of the visual nervous system and also plays a role in repair and regeneration of retinal ganglion cells (RGCs) (14–17). Tubb3 participates in forming the cytoskeleton; it is a specific neuronal marker and a marker of axon regeneration (16,18,19).

Various studies have reported that topical application of mesenchymal stem cells (MSCs) via eye drops can improve dry eye syndrome (20–23). A topical administration of eye drops containing adipose-derived stem cells (ADSCs) was reported as a non-invasive therapeutic method for corneal nerve regeneration<sup>[24]</sup>. Wharton's jelly mesenchymal stem cells (WJSCs) also have a high differentiation potential with an immunoprivileged status that prevents post-transplant rejection reactions (25–28); they have been also reported as potential therapeutics for stem cells differentiation into Schwann cells (29). However, topical administration of WJSCs and their conditioned media (CM) for corneal nerve regeneration has not yet been applied. The CM contains paracrine factors secreted by stem cells, such as nerve growth factor (NGF), stem cell factor (SCF), hepatocyte growth factor (HGF), and vascular endothelial factor (VEGF), which have the potential for nerve regeneration (30–33). CM may also have potency for nerve regeneration.

In this study, we aimed to examine the efficacy of WJSCs or their CM in corneal nerve regeneration in diabetic keratopathy rats, which have similar corneal structure to human, by examining clinical aspects of the cornea, corneal morphology, and markers of corneal nerve regeneration.

## Materials and Methods

### Ethical approval

All experiments were approved by the Health Research Ethics Committee of the Faculty of Medicine, University of Indonesia (UI) (protocol number 17-11-1098). All animal experiments adhered to the ARVO Statement for the Use of Animals in Ophthalmic and Vision Research.

### Human WJSCs and their CM

Human WJSCs and their CM were provided from the Stem Cell and Tissue Engineering (SCTE), Indonesia Medical Education and Research Institute (IMERI), Faculty of Medicine, UI (Jakarta, Indonesia). Umbilical cords were processed non-enzymatically using the multiple harvest explants method and cultured in complete medium that contained 10% in house processed platelet lysate, 1% Glutamax-1 (Gibco, USA), 1% Penstrep (Gibco, USA), and 1% amphotericin B (Gibco, USA) in MEM alpha (Gibco, USA)<sup>[33]</sup>.

At passage 3, after the cells reached 80% confluence, the cells and CM were harvested. We collected the CM after the last medium change in only containing alpha MEM without having serum and stored at -20°C, until ready to be used. WJSCs were harvested enzymatically using TrypLE Select (Gibco, USA) and counted using trypan blue staining method. The cells were then suspended in balanced salt solution (BSS) with an approximate concentration of 3.125.000 cells per 500 µL BSS. Hence, each drop contains approximately 312.500 WJSCs. The drops were freshly prepared for each administration. The WJSCs were administered topically to rat's eyes (one eye drop per hour, for 8 hours in one day) and CM was administered topically to rat's eyes (one eye drop per hour, for 8 hours in a day, for 14 days) (34).

### Animal model of diabetic keratopathy

#### *Experimental animals*

Twenty-eight male Sprague-Dawley rats with body weight of 250–300 g were used in the study. This study complied in conformity with the ARRIVE guidelines and the National Institutes of Health Guide for the Use and Care of Laboratory Animals (NIH Publications No.80-23, revised 1996). In addition, all animal experiments adhered to the ARVO Statement for the Use of Animals in Ophthalmic and Vision Research.

#### *Study design*

Twenty-eight male Sprague-Dawley rats were randomly divided into four groups (n=7 per group): group 1 (normal control group, CN), group 2 (untreated diabetic group, DM), group 3 (diabetic group treated by WJSCs, DM+WJ), and group 4 (diabetic group treated by CM, DM+CM) (sample size was calculated according to Federer's formula). Randomization was done by simple randomization using a random number table.

#### *Establishment of diabetic rats*

Diabetes was induced by STZ intraperitoneal injection (50 mg/kg, dissolved in citrate buffer) (35). Blood glucose level and body weight were monitored. Glucose was measured in the tail vein blood; random glucose  $\geq 250$  g/dL indicated DM. Diabetic keratopathy was evaluated by rat corneal sensibility analysis (Cochet-Bonnet esthesiometer (Luneau Ophthalmologie, Chartres, France) and integrity analysis (by slit-lamp biomicroscopy). Measurements of corneal sensibility were repeated twice and averaged, and the longest filament length resulting in a positive response was recorded. Exclusion criteria for diabetic group

(groups 2, 3 and 4): when animal died during STZ treatment or random glucose level did not reach 250 mg/dL. Next, the treatments were started at week 12.

### **Euthanasia**

Rats were euthanized by using ketamine (80 mg/kg of body weight) and xylazine (50 ml/kg of body weight) into the intraperitoneal space. All rats were killed using the cervical dislocation technique at week 14.

### **WJSCs and CM administration and evaluation of primary and secondary outcomes**

At week 12, DM+WJ group received WJSCs topically via eye drops (one eye drop per hour for eight hours in one day) on the surface of the cornea. DM+CM group received topical eye drops with CM (one eye drop every hour, eight times a day, every day for two weeks). Their body weight and blood glucose levels were examined at week 12 (before treatment) and 14 (after treatment) and compared with CN and DM groups. To prove the effect of WJSCs or their CM, primary outcome measures, i.e. corneal sensibility were measured at week 12 and 14 and corneal epithelial layer integrity was measured at week 14. Other outcomes that were measured after euthanasia were corneal (epithelial and stromal) thickness, GAP-43 and TUBB3 expression (mRNA and immunohistochemistry).

### **Histological staining**

The animals were sacrificed at week 14 using ketamine (80 mg/kg) and xylazine (50 mL/kg) intraperitoneally in the thigh area. Both eyes were removed and fixed in 4% paraformaldehyde for 24 hours. After fixation, corneas were embedded in paraffin blocks and 5- $\mu$ m sections were stained by hematoxylin-eosin (HE) staining. The stained slides were observed under a light microscope with a 40x and 100x magnification of the objective lens. The thickness of the cornea and stroma, and the number of corneal epithelial layers were observed. Corneal epithelial thickness was calculated by measuring the thickness of the epithelial layer from the superficial flattened polygonal layer to the columnar-shaped basal epithelial cell layer. The corneal epithelium thickness was measured from the outermost superficial flattened polygonal epithelial cells to basal columnar epithelial cells. Stromal thickness was measured from the layer after columnar basal epithelial cells to the endothelial corneal layer.

### **mRNA expression levels of GAP-43 and TUBB3**

The total RNA was extracted from rat cornea by TriPure (Roche, Sigma-Aldrich) in accordance with the manufacturer's instructions. The RNA was reverse-transcribed to cDNA and real-time quantitative PCR was performed using SensiFAST SYBR No-ROX One-Step Kit (Bioline, Meridian Bioscience). The mRNA expression was analysed by PCR procedure including an initial denaturation step of 95°C for 2 min, 40 cycles of denaturation at 95°C for 15 s, and annealing at 60°C for 1 min. The result of qPCR was analysed following the 2- $\Delta\Delta$ CT method described by Livak and Schmittgen (36). The primer sequences used in the experiments are shown in Table 1.

### **Immunohistochemistry examination**

After deparaffinization in xylol, samples were incubated overnight (4°C) with polyclonal sheep antibody (anti-GAP-43,NBP1-41123) dissolved in phosphate buffer saline + bovine serum albumin (PBS+BSA) in 1:500, followed by 5 min washing in PBS. Furthermore, the corneal samples were incubated for 60 min with donkey anti-sheep secondary antibody (ab97125®, 1:500) combined with the Universal

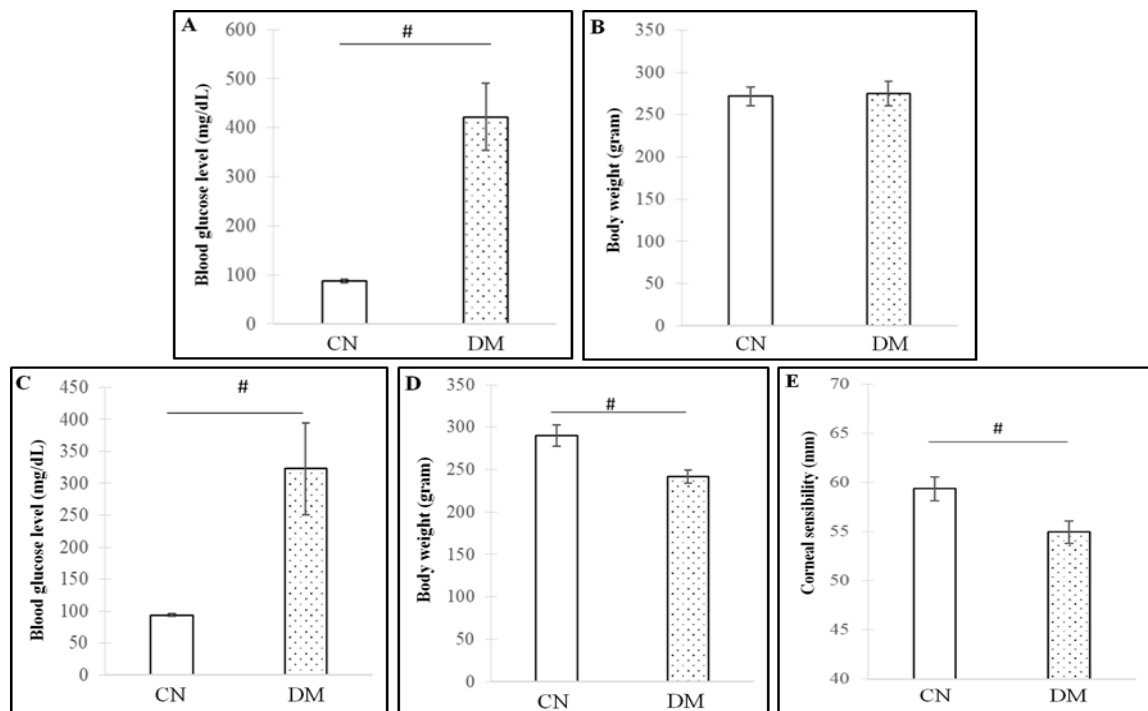
Immuno-peroxidase Polymer (N-Histofine®) kit, and rinsed with PBS at pH 7.4 for 5 min. Next, streptavidin-HRP (abcam ab64261) was applied at 37°C for 40 min, followed by 5 min rinsing in PBS. DAB was applied for 1 min at room temperature, and washed with PBS. Hematoxylin was applied as counterstain for 5 min, and slides were washed under with running water. After dripping with saturated lithium carbonate, they were washed under running water. Next, slides were dehydrated in 80%, 96%, and 100% alcohol (I and II) for 5 min each, soaked in xylol I, II, and III, and mounted with Entelan (Merck, Germany). Analysis was conducted using Image J.

### Statistical analysis

Quantitative data were summarized as mean and standard deviations (SD), and the analysis was performed using one-way analysis of variance (ANOVA) in SPSS software Version 24 (SPSS Inc, USA) followed by the least significant difference post-hoc analysis. Normal distribution and homogeneity were verified using Shapiro-Wilk and Levene tests. Non-normally distributed data was analyzed by non-parametric, Kruskal Wallis-Mann Whitney *U* test. The correlation analysis was done between the corneal function improvement and the integrity of the epithelial layer, histology, and corneal nerve regeneration (Pearson correlation for normally distributed data and Spearman correlation for non-normally distributed data). *P* values < 0.05 were considered statistically significant.

## Results

### Induced diabetic keratopathy in Sprague-Dawley rats



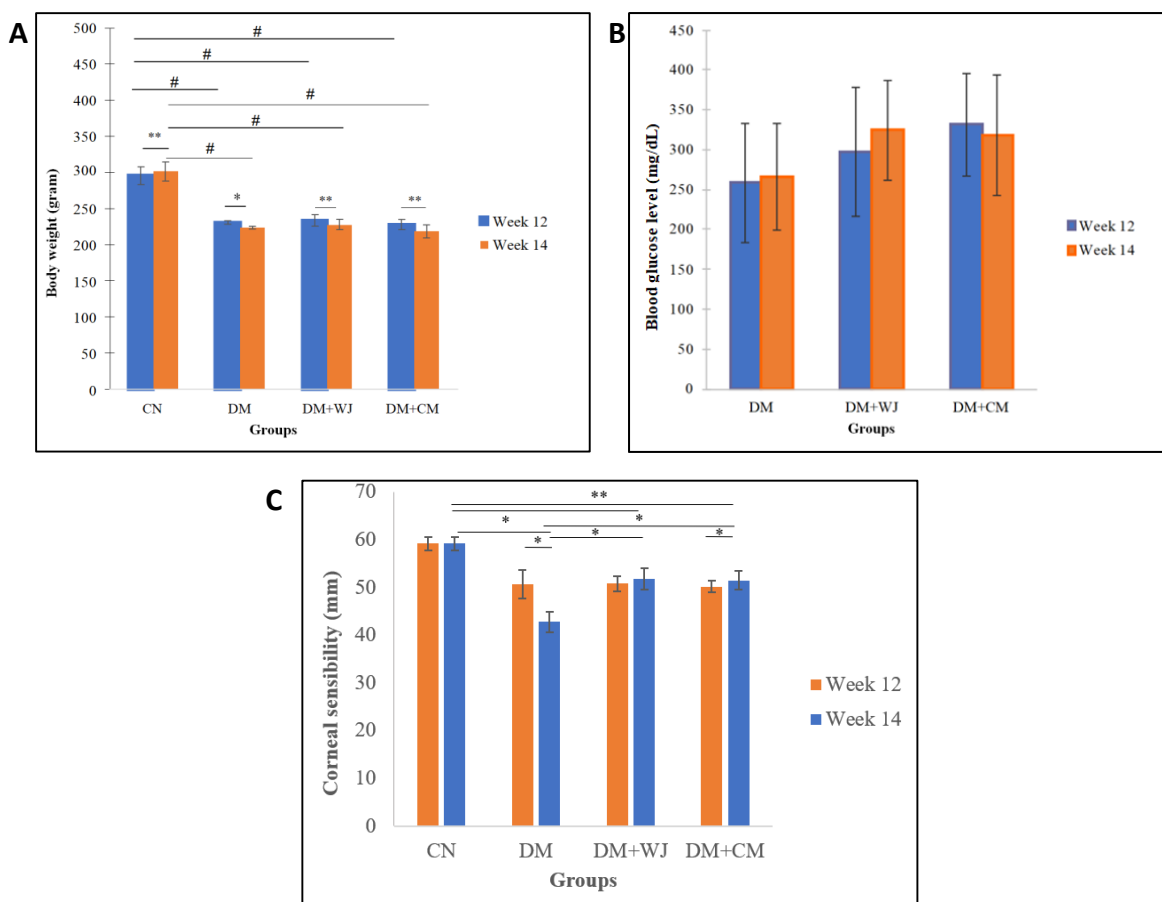
**Fig.1.** Analysis of blood glucose level and body weight of CN and DM groups on day 3 (A-B) and blood glucose level, body weight, and corneal sensibility of CN and DM groups at week 10 (C-E). Analyzed by one-way ANOVA and post-hoc Tukey's test #  $p < 0.01$ .

Blood glucose level was significantly higher in DM than in CN group ( $422\pm 69$  mg/dL vs.  $88\pm 4$  mg/dL,  $p<0.001$ ) with no difference in body weight on day 3 (Fig. 1A-B). Elevated blood glucose levels were consistent until week 10 after STZ injection ( $322.88\pm 71.74$  mg/dL vs.  $93.50\pm 2.17$  mg/dL,  $p<0.001$ ), when significant decrease in body weight ( $241.88\pm 7.41$  g vs.  $289.83\pm 12.75$  g,  $p<0.001$ ) and corneal sensibility ( $54.94\pm 1.12$  mm vs.  $59.33\pm 1.21$  mm) were observed in DM group compared with CN group (Fig. 1C-E). Thus, the treatment was conducted after keratopathy developed.

### Effect of topical application of WJSCs and CM in diabetic rat model

#### Body weight, blood glucose, sensibility and integrity of rat cornea

Body weight was significantly higher in CN than in DM, DM+WJ, and DM+CM groups both before and after treatment. After two weeks of treatment, body weight of DM, DM+WJ, and DM+CM groups decreased significantly ( $p<0.05$ ) compared with before treatment, but there were no differences between DM, DM+WJ, and DM+CM groups at week 14 ( $P=0.12$ ) (Fig. 2A). No significant change of blood glucose level was observed between DM, DM+WJ, and DM+CM groups at week 14 ( $p=0.38$ ) (Fig. 2B).

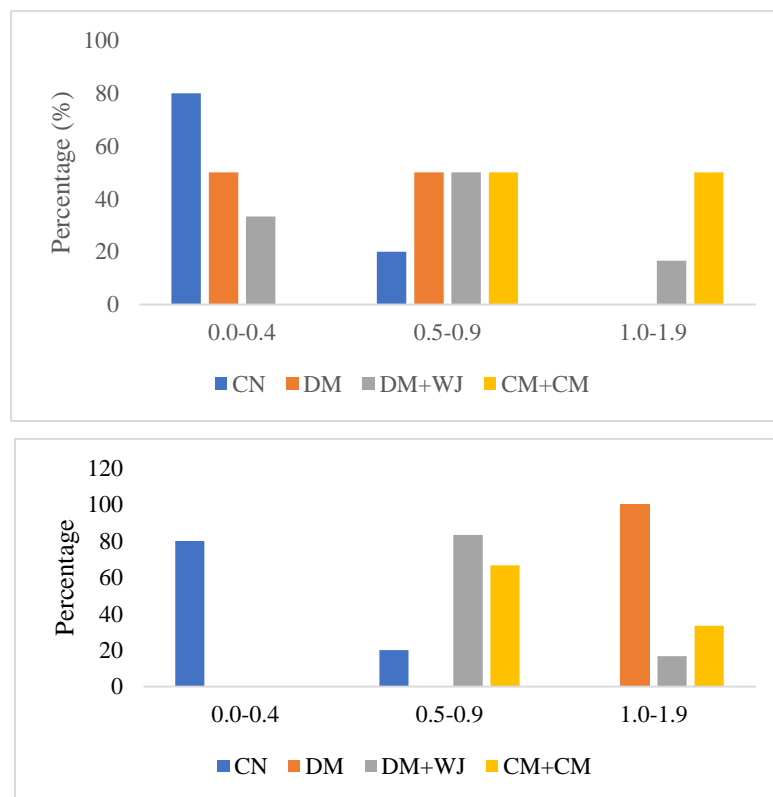
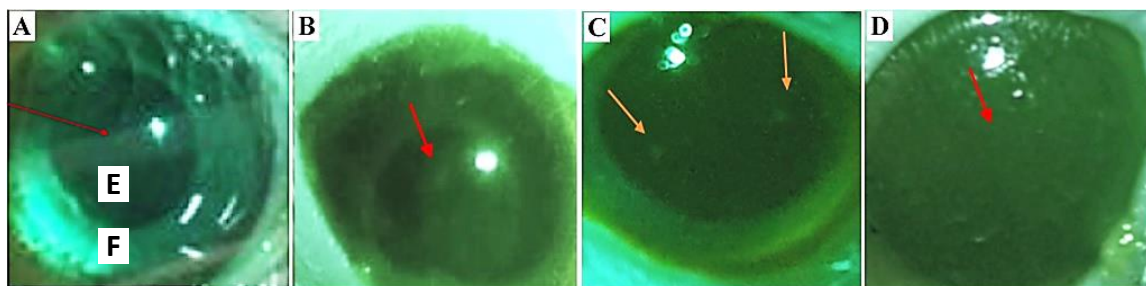


**Fig.2.** Evaluation of inter-group and within-group differences in body weight (A), blood glucose (B), and corneal sensibility (C) at week 12 and 14. Analyzed by independent t-test \*:  $p<0.05$ , \*\*:  $p<0.01$ , #:  $p<0.001$ .

In addition, after treatment, corneal sensibility decreased in DM group ( $50.75\pm 2.99$  mm vs.  $42.75\pm 2.22$  mm,  $P=0.04$ ), remained stable in CN ( $59.17\pm 1.33$  mm vs.  $59.17\pm 1.33$  mm,  $P=1.00$ ) and DM+WJ groups

(50.83±1.60 mm vs. 51.83±2.23 mm, P=0.04), but increased in DM+CM group (50.17±1.17 mm vs. 51.50±1.97 mm, P=0.03). At week 14, corneal sensibility was significantly lower in DM, DM+WJ, and DM+CM compared with CN group (p<0.001) (Fig. 2C).

Clinical value of corneal integrity is represented in Fig. 3A-D. Corneal lesion scores (CLS) at week 12 were 0–0.4 (83%, normal) and 0.5–0.9 (17%) in CN group, and 0.5–0.9 (50%) and 1–1.9 (50%) in DM group. DM+WJ group had CLS 0–0.4 (33%), 0.5–0.9 (50%), and 1–1.9 (17%), whereas DM+CM group had CLS 0.5–0.9 (50%) and 1–1.9 (50%). However, at week 14, the proportion of CN group with score 0–0.4 changed from 83% to 67% due to corneal epithelial injury of one rat. All DM had dendritic lesion with

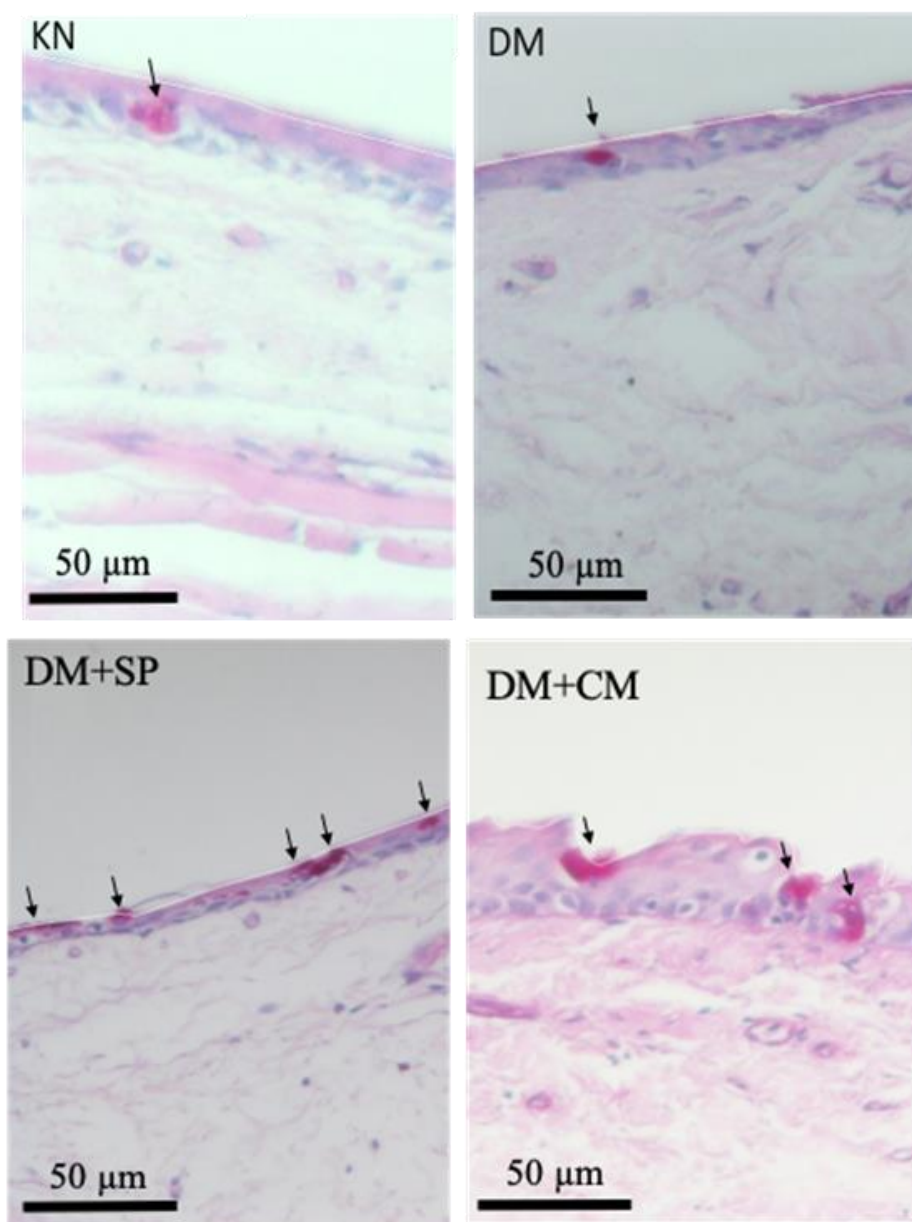


**Fig.3.** Macroscopic observation of rat eye at week 14 with fluorescence staining in CN (A), DM (B), DM+WJ (C), and DM+CM (D); percentage of corneal lesion score (CLS) at week 12 (E) and percentage of corneal lesion score (CLS) at week 14 (F). Red arrow: rat cornea; CN: control group; DM: diabetic rats; DM+WJ: diabetic rats with WJSCs applied via eye drops; DM+CM: diabetic rats with CM applied via eye drops

score 1 to 1.9, while DM+WJ group had 0.5–0.9 (83%) and 1.0–1.9 (17%). In contrast, number of dendritic lesions (1.0–1.9) to corneal lesion (0.5–0.9) decreased 50% to 33% in DM+CM group (Fig. 3E-F).

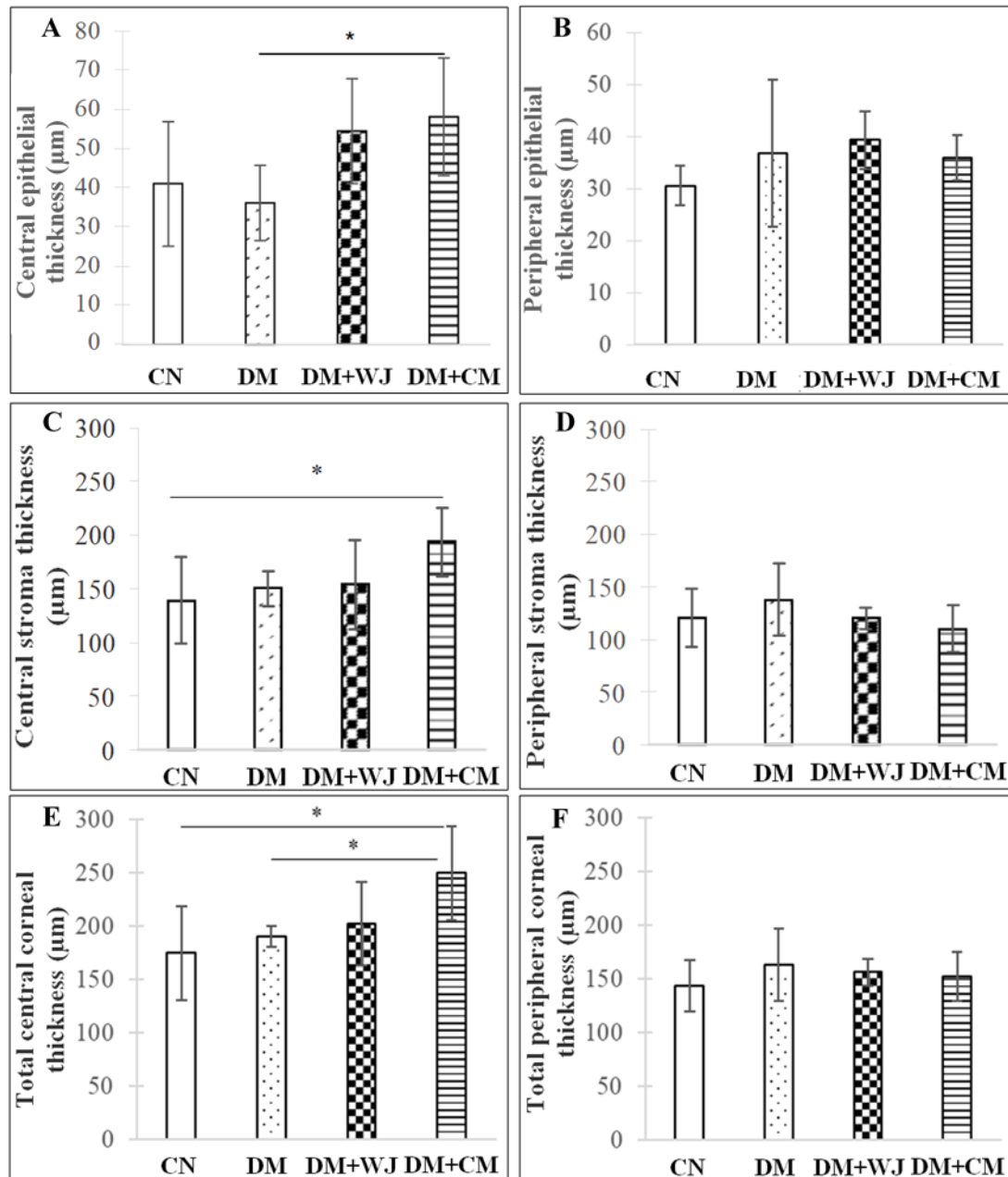
#### **Analysis of histological staining**

HE staining of the corneas are described on Figure 4. DM+CM group had significantly higher central corneal thickness compared with DM group ( $P=0.06$ ), but not compared with other groups. Peripheral corneal thickness showed no significant differences between the groups (Fig. 5A-B). Central corneal stroma was similar between DM and CN groups ( $150.40\pm 16.46\ \mu\text{m}$  vs  $139.26\pm 40.22\ \mu\text{m}$ ,  $P=0.63$ ). However,



**Fig.4.** Conjunctival goblet cells on rat cornea. Clockwise from top-left: normal control, untreated diabetic group, diabetic group treated by Wharton's jelly mesenchymal stem cell, and diabetic group treated by conditioned medium.

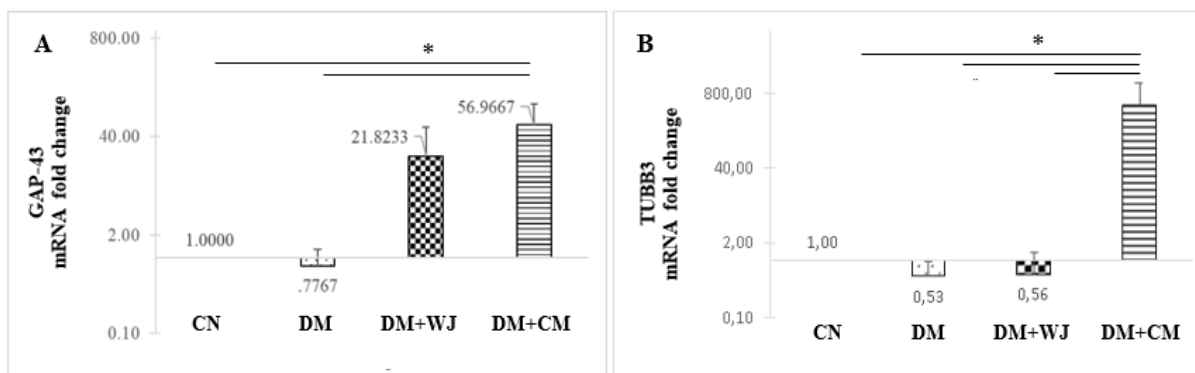
corneal stroma in DM+CM (193.81±23.27  $\mu\text{m}$ ) was significantly thicker compared with control group (P=0.02), but not significantly different from DM (P=0.08) and DM+WJ (P=0.07) groups. In addition, peripheral corneal stroma showed no significant difference between the groups (Fig. 5C-D). Total central corneal thickness was significantly higher in DM+CM group (249.81±43.85  $\mu\text{m}$ ) than in CN (174.72±44.12  $\mu\text{m}$ , P=0.004) and DM groups (190.15±9.63  $\mu\text{m}$ , P=0.03). However, no significant difference of total central corneal thickness was observed between DM+CM and DM+WJ. Total peripheral corneal thickness showed no significant differences between the groups (Fig. 5E-F).



**Fig.5.** Evaluation of corneal thickness (A-central, B-peripheral), stroma thickness (C-central, D-peripheral), and total corneal thickness (E-central, F- peripheral). Analyzed by one-way ANOVA (A,B,E,F); Mann-Whitney U (C-D) \*p<0.05.

### Expression of GAP-43 and Tubb3

The mean of GAP-43 mRNA expression was lower in DM than in CN group ( $P=0.99$ ). Furthermore, DM+WJ group and DM+CM showed slightly higher GAP-43 mRNA expression compared with DM. DM+WJ was similar ( $P=0.28$ ) and DM+CM was higher ( $P=0.01$ ) compared with control group. GAP-43 expression did not differ between the DM+WJ and DM+CM ( $P=0.12$ ) (Fig. 6).



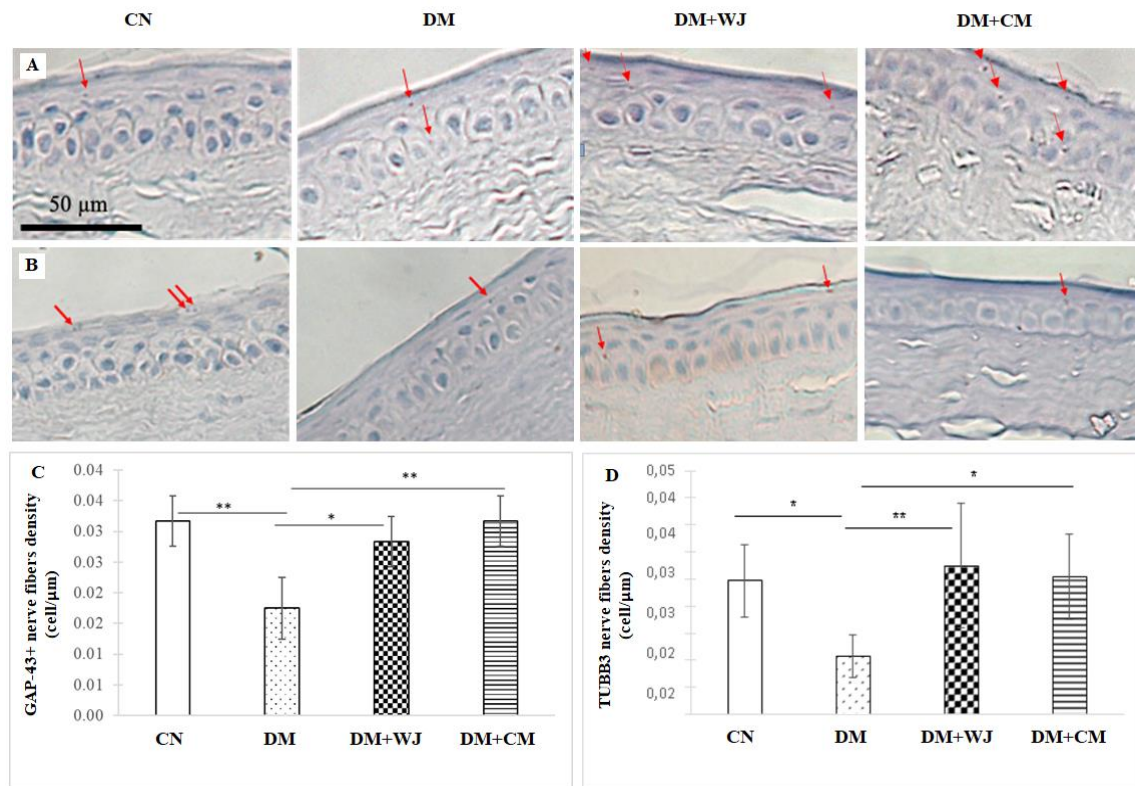
**Fig.6.** mRNA expression based on relative quantification. GAP-43 (A) and TUBB3 (B). Analyzed by one-way ANOVA (A-B) \*:  $p < 0.05$ .

The TUBB3 protein level was significantly lower in DM than in CN group ( $P=0.007$ ). Both WJSCs and CM treatments significantly increased levels of TUBB3 protein compared with DM group ( $P=0.01$ ,  $P=0.03$ , respectively). However, no significant difference was observed between DM+WJ and CN groups ( $P=0.10$ ) (Fig. 6).

### Nerve fiber density and nerve regeneration markers

The topical administration of WJSCs or their CM increased the density of GAP-43 positive nerve fibers in corneas of diabetic rats. Immunohistochemical expression of GAP-43 and TUBB3 proteins at nerve fibers along the epithelial layer is shown in Fig. 7A-B. There were nerve fibers with brown dots on the corneal epithelial layers, indicating positivity for GAP-43 marker. Next, the number of GAP-43 positive nerve fibers was counted in the epithelial layer along 270  $\mu\text{m}$  to obtain the density of GAP-43 positive nerve fibers per micrometer (Fig. 7C). DM group showed a significantly lower GAP-43-positive nerve fiber density than CN group ( $0.018 \pm 0.005$  cells/ $\mu\text{m}$  vs.  $0.032 \pm 0.004$  cells/ $\mu\text{m}$ ,  $P=0.006$ ). Administration of WJSC and CM significantly increased the density of GAP-43-positive nerve fibers compared with DM group ( $0.028 \pm 0.004$  cells/ $\mu\text{m}$ ,  $P=0.01$ ;  $0.032 \pm 0.004$  cells/ $\mu\text{m}$ ,  $P=0.006$  - respectively). The density of GAP-43-positive nerve fibers was similar between DM+WJ and DM+CM groups ( $P=0.18$ ), and between CN and DM+WJ ( $p=0.18$ ) or DM+CM groups ( $P=1.00$ ).

The number of TUBB3-expressing nerve fibers was then counted per micrometer of the corneal epithelial layer (Fig. 7D). The density of positive TUBB3 nerve fibers was significantly lower in DM than in CN group ( $0.011 \pm 0.004$  cells/ $\mu\text{m}$  vs.  $0.025 \pm 0.007$  cells/ $\mu\text{m}$ ,  $P=0.02$ ). The density of positive TUBB3 nerve fibers was also significantly higher in DM-WJ group ( $0.028 \pm 0.012$  cells/ $\mu\text{m}$ ) and DM-CM ( $0.026 \pm 0.008$  cells/ $\mu\text{m}$ ) than in DM group ( $P=0.006$ ,  $P=0.01$ , respectively), but not compared with CN group ( $P=0.56$ ,  $P=0.86$ , respectively). The average density of TUBB3-positive nerve fibers was not significantly higher in DM-WJ than in DM-CM group ( $P=0.68$ ).



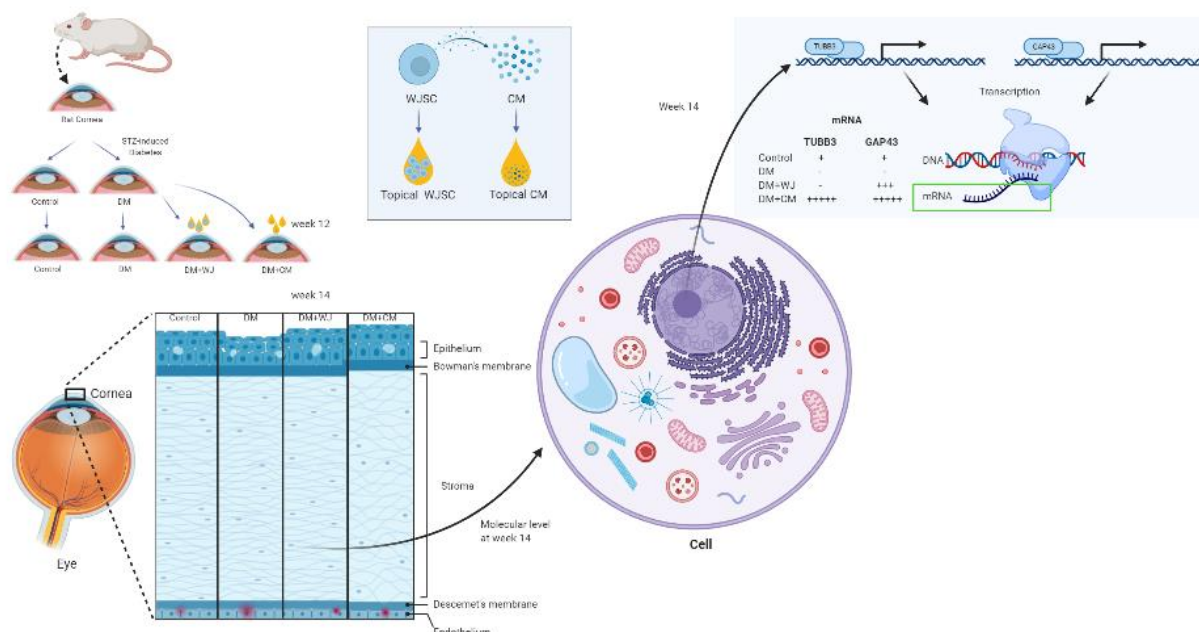
**Fig.7.** Immunohistochemical staining for GAP-43 (A, C) and TUBB3 (B, D) protein in rats corneas: microscopic evaluation (A-B) and density of positive nerve fibers (C-D). Red arrow shows positive nerve fibers. Analyzed by Mann-Whitney U (\*:  $p < 0.05$ , \*\*:  $p < 0.01$ ).

### The correlation analysis: corneal function improvement to the integrity of the epithelial layer, histology, and corneal nerve regeneration

In this study, corneal function as indicated by corneal sensibility value correlated with the degree of damage to the corneal epithelial layer integrity and histological and molecular examinations were done in pooled study groups with number of mice was six for each group. Corneal sensibility was strongly and inversely proportional to the level of damage to the integrity of the corneal epithelial layer ( $r = -0.89$  and  $p < 0.001$ ). In general, no correlation was found with the examination results on histological parameters. Lack of significant changes in DM compared with CN corneas was likely due to short duration of DM.

There was a strong positive correlation between corneal sensibility, GAP-43-positive nerve fiber density, and TUBB3 mRNA levels. There was a moderate positive correlation between corneal sensibility and TUBB3-expressing nerve fiber density ( $r = 0.41$ ,  $P = 0.13$ ).

The summary of the results is shown in Figure 8. Diabetes was successfully induced in rats by using STZ. After two weeks of treatment, the groups treated with WJSCs and CM showed epithelial tissue regeneration compared with diabetic group without treatment. The highest expression of TUBB3 and GAP43 in mRNA level was in DM+CM.



**Fig.8.** The summary of the study showing that corneal nerve regeneration in diabetic rats was improved in animals treated with WJSCs or CM. Created with BioRender.com.

## Discussion

In this study, STZ-induced rats developed DM and DM keratopathy as reflected in impaired corneal integrity and changed corneal epithelial layer and corneal sensibility. Type 1 diabetes reduced corneal sensibility was shown in DM group in our study. Decreased corneal sensibility and impaired corneal epithelial layer integrity in rats with diabetic keratopathy were also reported by Faried *et al.*(36). The corneal epithelial thickness in diabetic rats at week 12 ( $36.8 \pm 5.1 \mu\text{m}$  vs.  $37.4 \pm 6.5 \mu\text{m}$ ,  $P=0.834$ ) and week 14 ( $34.0 \pm 3.0 \mu\text{m}$  vs  $38.6 \pm 3.8 \mu\text{m}$ ,  $P=0.026$ ) after the STZ induction was lower than in normal controls<sup>[37]</sup>. Those results suggested that longer duration of DM can produce significant differences in corneal histology between DM and normal.

The changes in central stromal thickness are caused by thickening of the stroma (38–40). The corneal stroma contains collagen and glycosaminoglycans (GAG) that can attract water molecules from outside the cornea<sup>[38–40]</sup>. When the endothelial cells undergo apoptosis, their ion pumping function in pushing water from the cornea is disrupted, which results in corneal edema, and is reflected in an increased corneal thickness in rats with diabetic keratopathy (36). A previous study found that at 18 weeks after DM induction the corneas of diabetic rats were significantly thicker than those of non-diabetic rats (37). However, in our study, no significant difference was found in the corneal thickness between DM and control rats, which suggests that longer duration of DM is needed to produce noticeable effects. The effect of diabetes duration has previously been reported by Lee *et al.*(41). The diabetic corneas with a history of diabetes more than 10 years were significantly thicker than the diabetic corneas with a history of diabetes less than 10 years ( $595.9 \pm 4.2 \mu\text{m}$  vs  $582.2 \pm 3.7 \mu\text{m}$ ,  $P=0.015$ ) (42).

Mesenchymal stem cells are known to express and secrete various growth factors or cytokines, such as hepatocyte growth factor (HGF), basic fibroblast growth factor (bFGF), keratinocyte growth factor (KGF), endothelial vascular growth factor (VEGF), platelet-derived growth factor (PDGF), ciliary neurotrophic factor (CNTF), neurotrophin 3 (NT-3) factor, interleukin 1 receptor antagonist (IL1RA) as an anti-inflammatory cytokine, insulin-like growth factor 1 (IGF-1), and others (30–33,43). Stem cells secrete extracellular vesicles (EVs), which contain various proteins, peptides, nucleic acids, such as DNA and miRNA, and lipids (33,44–46). EVs help stabilize these various particles, facilitate intercellular communication, and interact with the extracellular matrix (25,46,47).

The results of this study indicate that topical treatment with WJSCs or their CM through eye drops is effective for repairing the damage to corneal integrity in DM rats. The effectiveness of topical administration of stem cells to regenerate damaged corneal epithelium was also reported in a tissue culture model<sup>[48]</sup>. It was reported that within 48 hours after wounding cornea, the regeneration of corneal epithelial cells significantly increased in the group of bone marrow stem cells ( $25 \times 10^3$  cells) compared with untreated control. Furthermore, the regeneration process is guided by the paracrine effects of various growth factors or cytokines produced by stem cells (48). Di et al. also reported that stem cells significantly reduce levels of pro-inflammatory cytokines TNF $\alpha$  and IL-1 $\beta$ , although their levels are still higher than in normal controls. This may explain why stem cells or CM were unable to restore the function of the diabetic corneal keratopathy to normal (49).

GAP-43 and TUBB3 are two marker proteins of nerve regeneration that are related to nerve growth and synapse formation (17,50). In the corneal epithelium without injury, GAP-43 plays a role in the remodeling process of the corneal nerves that are essential for normal innervation (17). In the injured corneal epithelium, GAP-43 plays a role in the recovery of nerve fibers required for wound healing or tissue regeneration (14,40). There was a strong negative correlation ( $r=-0.89$ ) between the integrity of the corneal epithelial cell layers and the expression of GAP-43 and TUBB3 in our study. Similar results were obtained by Cai et al. who found that DM mice had a lower TUBB3-positive corneal nerve fiber density compared with normal rats, followed by a thinner corneal epithelial layer and a significantly lower corneal epithelial cell density at 18 weeks after STZ induction (37). In another study, it was found that administration of CM from stem cells isolated from dental pulp *in vitro* increased expression of nerve marker genes and increased proliferation, migration, extracellular matrix, and angiogenesis to Schwann cells (51). Administration of CM from dental pulp stem cells also significantly increased the number of myelinated axons and axon-to-fiber ratio at week 12 after nerve transection surgery when compared to untreated control<sup>[51]</sup>. It has been previously described that the corneal nerves release neurotrophic factors important to support the proliferation and regeneration of corneal epithelial cells. Our immunohistochemistry analysis demonstrated that the density of the GAP-43-positive nerve fibers at growth cone and the density of the TUBB3-positive nerve fibers was higher in the normal control group in the DM group at week 14 after induction with STZ.

This study succeeded in proving that nerve disorders occur in diabetic keratopathy, such as reported in other studies (52,53) that impaired the integrity of the corneal epithelial layer, which is a characteristic of diabetic keratopathy (36). In addition, other characteristics of diabetic keratopathy, such as thinning of corneal epithelium and a sharp decrease in the number of corneal epithelial cells due to increased cell

apoptosis (54–56), were not found in this study. In contrast, this study showed that the peripheral cornea was thickened.

For further studies, the stability of stem cells or CM preparations during the transport process of WJSCs or CM until the stem cells or CM are given to experimental animals needs to be considered. In addition, animal models with a more human cornea structure-related, also the difference in the time frame between the rats which received WJ-MSCs (1 day protocol) and CM (14 days protocol) groups need to be conducted. At present, the stem cell dose or CM, frequency of administration, and topical preparation formulations are limited and need to be optimized. Therefore, further studies are required to improve results, and the results of this study can be the basis or reference for further research.

### Acknowledgements

No funding was received in this work.

### Data availability

The SNP data can be found in the NCBI repository - dbSNP: SS 289117722, rs ID: rs1555813. The genotype data that support the findings of this study are available from the corresponding author upon request.

### References

1. Atlas D. IDF diabetes atlas. International Diabetes Federation (9th editio) Retrieved from <http://www.idf.org/about-diabetes/facts-figures> 2019.
2. Sayin N, Kara N, Pekel G. Ocular complications of diabetes mellitus. *World J Diabetes* 2015;6:92.
3. He J, Pham TL, Kakazu A, et al. Recovery of Corneal Sensitivity and Increase in Nerve Density and Wound Healing in Diabetic Mice After PEDF Plus DHA Treatment. *Diabetes* 2017;66:2511-20.
4. Yin J, Huang J, Chen C, et al. Corneal complications in streptozocin-induced type I diabetic rats. *Invest Ophthalmol Vis Sci* 2011;52:6589-96.
5. Zhu L, Titone R, Robertson DM. The impact of hyperglycemia on the corneal epithelium: Molecular mechanisms and insight. *Ocul Surf* 2019;17:644-54.
6. Priyadarsini S, Whelchel A, Nicholas S, et al. Diabetic keratopathy: Insights and challenges. *Surv Ophthalmol* 2020;65:513-29.
7. Gao F, Lin T, Pan Y. Effects of diabetic keratopathy on corneal optical density, central corneal thickness, and corneal endothelial cell counts. *Exp Ther Med* 2016;12:1705-10.
8. Kaji Y, Amano S, Usui T, et al. Advanced glycation end products in Descemet's membrane and their effect on corneal endothelial cell. *Curr Eye Res* 2001;23:469-77.
9. Rosenberg ME, Tervo TM, Immonen IJ, et al. Corneal structure and sensitivity in type 1 diabetes mellitus. *Invest Ophthalmol Vis Sci* 2000;41:2915-21.
10. Kaji Y, Usui T, Oshika T, et al. Advanced glycation end products in diabetic corneas. *Invest Ophthalmol Vis Sci* 2000;41:362-8.
11. Shih KC, Lam KS, Tong L. A systematic review on the impact of diabetes mellitus on the ocular surface. *Nutr Diabetes* 2017;7:e251.
12. Puttagunta R, Tedeschi A, Soria MG, et al. PCAF-dependent epigenetic changes promote axonal regeneration in the central nervous system. *Nat Commun* 2014;5:3527.

13. Chaudhary S, Namavari A, Yco L, et al. Neurotrophins and nerve regeneration-associated genes are expressed in the cornea after lamellar flap surgery. *Cornea* 2012;31:1460-7.
14. Kawasaki A, Okada M, Tamada A, et al. Growth Cone Phosphoproteomics Reveals that GAP-43 Phosphorylated by JNK Is a Marker of Axon Growth and Regeneration. *iScience* 2018;4:190-203.
15. Stepp MA, Tadvalkar G, Hakh R, et al. Corneal epithelial cells function as surrogate Schwann cells for their sensory nerves. *Glia* 2017;65:851-63.
16. Avwenagha O, Campbell G, Bird MM. Distribution of GAP-43, beta-III tubulin and F-actin in developing and regenerating axons and their growth cones in vitro, following neurotrophin treatment. *J Neurocytol* 2003;32:1077-89.
17. Li HJ, Sun ZL, Yang XT, et al. Exploring Optic Nerve Axon Regeneration. *Curr Neuropharmacol* 2017;15:861-73.
18. Latremoliere A, Cheng L, DeLisle M, et al. Neuronal-Specific TUBB3 Is Not Required for Normal Neuronal Function but Is Essential for Timely Axon Regeneration. *Cell Rep* 2018;24:1865-79 e9.
19. Baas PW, Rao AN, Matamoros AJ, et al. Stability properties of neuronal microtubules. *Cytoskeleton (Hoboken)* 2016;73:442-60.
20. Beyazyildiz E, Pinarli FA, Beyazyildiz O, et al. Efficacy of topical mesenchymal stem cell therapy in the treatment of experimental dry eye syndrome model. *Stem Cells Int* 2014;2014:250230.
21. Zhang L, Coulson-Thomas VJ, Ferreira TG, et al. Mesenchymal stem cells for treating ocular surface diseases. *BMC Ophthalmol* 2015;15 Suppl 1:155.
22. Sgrignoli MR, Silva DA, Nascimento FF, et al. Reduction in the inflammatory markers CD4, IL-1, IL-6 and TNFalpha in dogs with keratoconjunctivitis sicca treated topically with mesenchymal stem cells. *Stem Cell Res* 2019;39:101525.
23. Lee MJ, Ko AY, Ko JH, et al. Mesenchymal stem/stromal cells protect the ocular surface by suppressing inflammation in an experimental dry eye. *Mol Ther* 2015;23:139-46.
24. Lin KJ, Loi MX, Lien GS, et al. Topical administration of orbital fat-derived stem cells promotes corneal tissue regeneration. *Stem Cell Res Ther* 2013;4:72.
25. Ferreira JR, Teixeira GQ, Santos SG, et al. Mesenchymal Stromal Cell Secretome: Influencing Therapeutic Potential by Cellular Pre-conditioning. *Front Immunol* 2018;9:2837.
26. Mennan C, Wright K, Bhattacharjee A, et al. Isolation and characterisation of mesenchymal stem cells from different regions of the human umbilical cord. *Biomed Res Int* 2013;2013:916136.
27. Fong CY, Chak LL, Biswas A, et al. Human Wharton's jelly stem cells have unique transcriptome profiles compared to human embryonic stem cells and other mesenchymal stem cells. *Stem Cell Rev Rep* 2011;7:1-16.
28. Vieira Paladino F, de Moraes Rodrigues J, da Silva A, et al. The Immunomodulatory Potential of Wharton's Jelly Mesenchymal Stem/Stromal Cells. *Stem Cells Int* 2019;2019:3548917.
29. Bojanic C, To K, Zhang B, et al. Human umbilical cord derived mesenchymal stem cells in peripheral nerve regeneration. *World J Stem Cells* 2020;12:288-302.
30. El Moshly S, Radwan IA, Rady D, et al. Dental Stem Cell-Derived Secretome/Conditioned Medium: The Future for Regenerative Therapeutic Applications. *Stem Cells Int* 2020;2020:7593402.
31. Kim HO, Choi S-M, Kim H-S. Mesenchymal stem cell-derived secretome and microvesicles as a cell-free therapeutics for neurodegenerative disorders. *Tissue Eng Regen Med* 2013;10:93-101.
32. Sagaradze G, Grigorieva O, Nimiritsky P, et al. Conditioned Medium from Human Mesenchymal Stromal Cells: Towards the Clinical Translation. *Int J Mol Sci* 2019;20.

33. Pawitan JA, Kispa T, Mediana D, et al. Simple production method of umbilical cord derived mesenchymal stem cell using xeno-free materials for translational research. *J Chem Pharm Res* 2015;7:652-6.
34. Abeeleh MA, Ismail ZB, Alzaben KR, et al. Induction of diabetes mellitus in rats using intraperitoneal streptozotocin: a comparison between 2 strains of rats. *Eur J Sci Res* 2009;32:398-402.
35. Livak KJ, Schmittgen TD. Analysis of relative gene expression data using real-time quantitative PCR and the 2<sup>-</sup>(Delta Delta C(T)) Method. *Methods* 2001;25:402-8.
36. Faried MA, Mansour FK, Zolfakar AS, et al. Experimentally induced diabetic keratopathy in albino rats and the possible protective role of ginger. *J Am Sci* 2013;9:206-20.
37. Cai D, Zhu M, Petroll WM, et al. The impact of type 1 diabetes mellitus on corneal epithelial nerve morphology and the corneal epithelium. *Am J Pathol* 2014;184:2662-70.
38. Antonyshyn K. Corneal neurotization maintains corneal epithelial integrity and restores nerve-derived peptides in a rat model of neurotrophic keratopathy: University of Toronto (Canada); 2019.
39. DG D HE. Cornea and sclera. In: Levin L, Nilsson S, Hoeve JV, et al., editors. *Alder's physiology of the eye*. 11th ed. Toronto: Elsevier; 2011. p. 71-130.
40. Meek KM, Knupp C. Corneal structure and transparency. *Prog Retin Eye Res* 2015;49:1-16.
41. Lee JS, Oum BS, Choi HY, et al. Differences in corneal thickness and corneal endothelium related to duration in diabetes. *Eye (Lond)* 2006;20:315-8.
42. Kaji Y. Prevention of diabetic keratopathy. *Br J Ophthalmol* 2005;89:254-5.
43. Zagoura DS, Roubelakis MG, Bitsika V, et al. Therapeutic potential of a distinct population of human amniotic fluid mesenchymal stem cells and their secreted molecules in mice with acute hepatic failure. *Gut* 2012;61:894-906.
44. Xie M, Xiong W, She Z, et al. Immunoregulatory Effects of Stem Cell-Derived Extracellular Vesicles on Immune Cells. *Front Immunol* 2020;11:13.
45. Tao H, Chen X, Cao H, et al. Mesenchymal Stem Cell-Derived Extracellular Vesicles for Corneal Wound Repair. *Stem Cells Int* 2019;2019:5738510.
46. Shojaati G, Khandaker I, Funderburgh ML, et al. Mesenchymal Stem Cells Reduce Corneal Fibrosis and Inflammation via Extracellular Vesicle-Mediated Delivery of miRNA. *Stem Cells Transl Med* 2019;8:1192-201.
47. McKay TB, Hutcheon AEK, Zieske JD, et al. Extracellular Vesicles Secreted by Corneal Epithelial Cells Promote Myofibroblast Differentiation. *Cells* 2020;9.
48. Sel S, Schilling UM, Nass N, et al. Bone marrow cells and CD117-positive haematopoietic stem cells promote corneal wound healing. *Acta Ophthalmol* 2012;90:e367-73.
49. Di G, Du X, Qi X, et al. Mesenchymal Stem Cells Promote Diabetic Corneal Epithelial Wound Healing Through TSG-6-Dependent Stem Cell Activation and Macrophage Switch. *Invest Ophthalmol Vis Sci* 2017;58:4344-54.
50. Hosseini S, Taghiyar L, Safari F, et al. Regenerative Medicine Applications of Mesenchymal Stem Cells. *Adv Exp Med Biol* 2018;1089:115-41.
51. Yamamoto T, Osako Y, Ito M, et al. Trophic Effects of Dental Pulp Stem Cells on Schwann Cells in Peripheral Nerve Regeneration. *Cell Transplant* 2016;25:183-93.
52. Bikbova G, Oshitari T, Baba T, et al. Diabetic corneal neuropathy: clinical perspectives. *Clin Ophthalmol* 2018;12:981-7.
53. Zhao H, He Y, Ren YR, et al. Corneal alteration and pathogenesis in diabetes mellitus. *Int J Ophthalmol* 2019;12:1939-50.

54. Zickri MB, Ahmad NA, Maadawi ZM, et al. Effect of stem cell therapy on induced diabetic keratopathy in albino rat. *Int J Stem Cells* 2012;5:57-64.
55. Take G, Karabay G, Erdogan D, et al. The ultrastructural alterations in rat corneas with experimentally-induced diabetes mellitus. *Saudi Med J* 2006;27:1650-5.
56. Di G, Qi X, Zhao X, et al. Corneal Epithelium-Derived Neurotrophic Factors Promote Nerve Regeneration. *Invest Ophthalmol Vis Sci* 2017;58:4695-702.