



Effect of *Capparis spinosa* Fruit Hydroalcoholic Extract on Paraquat-Induced Pulmonary Fibrosis in the Rat

Tahmine Ostovar¹,  Sahar Rezaei²,  Hajar Shokri-Afra³,  Sadra Samavarchi Tehrani⁴, 
Fatemeh Namvarjah⁵,  Masoume Aliabadi⁶,  Hosein Effatpanah^{7*}, 
Hemen Moradi-Sardareh⁸ 

1. International Campus, Shahid Sadoughi University of Medical Sciences, Yazd, Iran.
2. Department of Clinical Biochemistry, Faculty of Medicine, Urmia University of Medical Sciences, Urmia, Iran.
3. Gut and Liver Research Center, Non-communicable Disease Institute, Mazandaran University of Medical Sciences, Sari, Iran.
4. Endocrine Research Center, Institute of Endocrinology and Metabolism, Iran University of Medical Science, Tehran, Iran.
5. Department of Clinical Biochemistry, Faculty of Medicine, Tehran University of Medical Sciences, Tehran, Iran.
6. Department of Biochemistry, School of Medicine, Iran University of Medical Sciences, Tehran, Iran.
7. Department of Public Health, Asadabad School of Medical Sciences, Asadabad, Iran.
8. Asadabad School of Medical Science, Asadabad, Iran.

Article type: ABSTRACT

Original Article

Pulmonary fibrosis (PF) is a lethal inflammatory disease and there has been no effective medication for this progressive disease up to now. Paraquat is commonly used in agricultural settings to control weed growth and is one of the important risk factors for PF. Additionally, emerging evidence has demonstrated *Capparis spinosa* (*C. spinose*) fruit extract has anti-fibrotic, anti-inflammatory, and antioxidant properties. We aimed to evaluate whether *C. spinose* fruit hydroalcoholic extract has a positive effect against Paraquat-induced PF in rats. 30 male Wistar rats were randomly divided into 5 groups, which included: a control group, a Paraquat control group, a *C. spinose* group with a dose of 20 mg/kg, a *C. spinose* group with a dose of 30 mg/kg, a *C. spinose* group with a dose of 50 mg/kg. After 21 days of the treatment, levels of hydroxyproline and malondialdehyde (MDA) in lung tissue were assessed and lung indices and semi-quantitative histopathological changes were determined. The results showed that treatment with *C. spinose*, led to increased weight gain, whereas reduced lung weight. *C. spinose* demonstrated a decreasing effect on levels of MDA, and hydroxyproline in lung tissue. Moreover, histopathological data and the number of lung indices indicated the preventive role of *C. spinose* Paraquat-induced PF in rats.

Received:

2023.10.25

Revised:

2024.04.07

Accepted:

2024.04.08

Keywords: Pulmonary fibrosis, Paraquat, malondialdehyde, Hydroxyproline

Cite this article: Ostovar T, *et al.* Effect of *Capparis Spinosa* Fruit Hydroalcoholic Extract on Paraquat-Induced Pulmonary Fibrosis in the Rat. *International Journal of Molecular and Cellular Medicine*. 2023; 12(4):423-434. DOI: 10.22088/IJMCM.BUMS.12.4.423

*Corresponding: Hosein Effatpanah

Address: Department of Public Health, Asadabad School of Medical Sciences, Asadabad, Iran.

E-mail: m.effatpanah@gmail.com



© The Author(s).

Publisher: Babol University of Medical Sciences

This work is published as an open access article distributed under the terms of the Creative Commons Attribution 4.0 License (<http://creativecommons.org/licenses/by-nc/4>). Non-commercial uses of the work are permitted, provided the original work is properly cited.

Introduction

Pulmonary fibrosis (PF) is a deadly disease manifested by scar tissue accumulation in the lung, which results in alveolar dysfunction, deterioration of lung structure, and respiratory failure(1). Multiple risk factors have been suggested to cause PF, including microbial infections, toxic chemicals, and radiation exposure (2). There have been some therapeutic options for treating PF, such as immunosuppressive, antifibrotic medications, antimicrobial therapy, and others; however, most of them have not been efficiently curative or cost-effective (3, 4). For instance, it is proven that antimicrobial agents like doxycycline not only have no remarkable patient clinical benefits but also it is associated with some side effects such as gastrointestinal toxicity and skin rash (5, 6). Pirfenidone and nintedanib are two anti-fibrotic agents that are scarce or affordable (7). Therefore, it is urgently needed to explore an influential and low-cost approach to the treatment of PF.

Paraquat dichloride is commonly used in agricultural settings to control weed growth (8). Moreover, the increasing application of Paraquat dichloride has been reported in agricultural areas, which can cause life-threatening toxicity in humans and animals (9). Paraquat is regarded as one of the important risk factors for PF, which in high doses can be toxic to multiple organs like the liver, lungs, and kidney (10). The major organ that is targeted by Paraquat dichloride intoxication is the lung, and it is the most common reason for mortality (11).

PF induced by Paraquat poisoning led to stimulating oxidative stress via redox- cycling, and the production of radical oxygen species (ROS), which in turn affects key components of cell metabolism, resulting in cell death. Elevated ROS leads to lipid peroxidation that damages nucleic acids and proteins, produces inflammatory mediators, and activates stress-related transcription factors (12). Lipid peroxidation produces malondialdehyde (MDA) as a reactive aldehyde byproduct, which participates in further deterioration of the lung by stimulating apoptosis and inflammatory responses (13). The high levels of inflammatory cytokines contribute to acute lung injury as a result of apoptosis or necrosis of lung epithelial cells, which triggers PF (14, 15). In patients with PF, oxidative stress occurs due to the impairment or overwhelming of antioxidant defenses by the presence of ROS (16). Thus, high-dose antioxidant therapy that has been shown to prevent ROS generation and has a better therapeutic effect can be considered a candidate treatment for PF patients (17). Additionally, fibrogenic factors like TGF- β and α -smooth muscle actin (α -SMA) also enhance the progression of PF (18).

It has been investigated that some herbal products possess components with antioxidant, anti-apoptotic, and anti-inflammatory effects (19). Along with effectiveness, another reason for the popularity of traditional medicine is the lower cost which can be chosen as an affordable alternative strategy in poor countries (20). The genus *Capparis spinosa* (*C. spinosa*) is regarded as an aromatic plant that is derived from dry regions in the West or Asia. The aerial parts, roots, and seeds of *C. spinosa* contain a variety of bioactive phytochemical compounds that have been extracted and characterized. Individually or in combination, these constituents are responsible for the plant's varied pharmacological actions (21). Accumulating evidence has demonstrated the diverse beneficial pharmacological effects of *C. spinosa*, including antioxidant, antifungal, antihepatotoxic, anti-inflammatory, anti-allergic, antihistaminic, anti-diabetic, anti- cancer, antihypertensive, and antibacterial (22). According to this line of research, *C. Spinosa* reduces biochemical and

oxidative stress markers, protecting against cyclophosphamide-induced nephrotoxicity in mice (23). Furthermore, *C. Spinosa*'s beneficial components and antioxidant characteristics are what give them its therapeutic qualities. According to the literature that has been published, using *C. Spinosa* has no known negative effects, proving that this plant is safe to use. (24). Although the beneficial effects of *C. Spinosa* have been determined in various diseases, its effects on PF have not yet been investigated. Thus, we determined the therapeutic effects of this plant in the Paraquat-induced PF model.

Materials and methods

Wistar rats were purchased from the Laboratory Animal Center of the Pasteur Institute of Iran. *C. Spinosa* fruit was obtained from Shushtar City, Khuzestan province Iran, and after approval by the Khuzestan Medicinal Plants Research Center. In addition, paraquat, hydroxyproline, and malondialdehyde (MDA), and all the reagents for histological staining were obtained from Sigma–Aldrich Chemical Co. (USA).

Study design

30 male Wistar rats with a weight range of 190-200g were used. Rats were randomly divided into 5 groups of 6, which included: Group 1: As the negative control group, rats received normal saline for 21 days; Group 2: As the positive control group, rats received a single dose of paraquat (50 mg/kg, orally) only on the seventh day (the rats were taken normal saline for the first six days) and they received saline until the 21st day; Groups (3 – 5): rats treated with *C. spinosa* extract orally in doses of 20, 30 and 50 mg/kg, respectively, for 6 days, and then received a single dose of paraquat (50 mg/kg, orally) (25) only on the seventh day, and they received *C. spinosa* extract orally in doses of 20, 30 and 50 mg/kg, respectively until the 21th day (Figure 1). During the study, the animals were examined for respiratory changes, weight, and general condition. At the end, all animals were killed and their lungs were removed and weighed. Two parts of the lungs were isolated for biochemical and histological tests. The part related to histological tests was placed in a container containing 10% formalin. This research was approved by the Asadabad University of Medical Sciences Ethics Committee, Hamedan, Iran (ethics number, IR.ASAUMS.REC.1400.012). The animal procedures of this study were performed according to the ARRIVE Guidelines for Reporting Animal Research.

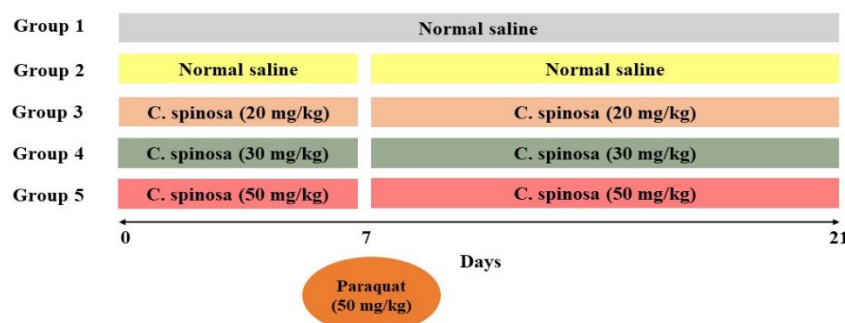


Fig. 1. Experimental protocol to study alleviative effects of *Capparis spinosa* at doses of 20, 30, and 50 mg/kg on Paraquat -induced PF in rats.

Preparing of *C. spinosa* fruit extract

C. Spinosa fruit was collected from Shushtar city, Khuzestan province Iran and after approval by Khuzestan Medicinal Plants Research Center, it was washed and dried in the shade. Then, the hydroalcoholic extract of *C. spinosa* fruit was extracted (26). According to the LD50 of the plant extract and the doses used in intraperitoneal injection in previous studies, three doses of 20, 30, and 50 mg/kg body weight were used.

Measurement of hydroxyproline and MDA

The lungs were defrizzed and 0.2 g of it was homogenized in 2 ml of distilled water and increased to 10 ml with distilled water. Then the amount of hydroxyproline as a pulmonary collagen index was measured at 557 nm by the method described by Martin CJ and Axelrod A(27). The principles of the reaction of thiobarbituric acid with MDA are based on the formation of a color complex and the adsorption against the control at a wavelength of 532 nm(28).

Histological tests

4 μ m tissue sections were prepared from the lungs of animals and then stained with hematoxylin and eosin (H&E) dye for the general examination.

RNA isolation, cDNA synthesis, and qRT-PCR

Tissue samples were homogenized using TRIzol reagent. In the next step, the total RNA was isolated using a Hybrid-R RNA Purification Kit (GeneAll, South Korea) and subsequently, the quality and quantity of the extracted RNA were assessed using a NanoDrop 1000 Spectrophotometer (Thermo Scientific, USA). Then, using 1000 ng of the RNA as substrate, cDNA was synthesized using a RevertAid First Strand cDNA Synthesis Kit (Thermo Scientific, USA). The synthesized cDNA was then used as the template for the RT-qPCR experiment which was performed using an SYBR Green RealQ Plus 2x Master Mix Green (Ampliqon). All the reactions were done as duplicates and were loaded into the Rotor-Gene Q real-time PCR cycler (QIAGEN Hilden, Germany) using the following cycle parameters: a 30-second stage at 95°C for the initial denaturation of DNA followed by 40 PCR cycles with 5 seconds at 90°C and 20 seconds at 60°C in each cycle. The obtained data were analyzed using the $2^{-\Delta Ct}$ method.

Statistical analysis

To examine the differences between different groups, One-way ANOVA followed by the Tukey post-hoc test were used. Data analysis was done using the IBM SPSS 23 software package (SPSS, Chicago, IL, USA) and the presented graphs were developed using GraphPad Prism 8 software (San Diego, CA, USA).

Results

Evaluation of body and lung weight changes in rats

Paraquat administration reduces body weight and increases lung weight. Body weight changes during the experimental period in the negative control group showed a gradual increase until the 21st day of the experiment (Figure 2), in the paraquat group from the first to the fifth-day severe body weight loss was observed and after that, there was a slight weight gain. In the other treatment groups, first body-weight loss and then weight gain were observed. Early body weight loss was lower in the 50 mg/kg dose treatment group, but in general, no significant difference was observed in terms of body weight changes in different

treatment groups. The results of the lung-to-body weight ratio showed that the therapeutic effects of the extract are dose-dependent (Figure 3).

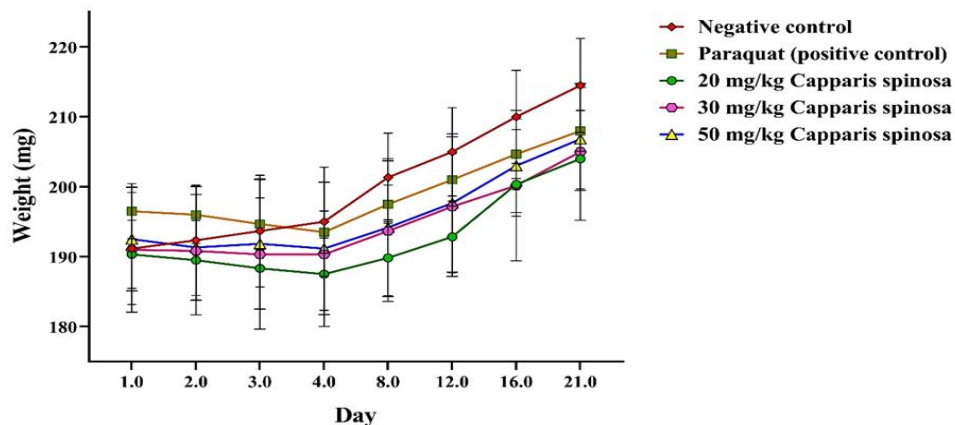


Fig. 2. Mean body weight in rats during the experimental period. All data presented as the mean \pm standard deviation (n = 6).

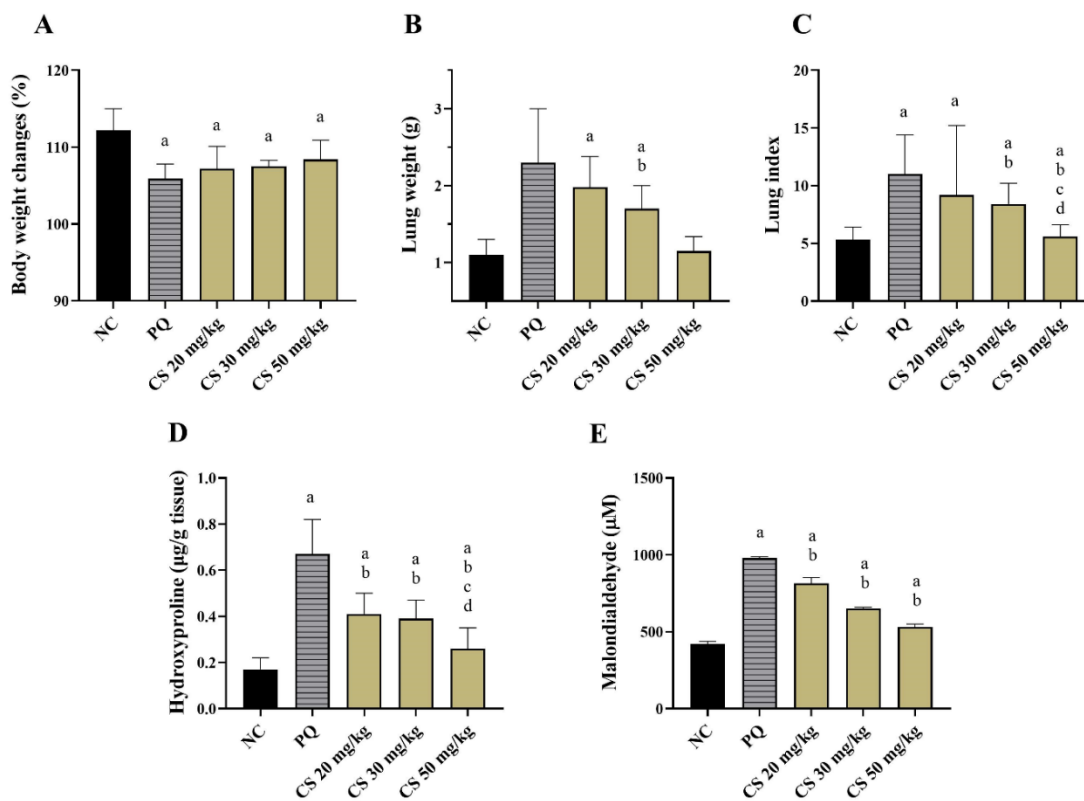


Fig. 3. Effects of Capparis spinosa at doses of 20, 30, and 50 mg/kg on the percentage of body weight changes (A), lung weight (g) (B), lung to body weight ratio (lung index) (C), levels of hydroxyproline (D) and malondialdehyde (MDA) (E) of rats in PF induced by paraquat. All data are expressed as means \pm SEM.

Comparison of hydroxyproline and MDA levels in rat lung

The results of the current study showed that paraquat increased the levels of hydroxyproline and MDA in the lungs, and *C. spinosa* fruit extract decreased them in the lungs in a dose-dependent manner (Figure 3). These results confirm the therapeutic effects of this plant.

Investigation of lung morphological changes and histological tests

In the negative control group, the appearance of the lung was completely normal and its color was uniform pink. In the paraquat group, the lungs were larger than the normal lungs, and there was edema, emphysema, and bleeding points on the surface of the lung (Figure 4), indicating the destruction of the alveoli and the creation of large open spaces. These changes were such that the general shape of the lungs and lobes was out of normal. Microscopic observations obtained from lung tissue sections showed that in the negative control group, the appearance of lung tissue, alveoli, and interstitial tissue was normal and there was no damage to them. In the Paraquat group, in most areas, the alveoli are destroyed and become open and irregular spaces. In the areas where the alveoli remained intact, their duct was filled with macrophage cells with abundant cytoplasm and the duct wall was thickened. In the *C. spinosa* group with a dose of 20 mg/kg, inflammatory and fibrotic lesions were reduced compared to the paraquat group, but the alveolar wall was still thick and inflammatory cells were seen in many areas of the tissue. In the *C. Spinosa* group with a dose of 30 mg/kg, decreased inflammatory cells and alveolar wall thickness were also seen. Also, a decrease in collagen deposition was observed in this group compared to the group treated with a dose of 20 mg/kg (Figure 4). In the *C. Spinosa* group at a dose of 50 mg/kg, alveolar destruction, alveolar wall thickness as well as collagen accumulation were significantly reduced and the structure of lung tissue is very similar to the control group (Figure 5).

Effect of hydroalcoholic extract of *C. spinosa* on the α -SMA, TGF- β 1 expression

To further verify the effect of hydroalcoholic extract of *C. spinosa* on Paraquat-induced PF and its potential mechanism, the mRNA levels of α -SMA, TGF- β 1 in lung tissue of rats were measured using RT-qPCR. Our data indicated that compared with the control group, the mRNA levels of α -SMA and TGF- β 1 significantly increased. However, compared with the Paraquat group, the expression levels of α -SMA and TGF- β 1 in the treatment groups significantly decreased. Among treatment groups, the *C. Spinosa* group at a dose of 50 mg/kg indicated further effect relative to other treatment groups (Figure 6).

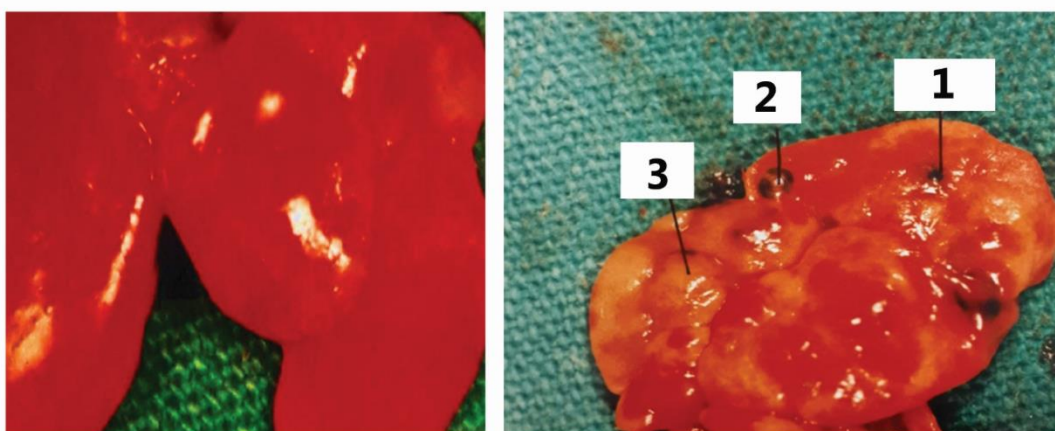


Fig. 4. A part of the normal lung (left) and fibrous lung (right). The healthy lung is pink and has uniform color but in the fibrous lung the bleeding points, emphysema, and fibrosis are marked in the photograph as numbers 1, 2, and 3, respectively.

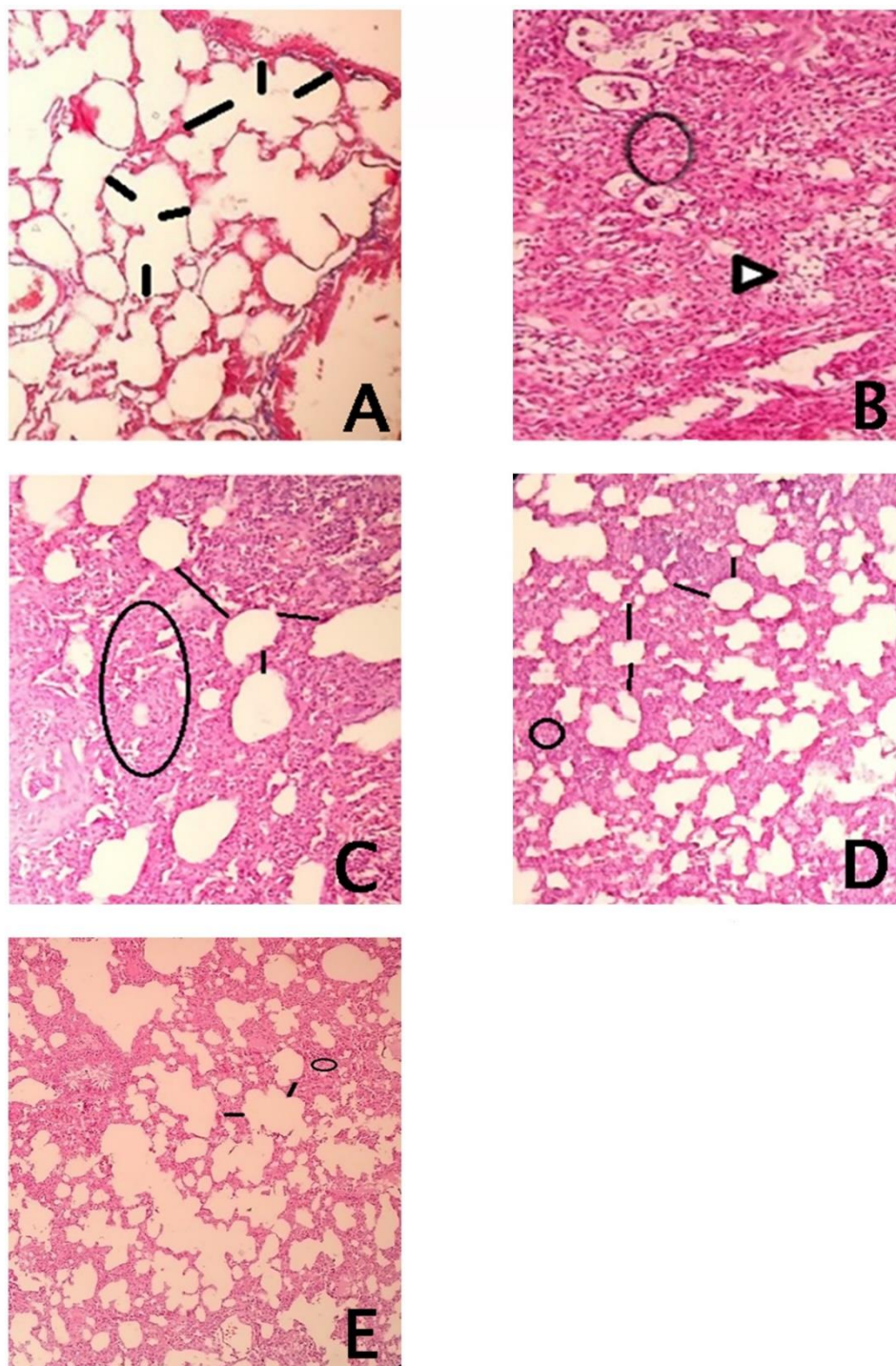


Fig. 5. A) Normal lung tissue sections with H&E staining; B) lung tissue sections of Paraquat (50 mg/kg) group. The accumulation of inflammatory cells, as indicated by arrows. C) Lung tissue sections of the group received 20 mg/kg daily of hydroalcoholic extract. The number and extension of observed lesions are less than the Paraquat group; D) lung tissue sections of the group received 30 mg/kg daily of hydroalcoholic extract E: lung tissue sections of the group received 50 mg/kg daily of hydroalcoholic extract. H&E staining at $\times 100$ magnification.

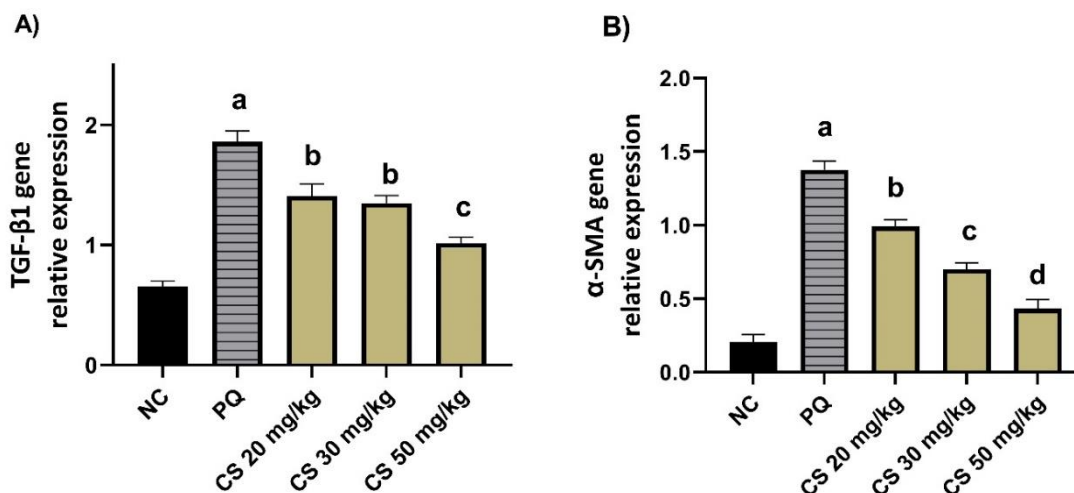


Fig. 6. Effects of *Capparis spinosa* at doses of 20, 30, and 50 mg/kg on the expression of the TGF-β and α-smooth muscle actin (α-SMA) in the lung tissue of rats. All data were analyzed by Student's t-test. The results are expressed as the mean ± SEM (n = 5) of at least three separate experiments.

Discussion

Paraquat's pulmonary effects have been thoroughly investigated from a biochemical and histological perspective(29). Our findings support past research on Paraquat's fibrogenic effects. However, little success has been reported for the treatment of PF. Regarding the herbicide's toxicity mechanism, many medications have been tested to stop Paraquat-induced PF in both humans and animals (30, 31). Accumulating evidence has demonstrated that treatment with *C. spinosa* has a therapeutic effect on the lung, reducing damage and improving histological structure. Phenolic compounds in *C. spinosa* have antioxidant activity against lung damage(32, 33). Hence, we evaluated impacts of thin plant on Paraquat-induced PF in the animal model.

Our findings elucidated that *C. Spinose* fruit extract administration in experimental rat animals could attenuate PF progression via decreased levels of MDA and hydroxyproline in a dose-dependent manner. Based on our findings, the comparison among 20 mg/kg, 30 mg/kg, and 50 mg/kg of *C. Spinose* groups has confirmed that ameliorating of MDA contents is the indicator of oxidative cell membrane damage (34) can efficiently occur in high dosage of 50 mg/kg. These findings confirm another study in which the positive influence of the hydroalcoholic extract of *C. spinose* against cyclophosphamide-induced nephrotoxicity in mice was investigated. They reported that CSE is dose-dependent, and due to the highest antioxidant and anti-inflammatory properties of *C. Spinose* MDA level has significantly reduced in mice(23). Our results demonstrated that Paraquat noticeably increased the lung wet/dry ratio, MDA, and Hydroxyproline levels (35-37). The Paraquat accumulates in the lung and contributes to the production of free radicals, which result in acute oxidative stress-related damage(38). As a result of the imbalance between oxidants and antioxidants in the lung, which has been shown as the most important reason for airway diseases, the accumulation of oxidative markers, including MDA, will be increased(39). Other studies support our results that Paraquat increases hydroxyproline levels and, consequently collagen fiber accumulation, which is the primary

pathological manifestation of PF (40, 41). It is proven that hydroxyproline has been identified as the major component of collagen fibers; thus, the lung tissue level of hydroxyproline can be employed as the direct indicator of PF (42, 43). In this regard, the effect of hydroalcoholic *C. spinosa* with a great amount of flavonoid and phenolic ingredients indicated an improved histological profile with near-normal hydroxyproline contents and normal collagen deposition. Accordingly, histological analysis of the H&E staining has strongly established antifibrotic effects of *C. spinosa* extract against cisplatin/CCL4-induced injury in liver and kidney tissues that agree with our results with Paraquat-induced lung injury (44). The primary building block of collagen is hydroxyproline, which is produced when proline is hydroxylated. The amount of collagen fibers in the lung increases significantly during lung fibrosis, and only collagen fibers contain hydroxyproline. To represent the extent of lung fibrosis, the lung hydroxyproline content might be changed to the lung collagen content (45). In the current study, Paraquat elevated the concentration of hydroxyproline in the lungs, and *C. spinosa* fruit extract reversed their effects in a dose-dependent manner, which these results was consistent with the results of other studies (46).

We have also investigated morphological changes in the lung tissue and histological analysis and microscopic examination have shown that the lung structure was destroyed after Paraquat administration in rats, and the fibrotic pattern was observed. Mirzaee *et al.* also approved alveolar destruction, alveolar wall thickness, accumulation of inflammatory cells, and lung fibrosis in paraquat-induced PF in mice (35). On the contrary, there were no pathological changes in the negative control group, and the architecture of the lung was completely normal. Furthermore, we have noticed that in all three groups of rats with Paraquat-induced PF that were treated with *C. spinosa*, attenuating effects of this medicinal plant improved by adding dosages from 20 mg/kg, 30 mg/kg, and 50 mg/kg, respectively. Our data surprisingly confirmed that at a dose of 50 mg/kg of *C. spinosa*, alveolar destruction, alveolar wall thickness, as well as collagen accumulation, severely decreased. Therefore, at the end of the experiments, it can be seen that the structure of lung tissue is very similar to the control group.

TGF- β 1 plays a crucial role in the fibrosis of injured organs. Abnormal expression of TGF- β 1 is hypothesized to be important in the pathogenesis of PF. TGF- β 1 is a vital regulator of Epithelial-mesenchymal transition (EMT) (47). EMT, is regarded notable part in the pathological process of PF. Over activation of TGF- β 1 can induce EMT in alveolar epithelial cells, which promotes the occurrence and development of PF. Moreover, it has been revealed that TGF- β 1 is a key fibro genic cytokine, which plays a critical role in the expression of α -SMA and induction of PF (48). In the current study it was illustrated that TGF- β 1 and α -SMA levels enhanced remarkably following Paraquat, simultaneous to the progression of PF. Therefore, it was conclude that TGF- β 1 may contribute to lung injury, and which was consistent with previous documents (49, 50). In agreement with our results (21, 51), interestingly, our findings demonstrated that different doses of *C. spinosa* extract have positive effect on improvement of PF, which dose of 50 mg/kg indicated better effect on PF.

PF induced by Paraquat, which involved alveolar thickness correlated with fibroblast and myofibroblast proliferation along with an increase in lung weight, MDA and hydroxyproline contents were reported. We have demonstrated a possible intervention effect of *C. spinosa* in paraquat-induced PF. It may be related to the inhibition of the mRNA expression of TGF-1 and α -SMA by *C. spinosa*. Treatment with hydroalcoholic

extract of *C. spinosa* has shown beneficial effects in rat PF intoxicated by Paraquat in a concentration-dependent manner. Overall, it seems that oral consumption of *C. spinosa* can be useful for the improvement of lung tissues against Paraquat-induced oxidative stress. Further studies are required to be carried out to elucidate the anti-oxidant and anti-fibrotic effects of *C. spinosa* on lung fibrosis.

Acknowledgments

This project was financially supported by a grant from the Deputy of Research, Asadabad University of Medical Sciences. This project was financially supported by a grant from the Deputy of Research, Asadabad University of Medical Sciences (Grant number: 68)

References

1. Lakatos HF, Thatcher TH, Kottmann RM, et al. The Role of PPARs in Lung Fibrosis. *PPAR Res* 2007;2007:71323.
2. Hasan M, Paul NC, Paul SK, et al. Natural Product-Based Potential Therapeutic Interventions of Pulmonary Fibrosis. *Molecules* 2022;27.
3. Parimon T, Hohmann MS, Yao C. Cellular Senescence: Pathogenic Mechanisms in Lung Fibrosis. *Int J Mol Sci* 2021;22.
4. Ghabousian A, Safari S, Ansari N. Potential therapeutic approaches in paraquat poisoning: a narrative review. *Front emerg med* 2022;6:e7-e.
5. Lorenzen JM, Schonenberger E, Hafer C, et al. Failed rescue therapy with rapamycin after paraquat intoxication. *Clin Toxicol (Phila)* 2010;48:84-6.
6. Bayhan GI, Akbayram S, Ozaydin Yavuz G, et al. Cutaneous side effects of doxycycline: a pediatric case series. *Cutan Ocul Toxicol* 2017;36:140-4.
7. Chen CY, Chen CH, Wang CY, et al. The effect of additional antimicrobial therapy on the outcomes of patients with idiopathic pulmonary fibrosis: a systematic review and meta-analysis. *Respir Res* 2021;22:243.
8. Kovalchuk N, Jilek JL, Van Winkle LS, et al. Role of Lung P450 Oxidoreductase in Paraquat-Induced Collagen Deposition in the Lung. *Antioxidants (Basel)* 2022;11.
9. Li T, Yang X, Xin S, et al. Paraquat poisoning induced pulmonary epithelial mesenchymal transition through Notch1 pathway. *Sci Rep* 2017;7:924.
10. Dong MN, Xiao Y, Li YF, et al. Amelioration of paraquat-induced pulmonary fibrosis in mice by regulating miR-140-5p expression with the fibrogenic inhibitor Xuebijing. *Int J Immunopathol Pharmacol* 2020;34:2058738420923911.
11. Sittipunt C. Paraquat poisoning. *Respir Care* 2005;50:383-5.
12. Niazi R, Peeri M, Azarbayjani MA. The interactive effect of berberine chloride and exercise rehabilitation on the lung tissue apoptosis and oxidative stress biomarkers in rats exposed to diazinon. *Physiol Pharmacol* 2022;26:60-9.
13. Subbiah R, Tiwari RR. The herbicide paraquat-induced molecular mechanisms in the development of acute lung injury and lung fibrosis. *Crit Rev Toxicol* 2021;51:36-64.
14. Khalighi Z, Rahmani A, Cheraghi J, et al. Perfluorocarbon attenuates inflammatory cytokines, oxidative stress and histopathologic changes in paraquat-induced acute lung injury in rats. *Environ Toxicol Pharmacol* 2016;42:9-15.
15. Cappelletti G, Maggioni MG, Maci R. Apoptosis in human lung epithelial cells: triggering by paraquat and modulation by antioxidants. *Cell Biol Int* 1998;22:671-8.
16. Taniguchi A, Tsuge M, Miyahara N, et al. Reactive Oxygen Species and Antioxidative Defense in Chronic Obstructive Pulmonary Disease. *Antioxidants (Basel)* 2021;10.

17. Hu S, Qiao C, Yuan Z, et al. Therapy with high-dose long-term antioxidant free radicals for severe paraquat poisoning: A pilot study. *Exp Ther Med* 2018;16:5149-55.
18. Bai L, Li A, Gong C, et al. Protective effect of rutin against bleomycin induced lung fibrosis: Involvement of TGF-beta1/alpha-SMA/Col I and III pathway. *Biofactors* 2020;46:637-44.
19. Asiimwe JB, Nagendrappa PB, Atukunda EC, et al. Prevalence of the Use of Herbal Medicines among Patients with Cancer: A Systematic Review and Meta-Analysis. *Evid Based Complement Alternat Med* 2021;2021:9963038.
20. Xiong Y, Gao M, van Duijn B, et al. International policies and challenges on the legalization of traditional medicine/herbal medicines in the fight against COVID-19. *Pharmacol Res* 2021;166:105472.
21. Zhang H, Ma ZF. Phytochemical and Pharmacological Properties of *Capparis spinosa* as a Medicinal Plant. *Nutrients* 2018;10.
22. Nabavi SF, Maggi F, Daglia M, et al. Pharmacological Effects of *Capparis spinosa* L. *Phytother Res* 2016;30:1733-44.
23. Kalantar M, Goudarzi M, Khodayar MJ, et al. Protective effects of the hydroalcoholic extract of *Capparis spinosa* L. against cyclophosphamide-induced nephrotoxicity in mice. *Jundishapur J Nat Pharm Prod* 2016;11.
24. Sher H, Alyemini MN. Ethnobotanical and pharmaceutical evaluation of *Capparis spinosa* L, validity of local folk and Unani system of medicine. *J Med Plants Res* 2010;4:1751-6.
25. Kalantar M, Khodayar MJ, Kalantari H, et al. Therapeutic effect of gallic acid against paraquat-induced lung injury in rat. *Jundishapur J Nat Pharm Prod* 2018;13.
26. Mirzakhani N, Farshid AA, Tamaddonfard E, et al. Comparison of the effects of hydroalcoholic extract of *Capparis spinosa* fruit, quercetin and vitamin E on monosodium glutamate-induced toxicity in rats. *Vet Res Forum* 2020;11:127-34.
27. Martin CJ, Axelrod AE. A modified method for determination of hydroxyproline. *Proc Soc Exp Biol Med* 1953;83:461-2.
28. Mehrzadi S, Mombeini MA, Fatemi I, et al. The effect of ellagic acid on renal injury associated with acrylamide in experimental rats. *Physiol Pharmacol* 2022;26:313-21.
29. Sun Z, Yang Z, Wang M, et al. Paraquat induces pulmonary fibrosis through Wnt/beta-catenin signaling pathway and myofibroblast differentiation. *Toxicol Lett* 2020;333:170-83.
30. Tai W, Deng S, Wu W, et al. Rapamycin attenuates the paraquat-induced pulmonary fibrosis through activating Nrf2 pathway. *J Cell Physiol* 2020;235:1759-68.
31. Rodrigues da Silva M, Schapochnik A, Peres Leal M, et al. Beneficial effects of ascorbic acid to treat lung fibrosis induced by paraquat. *PLoS One* 2018;13:e0205535.
32. Benzidane N, Charef N, Krache I, et al. In vitro bronchorelaxant effects of *Capparis spinosa* aqueous extracts on rat trachea. *J Appl Pharm Sci* 2013;3:085-8.
33. Mansour RB, Jilani IBH, Bouaziz M, et al. Phenolic contents and antioxidant activity of ethanolic extract of *Capparis spinosa*. *Cytotechnology* 2016;68:135-42.
34. Pehlivan M, Hazinedaroglu SM, Kayaoglu HA, et al. The effect of diosmin hesperidin on intestinal ischaemia--reperfusion injury. *Acta Chir Belg* 2004;104:715-8.
35. Mirzaee S, Mansouri E, Shirani M, et al. Diosmin ameliorative effects on oxidative stress and fibrosis in paraquat-induced lung injury in mice. *Environ Sci Pollut Res Int* 2019;26:36468-77.
36. Yasaka T, Ohya I, Matsumoto J, et al. Acceleration of lipid peroxidation in human paraquat poisoning. *Arch Intern Med* 1981;141:1169-71.
37. Rasooli R, Pourgholamhosein F, Kamali Y, et al. Combination Therapy with Pirfenidone plus Prednisolone Ameliorates Paraquat-Induced Pulmonary Fibrosis. *Inflammation* 2018;41:134-42.

38. Liu MW, Liu R, Wu HY, et al. Radix puerariae extracts ameliorate paraquat-induced pulmonary fibrosis by attenuating follistatin-like 1 and nuclear factor erythroid 2p45-related factor-2 signalling pathways through downregulation of miRNA-21 expression. *BMC Complement Altern Med* 2016;16:11.
39. Fois AG, Paliogiannis P, Sotgia S, et al. Evaluation of oxidative stress biomarkers in idiopathic pulmonary fibrosis and therapeutic applications: a systematic review. *Respir Res* 2018;19:51.
40. Liu K, Zhan Z, Gao W, et al. Cyclosporine attenuates Paraquat-induced mitophagy and pulmonary fibrosis. *Immunopharmacol Immunotoxicol* 2020;42:138-46.
41. Yiwen C, Chenzhong Z, Chunrui S, et al. Establishment of the trans-resveratrol-induced mouse pulmonary fibrosis model and its comparison with the bleomycin-induced model. *bioRxiv* 2019:812883.
42. Wu Y, Cui S, Wang W, et al. Kidney and lung injury in rats following acute diquat exposure. *Exp Ther Med* 2022;23:275.
43. Wu Z, Hou Y, Dai Z, et al. Metabolism, Nutrition, and Redox Signaling of Hydroxyproline. *Antioxid Redox Signal* 2019;30:674-82.
44. Tir M, Feriani A, Labidi A, et al. Protective effects of phytochemicals of *Capparis spinosa* seeds with cisplatin and CCl₄ toxicity in mice. *Food biosci* 2019;28:42-8.
45. Ren Y, Zhao J, Shi Y, et al. Simple determination of L-hydroxyproline in idiopathic pulmonary fibrosis lung tissues of rats using non-extractive high-performance liquid chromatography coupled with fluorescence detection after pre-column derivatization with novel synthetic 9-acetylimidazol-carbazole. *J Pharm Biomed Anal* 2017;142:1-6.
46. Shariati S, Khodayar MJ, Hemmati AA, et al. The ameliorative effects of allopurinol on paraquat-induced pulmonary fibrosis in rats. *Pharm Sci* 2019;25:11-6.
47. Chen CM, Chou HC, Hsu HH, et al. Transforming growth factor-beta1 upregulation is independent of angiotensin in paraquat-induced lung fibrosis. *Toxicology* 2005;216:181-7.
48. Shao X, Li M, Luo C, et al. Effects of rapamycin against paraquat-induced pulmonary fibrosis in mice. *J Zhejiang Univ Sci B* 2015;16:52-61.
49. Guo F, Sun YB, Su L, et al. Losartan attenuates paraquat-induced pulmonary fibrosis in rats. *Hum Exp Toxicol* 2015;34:497-505.
50. Kan B, Jian X, Zhou Q, et al. Effect of transforming growth factor-beta1 on acute lung injury caused by paraquat. *Mol Med Rep* 2014;9:1232-6.
51. Askari VR, Rahimi VB, Zamani P, et al. Evaluation of the effects of Iranian propolis on the severity of post operational-induced peritoneal adhesion in rats. *Biomed Pharmacother* 2018;99:346-53.