

Comparative Study of Expression of Smad3 in Oral Lichen Planus and Normal Oral Mucosa

Shima Nafarzadeh¹, Samad Ejtehadi², Pouyan Amini Shakib^{1*}, Majid Fereidooni³,
Ali Bijani⁴

1. Department of Oral and Maxillofacial Pathology, Faculty of Dentistry, Babol University of Medical Sciences, Babol, Iran.
2. Private Dentist, Babol, Iran.
3. Department of Periodontology, Faculty of Dentistry, Babol University of Medical Sciences, Babol, Iran.
4. Non-Communicable Pediatric Diseases Research Center, Amirkola Hospital, Babol University of Medical Sciences, Babol, Iran.

Submitted 23 Sep 2013; Accepted 12 Nov 2013

Oral lichen planus (OLP) is a chronic inflammatory disease of the oral mucosa which is considered by the World Health Organization (WHO) as a premalignant condition. One step in malignant development is so called epithelial mesenchymal transition (EMT), a process whereby epithelial cells acquire mesenchymal characteristics. A factor known to induce EMT is the transforming growth factor- β (TGF- β), which uses the Smad proteins as mediators for its signaling. The aim of this study was to compare the expression of Smad 3 in Oral Lichen Planus and normal oral mucosa. This descriptive analytic study was performed on 30 patients with OLP (21 women and 9 men with mean age of 45.23 ± 2.44 years) and 20 normal oral mucosa (14 women and 6 men with mean age of 46.95 ± 2.21 years). The samples were studied by immunohistochemical staining. Data were analyzed with paired T-test and Wilcoxon test by SPSS software. Expression of Smad3 in OLP samples and normal oral mucosa was different. This difference was statistically significant ($P < 0.001$). The apparently higher expression of Smad 3 in oral lichen planus compared to normal oral mucosa might help to discuss its higher potential for malignant transition.

Key words: Oral lichen planus, smad 3, transforming growth factor β

Lichen planus (LP) is a relatively common chronic dermatologic disease that often affects the oral mucosa with a prevalence ranging from 0.2 to 4% (1-2). Indeed Oral lichen planus (OLP) is

considered as a chronic disease with dynamic evolution (2) for which several panels of diagnostic criteria, such as the modified WHO one, have been proposed to render a more reliable and accurate

* Corresponding author: Department of Oral and Maxillofacial Pathology, Faculty of Dentistry, Babol University of Medical Sciences, Babol, Iran. E-mail: p.shakib@mubabol.ac.ir; pouyanshakib@yahoo.com

diagnosis (3). The cause of LP is unknown; it is generally considered to be an immunologically mediated process (4). Hence, there is a questionable theory about the potential of OLP for malignant transformation into oral squamous cell carcinoma (OSCC) (5). Although Gonzalez-Moles et al. (6) have reported the frequency of 0 to 12.5% for this kind of transformation, in a recent study, Shen et al. (7) demonstrated that the incidence of OSCC developing in lesions previously diagnosed as OLP, is less than 1% and they didn't entirely rule out these cases as de novo OSCCs.

Transforming growth factor β (TGF β) regulates several cellular processes including proliferation, differentiation, migration and death (8). Numerous studies have demonstrated the importance of TGF β signaling in cancer progression and metastasis. Although some studies support the tumor suppressive effects of TGF β , other studies indicate a tumor promoting function for TGF β . Thus, it seems that this cytokine may have various effects on different stages of tumorigenesis (9).

Smad proteins are an integral part of the TGF β signaling pathway. After ligand binding, the TGF β receptor II (T β RII) phosphorylates TGF β receptor I (T β RI) which consequently phosphorylates and activates two subgroups of Smad proteins (Smad 2 and Smad 3). These Smad proteins bind to a co-Smad and finally the Smad complex translocates to the nucleus, where the transcription of TGF β -responsive genes are regulated (9).

Some previous studies have demonstrated a significant reduction of Smad 3 in TGF β signaling pathway in tissues with erythematous OLP compared to normal oral mucosa (10) and some have shown an increased expression of this protein and consequently, related it to early stages of OLP transition to malignancy (11). Therefore, in this study we investigated the immunohistochemical (IHC) expression of Smad3 in tissues with OLP and adjacent normal tissues to determine the relative

role of this protein in evolution of OLP and evaluate the prognostic value of this marker when the progression to malignancy is suspected.

Materials and Methods

Tissue specimens and clinical data

Our study consisted of 30 biopsy specimens taken from patients with OLP (24 reticular and 6 erosive), as defined by modified WHO criteria (3) and 20 samples of non-inflammatory, non-precancerous adjacent normal oral epithelium as control group. All cases were retrieved from the files of Oral and Maxillofacial Pathology Department of Dental Faculty of Babol University of Medical Sciences, between 2005 and 2010. All biopsies have been fixed in formalin 10% and processed to paraffin-embedded tissue blocks according to the routine practice. Representative Hematoxylin & Eosin sections were assessed to confirm the diagnosis and sufficing of the tissue for further evaluation. The clinical and demographic data were collected from pre-existing medical records.

Immunohistochemistry

Smad3 expression was assessed by immunohistochemical analysis using streptavidin-biotin-peroxidase technique. Formalin-fixed paraffin embedded tissue samples were cut into 4 μ m-thick sections and mounted on silane-coated slides. The sections were deparaffinized with xylene, rehydrated in graded ethanol and immersed in 0.3% H₂O₂ in methanol for 10 min at room temperature (RT) to block the endogenous peroxidase activity. To retrieve the antigen, the slides were treated using microwav in 0.01 mol/L citrate buffer (PH= 6.2) at 95°C for 15 min and then washed in distilled water. The sections were then incubated with primary antibody (ab55479, Abcam Corp., Cambridge, UK) for 60 min. For negative control, no primary antibody was added. After washing in PBS, the sections were incubated with Horseradish peroxidase (HRP) conjugated secondary antibody at

Expression of Smad3 in OLP

RT for 30 min. Following PBS washing, sections were incubated with 3, 3' diaminobenzidine tetrahydrochloride (DAB) (Dako, Corp, Denmark) for 10 min. Finally, the sections were counterstained with hematoxylin and then dehydrated, cleared and covered with a coverslip. Also, colorectal carcinoma specimens were used as positive controls (based on related data sheet) to allow antibody expression comparison.

Evaluation of Immunohistochemical staining

The cytoplasmic and / or nuclear immunohistochemical expression of Smad 3 was evaluated quantitatively using a light microscopy according to what Danielsson et al. performed in their study (11). According to the staining intensity (weak to severe), the percentage of stained epithelial cells in the area involved by OLP and adjacent normal tissue was determined and the tissues were classified into four groups: (0) 0%; (1) 1 to 25%; (2) 26 to 50%; (3) 51 to 75%; (4) higher than 75 %; at a magnification of 100×.

Finally, paired T-test and Wilcoxon test were used to assess the statistical significance of the correlations between Smad3 expression and the health status of the tissue and $P < 0.05$ was considered significant.

Results

The mean age of the patients with OLP and control group were 45.23 years (range 23 to 75) and 46.95 years (range 28 to 75), respectively. Twenty one (70%) of the patients with OLP and fourteen (70%) of the control group were women. The

remaining thirty percent of both groups were men.

22 (73.4%) samples of lichen planus were located in buccal mucosa, 1 (3.3%) in labial mucosa, 4 (13.3%) in tongue, 2 (6.7) in gingiva and 1 (3.3) in palate. In normal oral mucosa, the distribution of samples in the above locations was 16 (80%), 1 (5%), 2 (10%), 1 (5%) and 0 (0%) respectively. The results of immunohistochemical staining of Smad3 in both case and control groups are represented in table 1 and figures 1 and 2. Also, a significant difference of the expression of Smad3 was observed between normal oral mucosa and OLP (Table 2).

Discussion

We designed the present study in order to evaluate Epithelial-Mesenchymal Transition (EMT) changes in oral lichen planus because of malignant behavior of this disease and its tendency to change to head and neck squamous cell carcinoma (HNSCC) which was found in previous studies.

Among the proteins which have role in EMT, we chose Smad3 because it is involved in TGF- β pathway and is highly expressed in several cancers (12). The SMAD genes encode components of the TGF- β signaling normally inhibits the cell cycle; the loss of these genes may allow unrestrained cell growth (4). Smad3 together with co-factor SNAIL also acts in repression of E-cadherin and Occludin which help tumoral progression (13). Smad3 may have a role in apoptosis and also in inflammation, but the results are contradictory (14-15).

Table 1. IHC staining findings of Smad3 in OLP and control group.

| Group | Case (n)/ (%) | Control (n)/ (%) |
|-------|---------------|------------------|
| 0 | 0/0 | 3/15 |
| 1 | 3/10 | 17/85 |
| 2 | 14/46.7 | 0/0 |
| 3 | 4/13.3 | 0/0 |
| 4 | 9/30 | 0/0 |

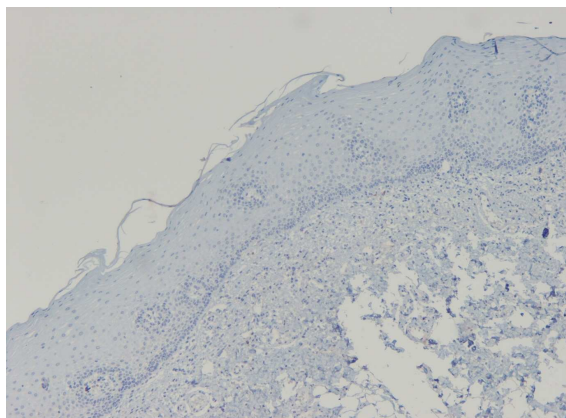


Fig 1. IHC staining of normal oral mucosa showing no expression of SMAD3 (X100).

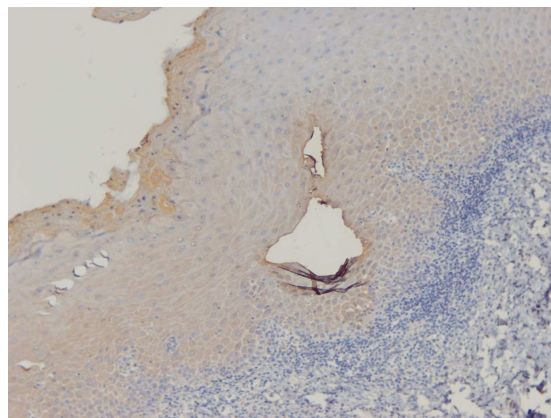


Fig 2. IHC staining of OLP demonstrates high expression (score 4) of SMAD3 (X400).

Table 2. Comparison of immunohistochemical expression of Smad3 in OLP and normal oral mucosa.

| Sample type | Mean value | Std. deviation | T- test | Wilcoxon |
|---------------------------|------------|----------------|---------|----------|
| <i>OLP</i> | 64.5 | 30.17 | P<0.001 | P=0.001 |
| <i>Normal oral mucosa</i> | 11.25 | 6.85 | | |

In this study, we found a higher expression rate in OLP compared to normal oral mucosa which was statistically significant ($P<0.001$). Different target genes are regulated by Smad 2 and Smad 3 (16). So, the higher expression of Smad 3 in OLP could prove that Smad 3 target genes are more expressed in OLP. This finding supports the malignant potential of OLP.

Karatsaidis et al. found a decreased expression of Smad 2/3 in their study. This difference could be due to the use of different antibodies, different IHC methods and inclusion of both OLP and oral lichenoid reactions in their research (10).

Danielsson et al. found an increased expression of Smad 3 in OLP, dysplasia and tumors compared to normal controls which is in accordance with our findings (11).

In the present study, expression was seen in the nucleus of epithelial cells which is explained by Smad3 active status due to phosphorylation. Considering normal oral mucosa, we found few cells with Smad 3 expression which is in accordance with Danielson et al.'s study results (11), but

is in contrast to the study of Karatsaidis who found a strong expression of Smad 3 in normal oral mucosa (10).

As a whole, our findings showed an increased expression of Smad 3 in OLP compared to normal oral mucosa which might be due to its probable role in apoptosis, inflammation and EMT and may indicate its higher potential for malignant transition.

Acknowledgement

We would like to thank Mr. Mohsen Aghajanjpour for his kind cooperation in sample staining. This work has been supported by a grant (#9031813) from Babol University of Medical Sciences.

Conflict of interest

Authors declared no conflict of interest.

References

1. Neville BW, Damm DD, Allen CM, et al. Oral and Maxillofacial Pathology. 3 ed. Missouri: Saunders; 2009:782-6.
2. Lu SL, Reh D, Li AG, et al. Overexpression of transforming growth factor beta1 in head and neck epithelia results in

Expression of Smad3 in OLP

inflammation, angiogenesis, and epithelial hyperproliferation.

Cancer Res 2004;64:4405-10.

3. van der Meij EH, Schepman KP, van der Waal. The possible premalignant character of oral lichen planus and oral lichenoid lesions: a prospective study. Oral Surg Oral Med Oral Pathol Oral Radiol Endod 2003;96:164-71.

4. Regezi JA, Sciubba JJ, Jordan RC. Oral pathology; clinical pathologic correlations. 5 ed. Missouri: Saunders; 2008:90-1.

5. Gorsky M, Epstein JB. Oral lichen planus: malignant transformation and human papilloma virus: a review of potential clinical implications. Oral Surg Oral Med Oral Pathol Oral Radiol Endod 2011;111:461-4.

6. Gonzalez-Moles MA, Scully C, Gil-Montoya JA. Oral lichen planus: controversies surrounding malignant transformation. Oral Dis 2008;14:229-43.

7. Shen ZY, Liu W, Feng JQ, et al. Squamous cell carcinoma development in previously diagnosed oral lichen planus: de novo or transformation? Oral Surg Oral Med Oral Pathol Oral Radiol Endod 2011;112:592-6.

8. Luwor RB, Baradaran B, Taylor LE, et al. Targeting Stat3 and Smad7 to restore TGF-beta cytotstatic regulation of tumor cells *in vitro* and *in vivo*. Oncogene 2013;32:2433-41.

9. Tannehill-Gregg SH, Kusewitt DF, Rosol TJ, et al. The roles of Smad2 and Smad3 in the development of chemically induced

skin tumors in mice. Vet Pathol 2004;41:278-82.

10. Karatsaidis A, Schreurs O, Axell T, et al. Inhibition of the transforming growth factor-beta/Smad signaling pathway in the epithelium of oral lichen. J Invest Dermatol 2003;121:1283-90.

11. Danielsson K, Wahlin YB, Coates PJ, et al. Increased expression of Smad proteins, and in particular Smad3, in oral lichen planus compared to normal oral mucosa. J Oral Pathol Med 2010;39:639-44.

12. Kumar V, Abbas AK, Fausto A, et al. Robbins basic pathology. 8th ed. Philadelphia: Saunders; 2007:197.

13. Vincent T, Neve EP, Johnson JR, et al. A SNAIL1-SMAD3/4 transcriptional repressor complex promotes TGF-beta mediated epithelial-mesenchymal transition. Nat Cell Biol 2009;11:943-50.

14. Kim SG, Kim HA, Jong HS, et al. The endogenous ratio of Smad2 and Smad3 influences the cytotstatic function of Smad3. Mol Biol Cell 2005;16:4672-83.

15. Li AG, Lu SL, Zhang MX, et al. Smad3 knockout mice exhibit a resistance to skin chemical carcinogenesis. Cancer Res 2004;64:7836-45.

16. Schmierer B, Hill CS. Kinetic analysis of Smad nucleocytoplasmic shuttling reveals a mechanism for transforming growth factor beta-dependent nuclear accumulation of Smads. Mol Cell Biol 2005;25:9845-58.